

AN UNUSUAL CASE OF HYPOPHOSPHATEMIA IN A CHILD AFFECTED BY DI GEORGE SYNDROME

Kalapurackal MA, Barzaghi F, Pitea M, Cassano G, Weber G.

Department of Pediatrics, Vita-Salute San Raffaele University, San Raffaele Scientific Institute, Milan, Italy

Introduction

Among other features, Di George Syndrome is usually characterized by hypoparathyroidism and consequent hypocalcemia and hyperphosphatemia. We report a clinical case of a patient with Di George Syndrome and an unusual case of hypophosphatemia.

Clinical case

A female child born from non consanguineous parents of Pakistani origin presented with congenital heart anomaly at prenatal ultrasound and confirmed at birth, with type B aortic arch interruption, right-sided aortic arch, wide ventricular and atrium septum defects, which required repeated surgical corrections during the first 9 months of life. The ultrasound also reported absence of the thymus. Suspecting Di George Syndrome, a fluorescent in situ hybridization (FISH) was performed, which reported a microdeletion of chromosome 22 therefore confirming the diagnosis.

Routine screening for features associated with Di George syndrome were performed at 18 months of age. The patient's weight, length and head circumference were inferior to the 3rd percentile. She presented with widened wrists and ankles and slight bowing of the legs. She managed to walk independently at 16 months of age. Her diet was reported to be slightly deficient in milk products, and otherwise varied. She had previously suffered a post-traumatic fracture of the left arm. The patient never experienced a severe infection requiring hospitalization.

Blood tests showed normal T-cell count, the and hearing test was normal. Routine calcium and phosphate metabolism documented hypophosphatemia in multiple occasions, associated with normal total and ionized calcium, normal PTH, increased alkaline phosphatase (ALP), slightly low 25OHVitamin D, however not low enough to cause hypophosphatemia. Urinary phosphate reabsorption was reduced. Wrist and knee radiographs showed signs of rickets.

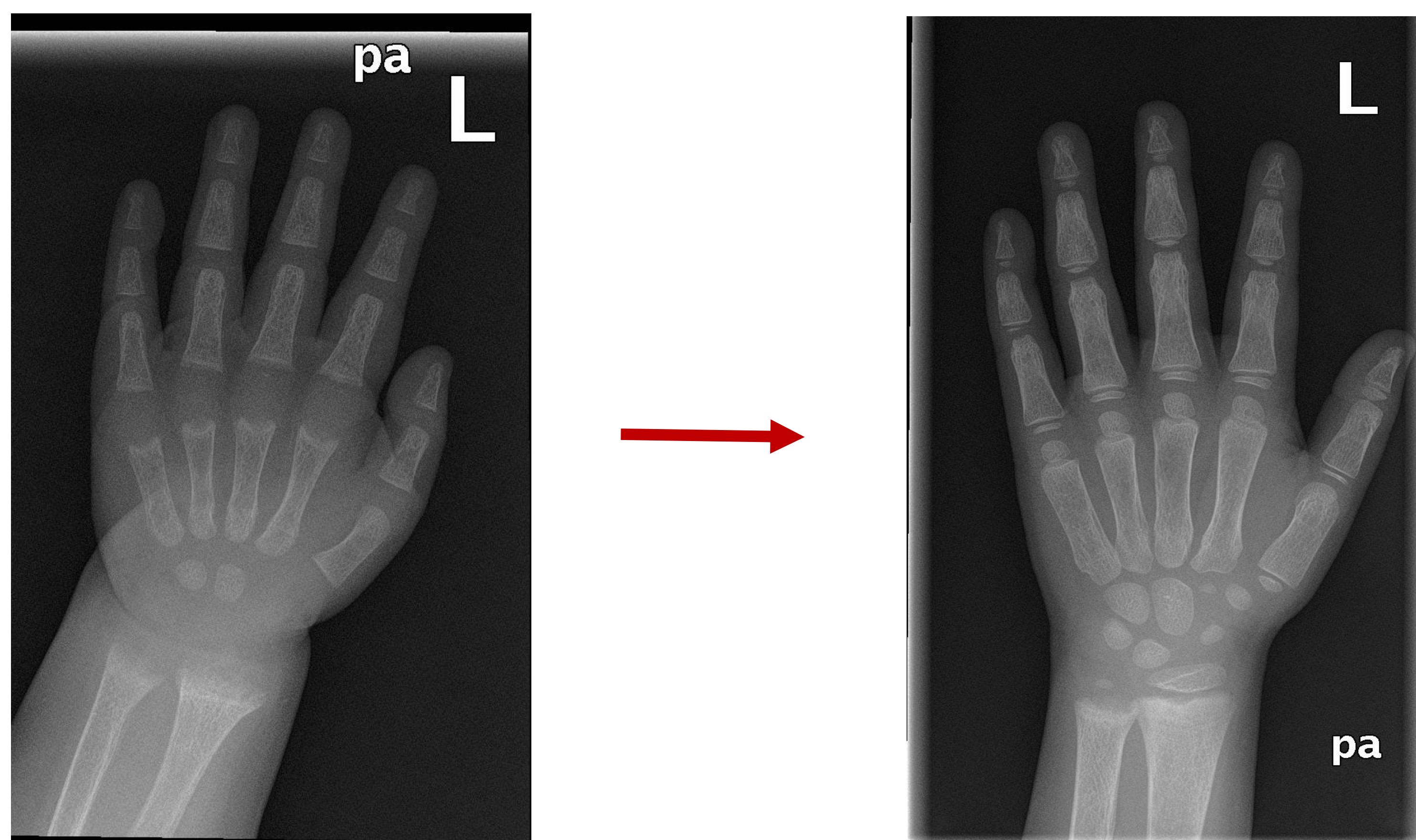
Parameter	Value	Normal range
Tot. Calcium	9,08 mg/dl	9-11
Phosphorus	2,53 mg/dl	3,75-6,30
Creatinine	0,09 mg/dl	0,2-0,5
PTH	75,4 pg/ml	20-90
ALP	1168 U/L	<409 U/L
25OHVit D	18,8 ng/ml	20-68
1,25OHVit D	71 pg/ml	26-95
Urine ca/creat	0,04 mg/mg	0,03-0,56
Urine phosphorus	120.3 mg/dl	
TPO4/GFR	2,45	>2,5

Calcium and phosphate metabolism at XLH diagnosis

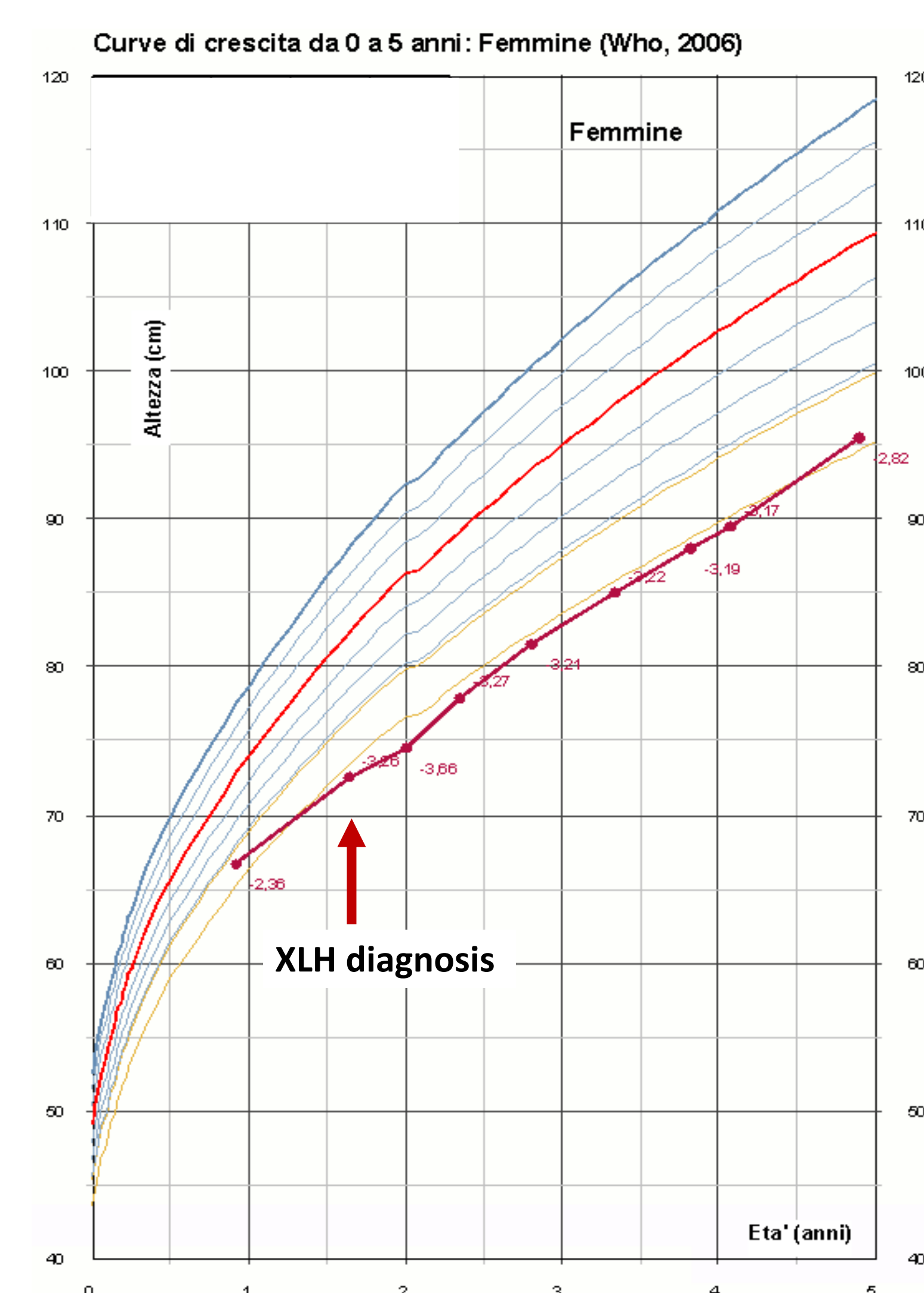
Results

A genetic analysis on PHEX gene was performed, which documented a heterozygous deletion on exon 12, responsible for X-linked hypophosphatemia (XLH). The genetic analysis was extended to the parents, who resulted non affected.

Treatment with alfacalcidol and phosphate was initiated, and the patient showed progressive normalization of bone metabolites and improvement of the radiographic signs of rickets. Severe impairment of linear growth persisted, likely due to the coexistence of the two pathologies and the resulting therapeutic challenges.



Hand and wrist X-ray at XLH diagnosis and 3 years after therapy with phosphate and alfacalcidol.



Conclusion

Di George Syndrome is usually characterized by hypoparathyroidism and consequent hyperphosphatemia and hypocalcaemia, therefore the patient's biochemical and radiological findings were very unusual.

These findings must compel the clinician to search an alternative cause to hypophosphatemia and rickets in the patient.

No cases of hypophosphatemia in Di George Syndrome and coexistence of XLH and Di George Syndrome have previously been reported in literature.

Bibliography

1. McDonald-McGinn DM, Sullivan KE, Marino B et al. 22q11.2 deletion syndrome. Nat Rev Dis Primers. 2015;1:12071
2. Carpenter TO, Imel EA, Holm IA et al. A clinician's guide to X-linked hypophosphatemia. J Bone Miner Res 2011;26(7):1281-8.