

# A RARE FORM OF OVOTESTICULAR DSD: DIAGNOSTIC AND MANAGEMENT CHALLENGES



Kruthika Narayan<sup>1</sup>, Nicky Nicoll<sup>1</sup>, Julie Alderson<sup>2</sup>, Sarah Smithson<sup>3</sup>, Guy Nicholls<sup>4</sup>, Elizabeth Crowne<sup>1</sup>

1. Department of Paediatric Endocrinology and Diabetes, Bristol Royal Hospital for Children, University Hospitals Bristol NHS Foundation Trust, United Kingdom
2. Psychology, Bristol Royal Hospital for Children, University Hospitals Bristol NHS Foundation Trust, United Kingdom
3. Department of Clinical Genetics, St Michael's Hospital, University Hospitals Bristol NHS Foundation Trust, United Kingdom
4. Department of Paediatric Surgery, Bristol Royal Hospital for Children, University Hospitals Bristol NHS Foundation Trust, United Kingdom

The authors have no financial relationships or conflicts of interest to disclose



## INTRODUCTION

A baby born to non-consanguineous parents after a normal pregnancy, presented with atypical genitalia (Prader Stage 2-3) including clitoromegaly, a urethral opening in the anterior perineum and a normal vaginal opening. Adrenal androgens were within normal range for age. The baby was noted to have inguinal herniae, with bilateral masses present in the labio-scrotal folds. Pelvic ultrasound identified a normal uterus however the labial masses could not be identified as ovaries or testes.

The blood karyotype was XX and array CGH was normal.

Hormonal investigations are listed in table 1. The raised AMH and Inhibin B were inconsistent with an XX karyotype and suggested an ovotesticular DSD. No evidence of adrenal abnormality was present. Sex of rearing was discussed with the family, with consensus that baby would be reared as female.

Test	Result
Testosterone	0.6nmol/L
LH	0.6 IU/L
FSH	0.6IU/L
17OHP	1.7nmol/L [ $< 2$ nmol/L]
11 deoxycortisol	9.7nmol/L [0-7.2nmol/L]
Standard Synacthen	246nmol/L $\rightarrow$ 599nmol/L $\rightarrow$ 770nmol/L
5-alpha dihydrotestosterone	2167pmol/L [80-1270]
DHEAS	8.8umol/L [0.86-16.5]
Plasma renin activity	12.3 [0.5-3.5]
Aldosterone	2120 [90-700]
AMH	280.2pmol/L
Inhibin B	149ng/L

Table 1: Summary of hormonal investigations on Baby. Raised AMH and Inhibin B suggestive of an ovotesticular DSD

## NR5A1 GENE

Genetic testing was undertaken and a 30-gene DSD panel identified a heterozygous sequence variant c.389C>T in NR5A1 which had not been reported previously.

The NR5A1 encodes steroidogenic factor SF1 which is known to be involved in gonadal development. Recurrent heterozygous NR5A1 variants have been associated with both 46, XX and 46, XY DSD, specifically c.275G>A, p.(Arg92Gln) and c.274C>T, p.(Arg92Trp)<sup>1-3</sup>. It is hypothesised the substitution of arginine to tryptophan or glycine at this locus impairs the binding of NR5A1 to DNA and thereby alters function of this transcription factor to switch ovarian/testicular development<sup>3</sup>.

In this child, the c.389C>T variant was at a different location within the gene and it was identified in the baby's asymptomatic father. This evidence, together with the cytogenetic findings within the gonad, suggest that it is not clinically significant.

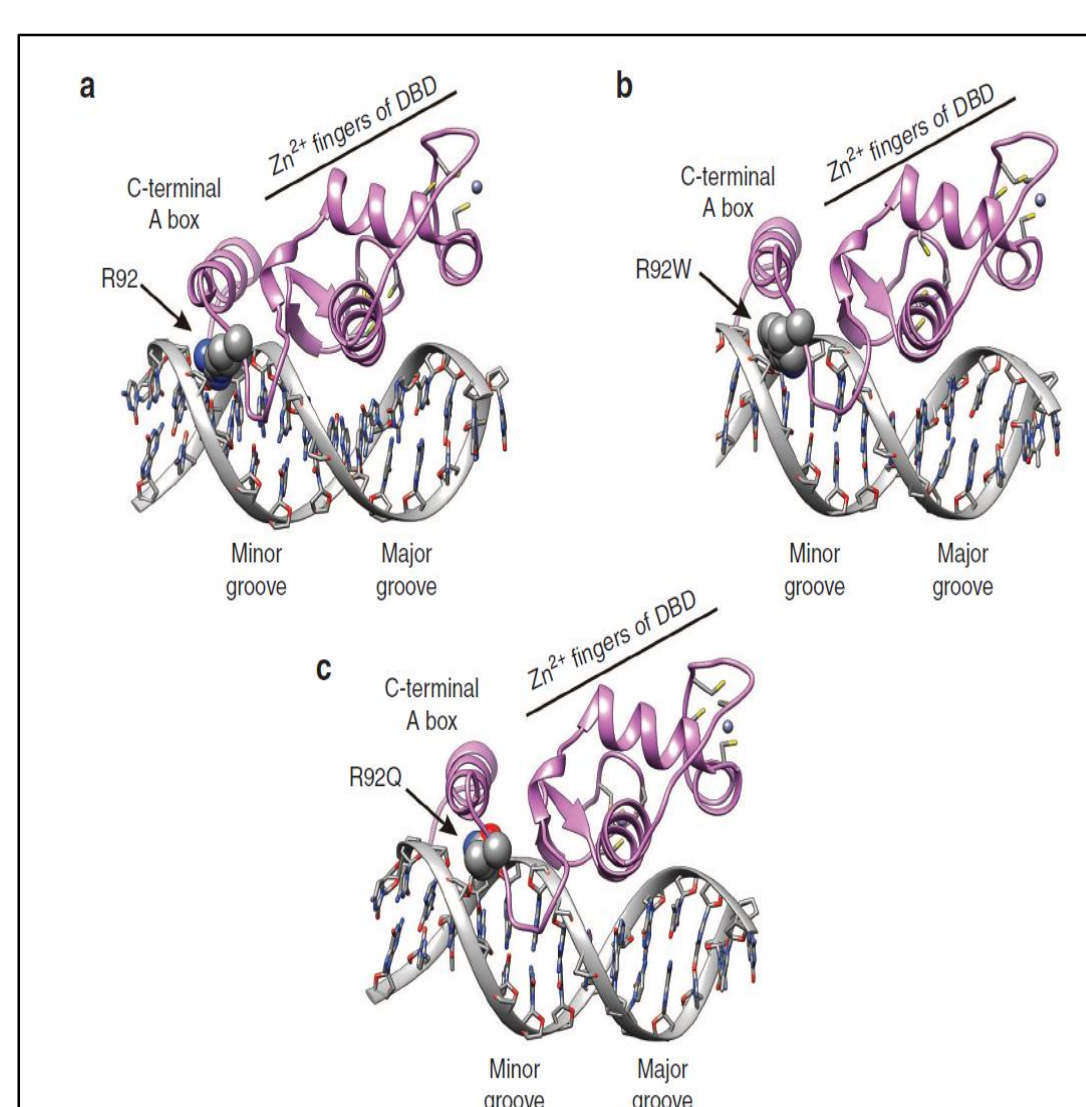


Figure 1: Postulated mechanisms of impaired DNA binding with NR5A1 variants (b and c) compared to wild type (a). From Baetens et al., 2017<sup>1</sup>.

## 46XX/69XXY MIXOPLOIDY

Multidisciplinary consensus was that the herniae needed surgery and in view of the ovotesticular DSD, the gonads should be biopsied to characterise the histology if they appeared abnormal. At surgery, the right gonad was clearly abnormal with a bipolar appearance & was biopsied, the left looked macroscopically like an ovary (not biopsied).

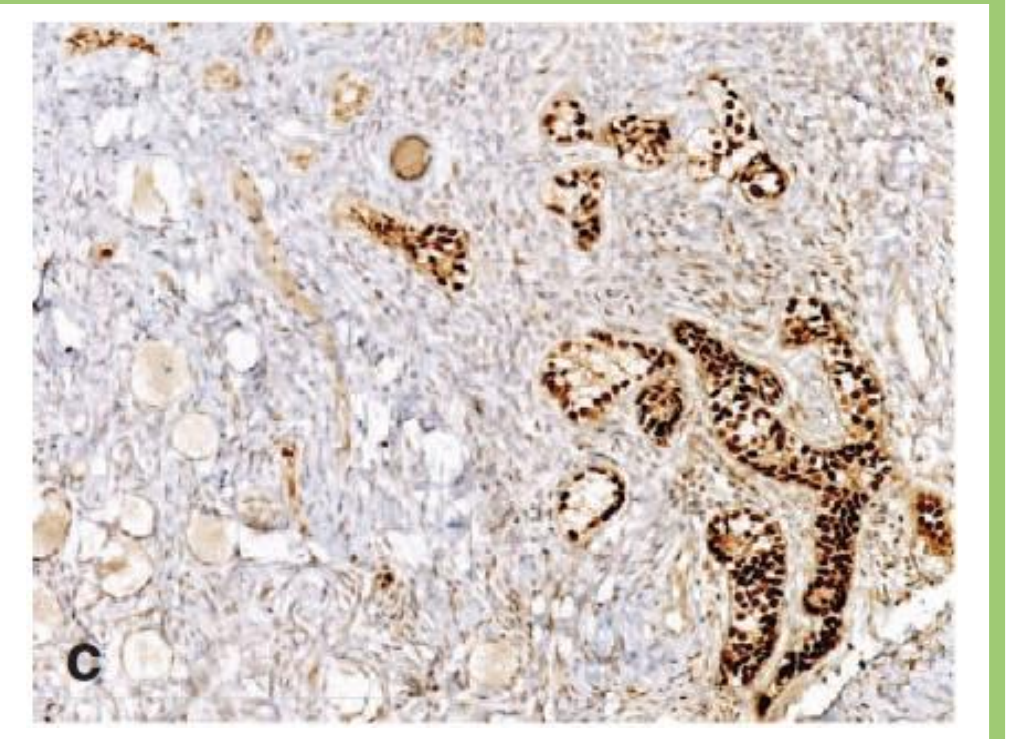


Figure 2: Ovotestis with testicular tissue (right) and ovarian tissue (left). From Baetens et al., 2017<sup>1</sup>

The abnormal right gonad consisted of ovarian tissue at the fimbrial pole and seminiferous tubules at the non-fimbrial pole. Karyotype analysis showed a 46XX/69XXY mixoploidy

## HYPOTHETICAL MECHANISMS

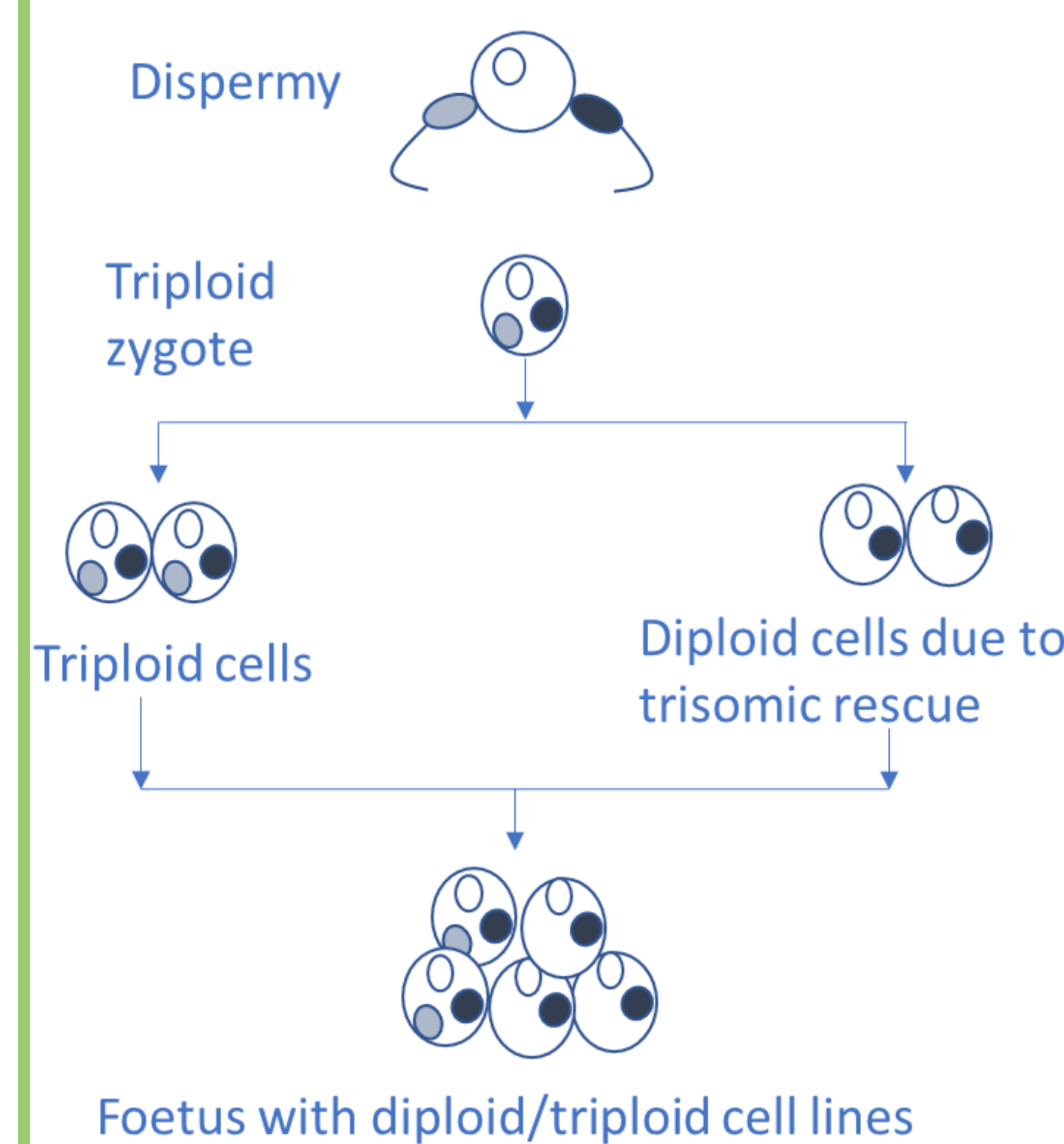


Figure 3: Possible mechanism. Ovum fertilised by two spermatozoa resulting in triploid zygote. Trisomic rescue in some cell lines resulting in foetus with triploid and diploid cells.

In the triploid cells from the gonad, further studies confirmed that one X chromosome was derived from the mother, but the other X and the Y chromosome from the father. We suggest that at the time of conception, one ovum was fertilised by two spermatozoa, followed by one of two events: firstly trisomic rescue in most cells (Figure 3). Loss of the paternal genome in some cell lines has been previously described as an explanation for mixoploidy<sup>4</sup>. Secondly, delayed fusion of one of the two paternal pronuclei, resulting in mixoploidy<sup>5</sup>. However, the true mechanism is unknown.

## MANAGEMENT QUESTIONS

### 1. What should be done about the right gonad?

There was multidisciplinary consensus that the right gonad should be removed due to the risk of malignancy and risk of further virilisation.

### 2. What should be done about the left gonad?

Did the macroscopically normal left gonad also have histological abnormalities? However, biopsy could risk damaging the single potentially viable ovary. The left gonad was eventually biopsied and shown to have normal ovarian histology.

### 3. Was Baby's phenotype explained by the ovotestis?

It was thought the presence of the Y chromosome explained her virilisation rather than the NR5A1 gene variant.

### 4. Could mixoploidy exist in other cell lines?

There have been case reports of 46XX/69XXY mixoploidy in skin fibroblasts with a normal blood karyotype<sup>6</sup>. Our baby has been thriving and developing normally. Further investigation is currently not indicated.

### 5. Importance of multidisciplinary management

This child highlighted the importance of parallel investigations and a multidisciplinary approach to clarify diagnosis and management.

## REFERENCES

1. Baetens D, Stoop H, Peelman F, Todeschini A-L, Rosseel T, Coppieters F, et al. NR5A1 is a novel disease gene for 46,XX testicular and ovotesticular disorders of sex development. *Genet Med*. 2017;19(4):367-76.
2. Swartz JM, Ciarlo R, Guo MH, Abhra A, Weaver B, Diamond DA, et al. A 46,XX Ovotesticular Disorder of Sex Development Likely Caused by a Steroidogenic Factor-1 (NR5A1) Variant. *Horm Res Paediatr*. 2017;87:191-5.
3. Bashamboo et al. A recurrent p.Arg92Trp variant in steroidogenic factor-1 (NR5A1) can act as a molecular switch in human sex development. *Hum Mol Genet*. 2016;25(16):3446-53.
4. Golubovsky MD. Postzygotic diploidization of triploids as a source of unusual cases of mosaicism, chimerism and twinning. *Hum Reprod*. 2003;18(2):236-42.
5. Wegner R-D et al. Fetal 46,XX/69,XXY mixoploidy: origin and confirmation by analysis of fetal urine cells. *Prenatal diagnosis* 2009; 29:287-9.
6. Jarvela IE, Salo MK, Santavuori P, Salonen RK. 46,XX/69,XXX diploid-triploid mixoploidy with hypothyroidism and precocious puberty. *J Med Genet*. 1993; 30:966-7.

