

Refractory Cyclical Cushing's Disease – A case of multiple pituitary micro-adenomas in a 3 year old girl after 8 years follow up

Elizabeth Robinson and Poonam Dharmaraj, Biochemistry and Endocrinology departments, Alder Hey Children's Hospital, Liverpool, U.K.
 Carl David Leith van Heyningen, Member of the Royal College of Paediatrics & Child Health, Educational Fellow, Leicester Royal Infirmary Hospital, U.K.

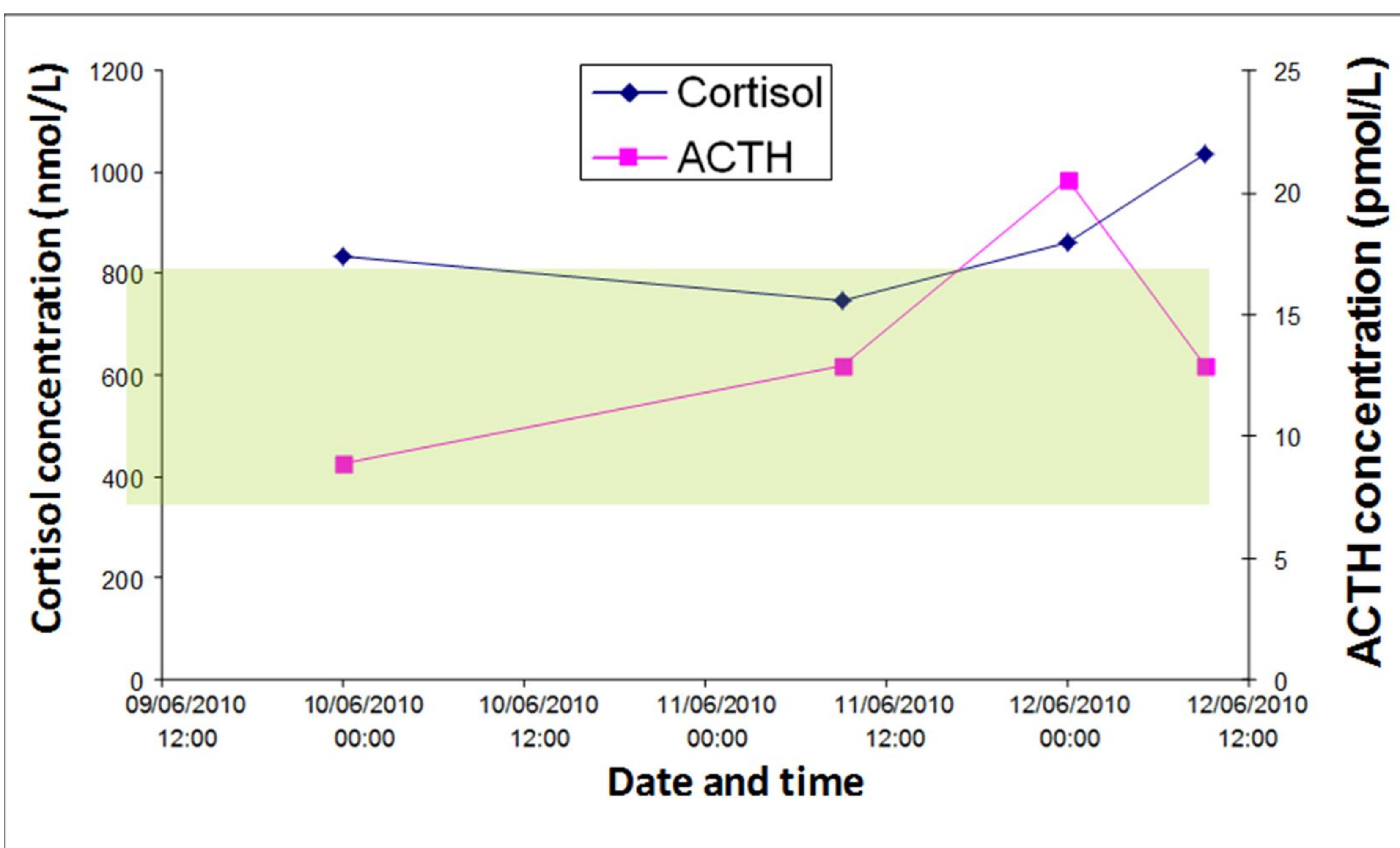
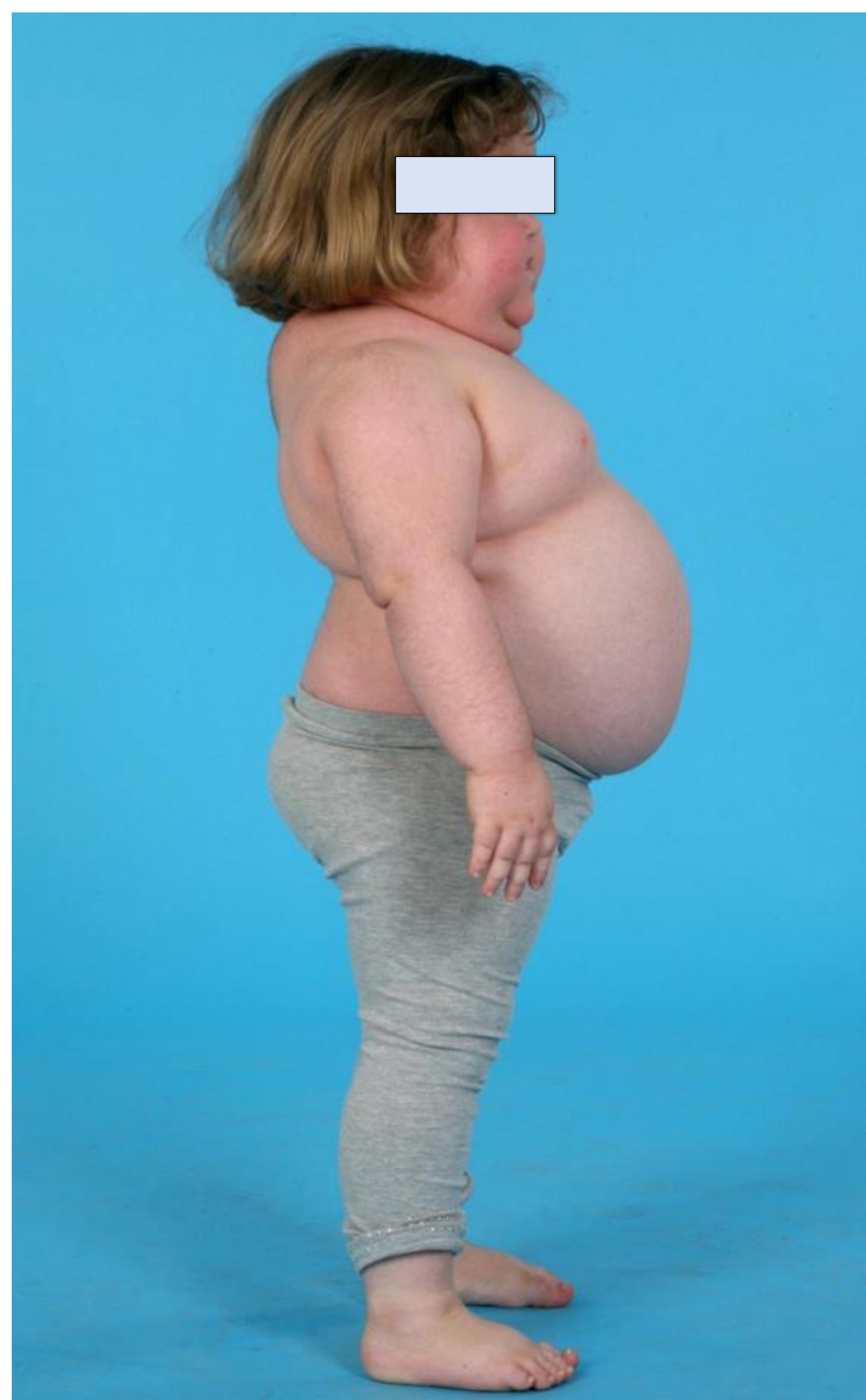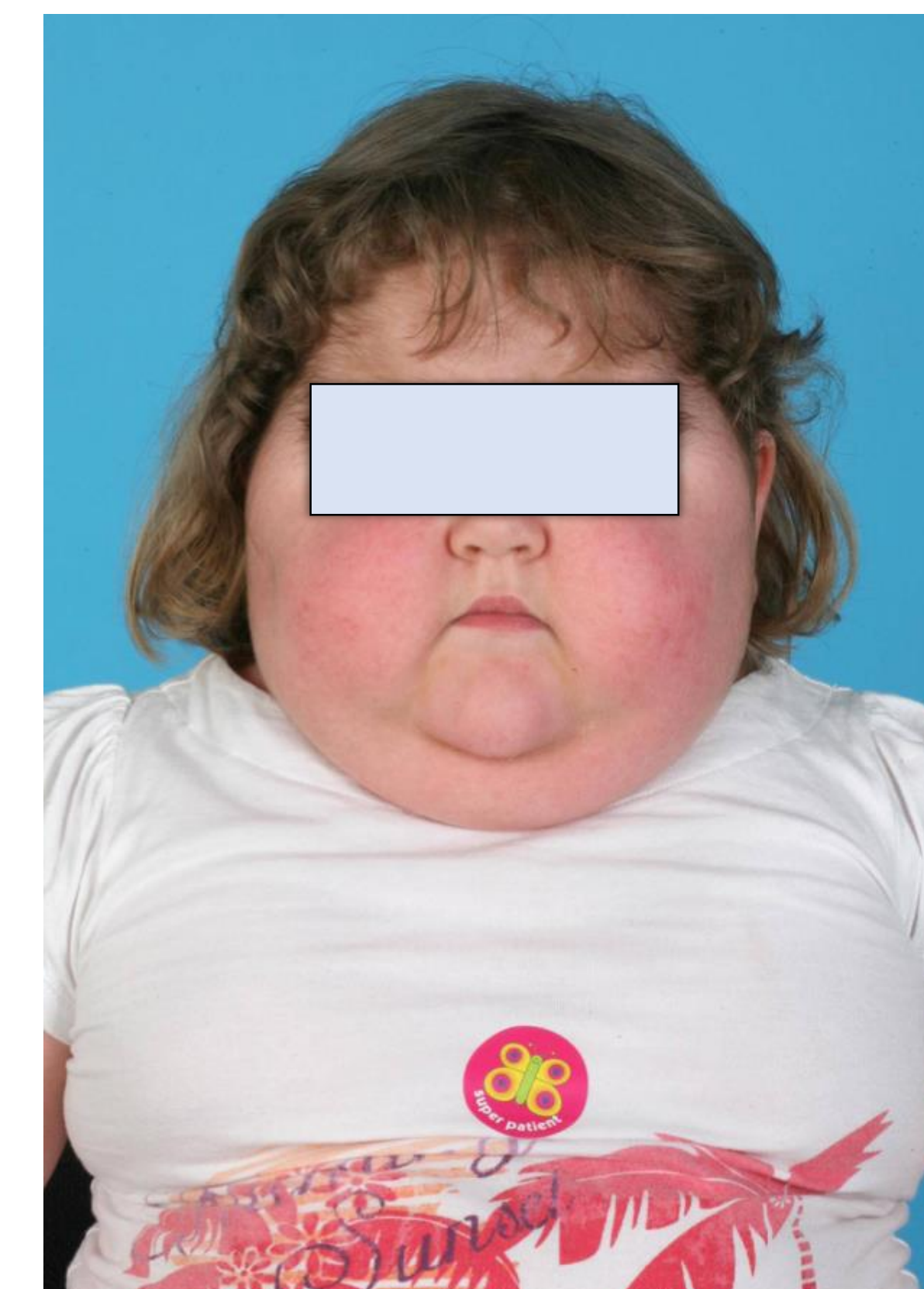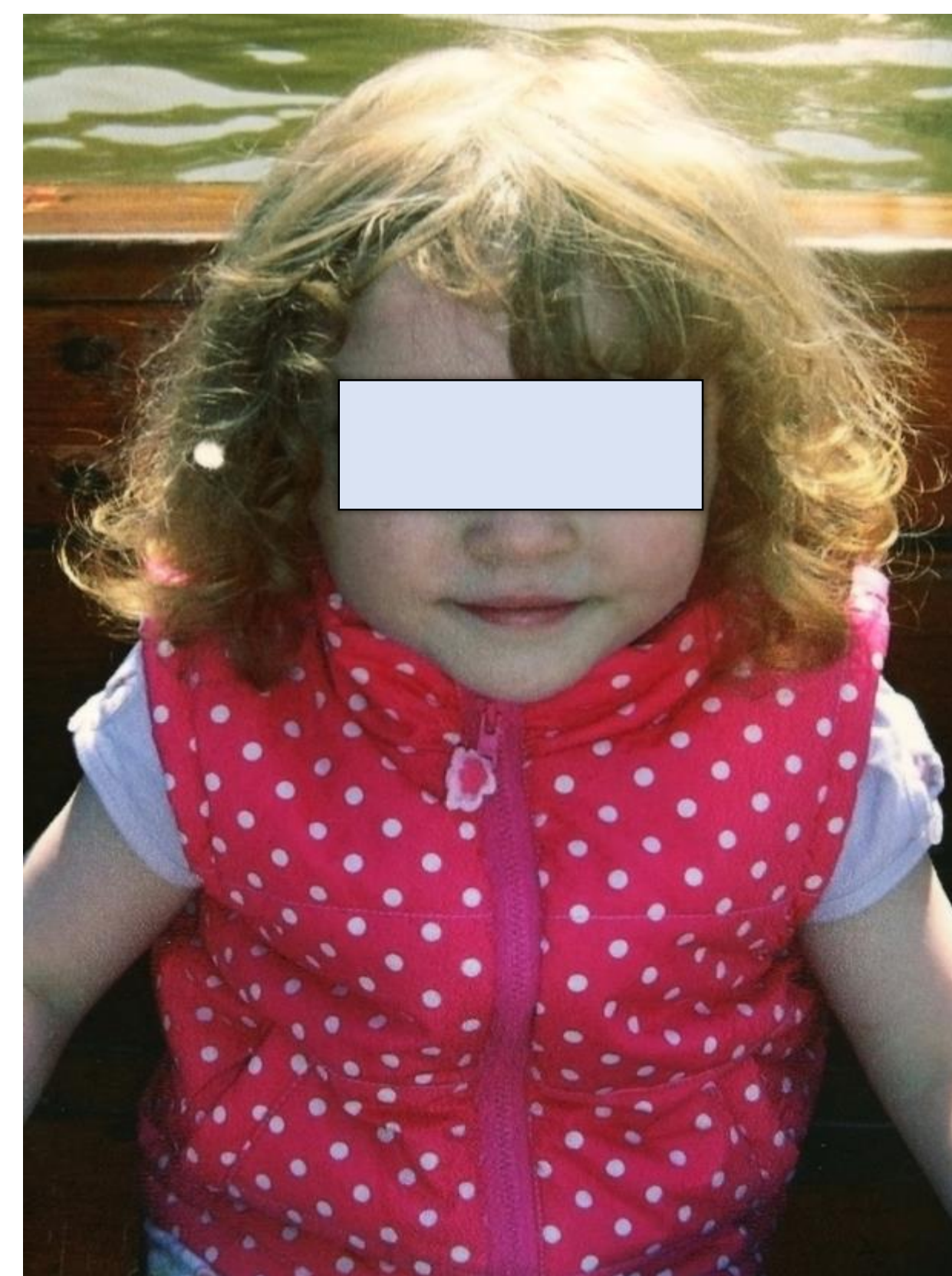Case presentation: A 3 years 10 months old British white girl presented with rapid weight gain of 11 Kg over 4 months, hirsutism, central obesity, moon face, buffalo hump and hypertension.

Investigations: Plasma cortisol, IGF-1 and ACTH levels were elevated. The 9am plasma cortisol was 1035 nmol/L (140-500) with simultaneous plasma ACTH 13 pmol/L (1-11). Plasma cortisol and ACTH levels responded to both dexamethasone suppression and CRH stimulation. Inferior petrosal sinus venous blood samples showed no significant ACTH left to right gradient before and after CRH stimulation. Magnetic resonance images of the adrenals and pituitary were normal. The findings suggested a pituitary cause, but no unilateral pituitary adenoma was identified.

Surgery: The whole anterior pituitary gland was removed by endoscopic trans-sphenoidal excision.

Histology and immunohistochemistry : Multiple pituitary micro-adenoma fragments were found within normal anterior pituitary tissue on histological examination. The fragments showed positive reactivity for both growth hormone and ACTH by immunohistochemistry. This confirmed a diagnosis of Cushing's disease with growth hormone excess.

Follow up: She made a good recovery over 3 years after surgery on hydrocortisone, growth hormone and thyroxine replacement therapy. No MEN1 gene mutation was found on genetic analysis. A relapse of Cushing's disease occurred 6 years after surgery and she was treated with repeat trans-sphenoidal pituitary surgery followed by pituitary radiotherapy. This further treatment was unsuccessful and she hence underwent a bilateral adrenalectomy eight years after initial presentation. A diagnosis of resistant cyclical Cushing's disease was made.



Inferior petrosal sinus sampling

Expected gradient : >2:1 (basal) and >3:1 (post CRH)

Time (min)		Peripheral	Right	Left
-5	Cortisol (nmol/L)	93	105	115
	ACTH (pmol/L)	3.7	4.1	3.5
20	Cortisol (nmol/L)	105	107	110
	ACTH (pmol/L)	8.6	9.6	7.7

Discussion: A review of the literature on endogenous Cushing's Syndrome in children identified that:

- (a) 2-5 new paediatric cases occur per 10 million people per year, (b) pituitary adenoma causing Cushing's disease is the commonest cause above age 7 years and adrenal tumour is the commonest cause below age 7 years, (c) multiple pituitary adenomas are very rare, occurring in up to 2.6% in surgical series, (d) the youngest previous case of paediatric Cushing's disease reported was in a five year old child.

Conclusion: This is the youngest child ever reported with multiple pituitary micro-adenomas causing refractory cyclical Cushing's disease. No genetic cause was identified. This report demonstrates that pituitary driven Cushing's disease may present difficult diagnostic and long term therapeutic challenges.