

# Growth hormone deficiency in neurofibromatosis: report of four cases

Elisa Guidoni, Ursula Geronzi, Federica Lotti, Laura Arianna Sorrentino, Salvatore Grosso, [Giovanna Municchi](#)

Department of Molecular Medicine and Development, Section of Pediatrics, University of Siena, Italy

UNIVERSITÀ  
DI SIENA  
1240

## Introduction

Short stature is frequently associated to neurofibromatosis (NF). In these patients this condition is often caused by growth hormone (GH) deficiency. We describe four boys affected by NF type 1 and GH deficiency treated with GH replacement therapy.

## Case Report

GH deficiency was diagnosed in four patients with NF type 1, who were referred to our Pediatric Endocrinology Unit for short stature.

### Patient 1

The boy started GH replacement therapy at the CA of 11.3 years, height was -2.5 SD, target height (TH) -1.5 SD. Tanner stage 1, bone age (BA) 8.5 years.

After 1 year on GH replacement therapy, height improved to -1.9 SD, Tanner stage 2, BA 9.5 years.

After 2 years height was -1.7 SD, Tanner stage 3, BA 12.5 years. (Figure 1-2)

The brain MRI didn't show any variations during follow-up.

Figure 1

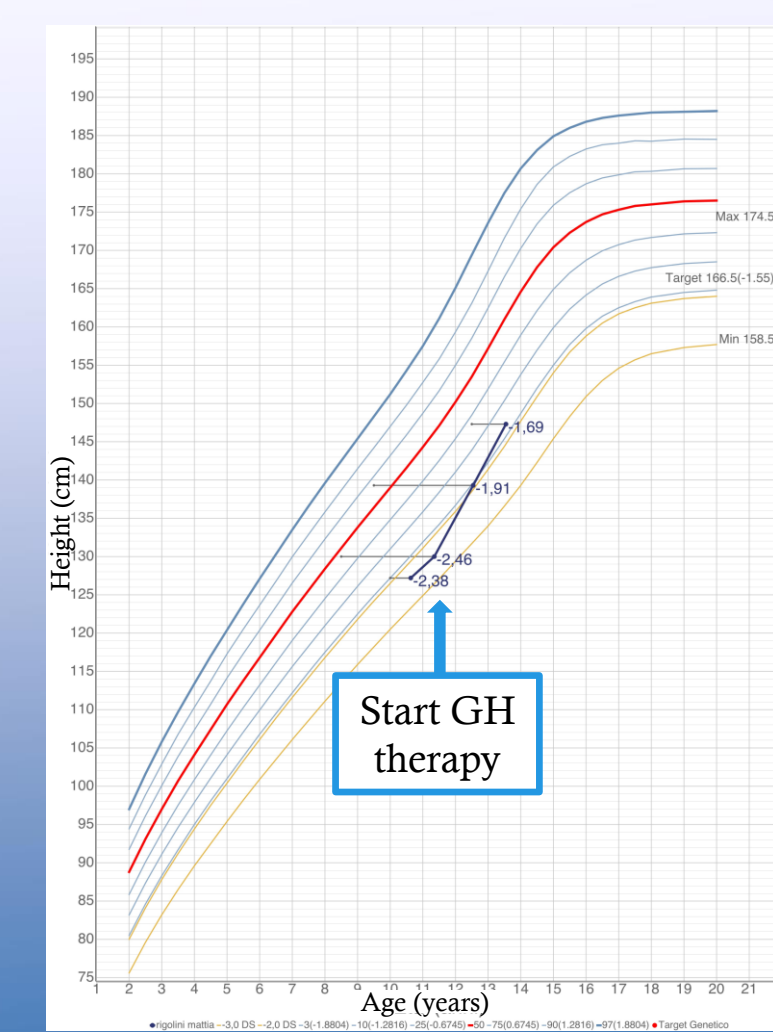
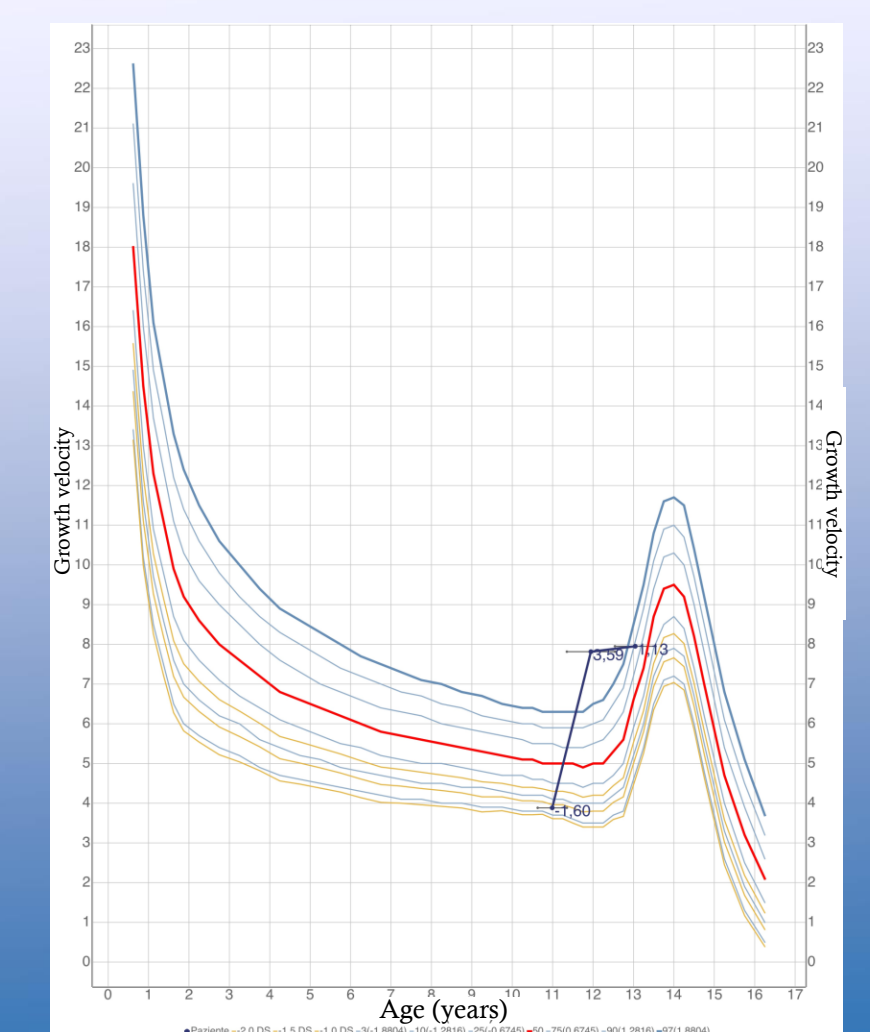


Figure 2



### Patient 2

The boy started GH replacement therapy at the CA of 11 years. He was prepubertal, height was -2.3 SD, TH -0.8 SD, BA 10 years.

During the first 6 months on GH treatment growth rate improved from 4 cm/years to 6 cm/years, even though calculated over a period of only 6 months. (Figure 3-4)

No adverse events were reported.

Figure 3

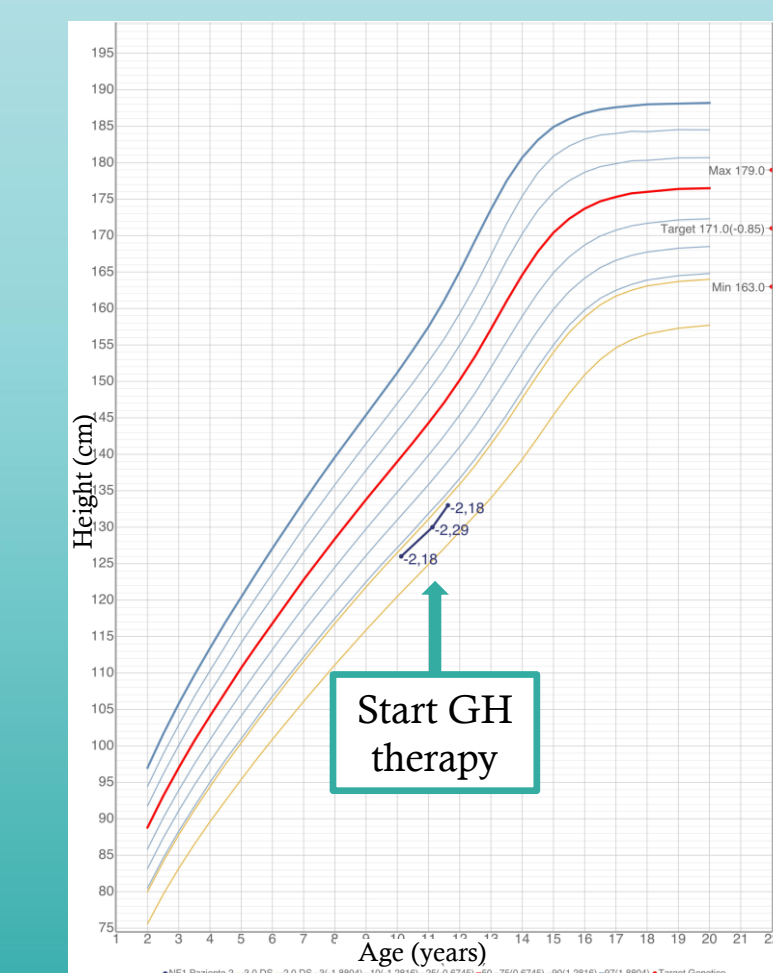
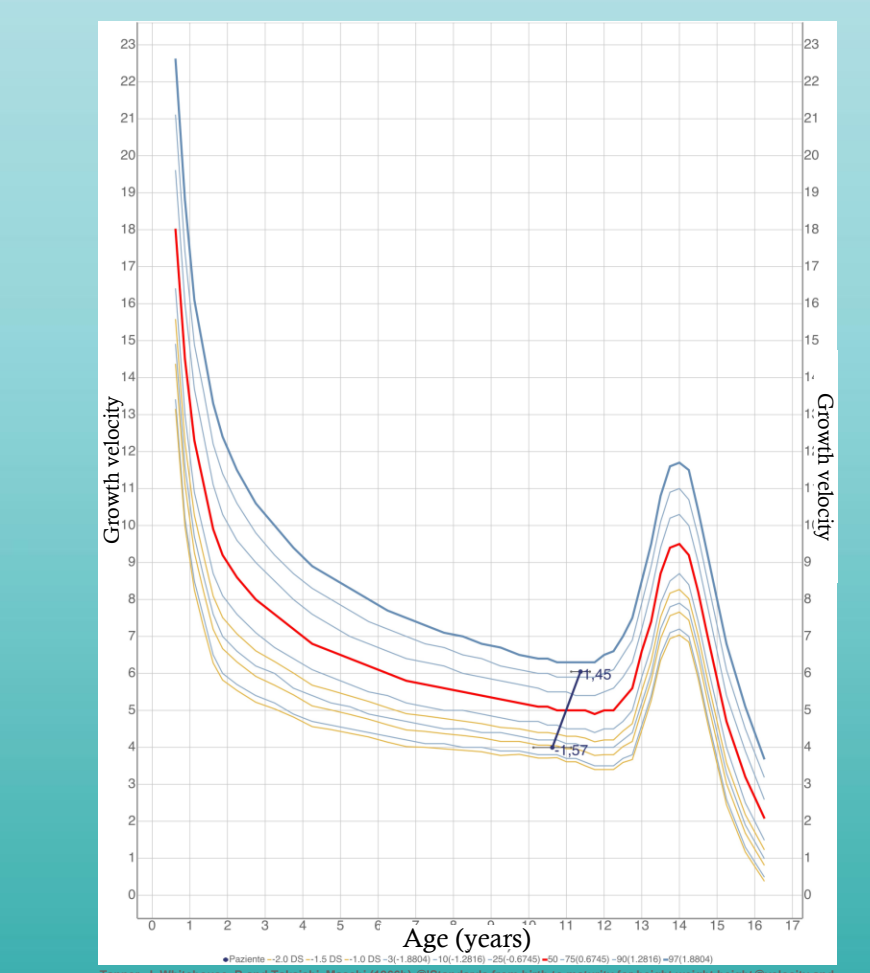


Figure 4



### Patient 3

The boy started GH replacement therapy at the CA of 9.5 years. He was prepubertal, height was -2.7 SD, TH -1.2 SD and BA 7.5 yrs. After three months on GH treatment height increased from -2.7 SD to -2.5 SD. (Figure 5-6)

Figure 5

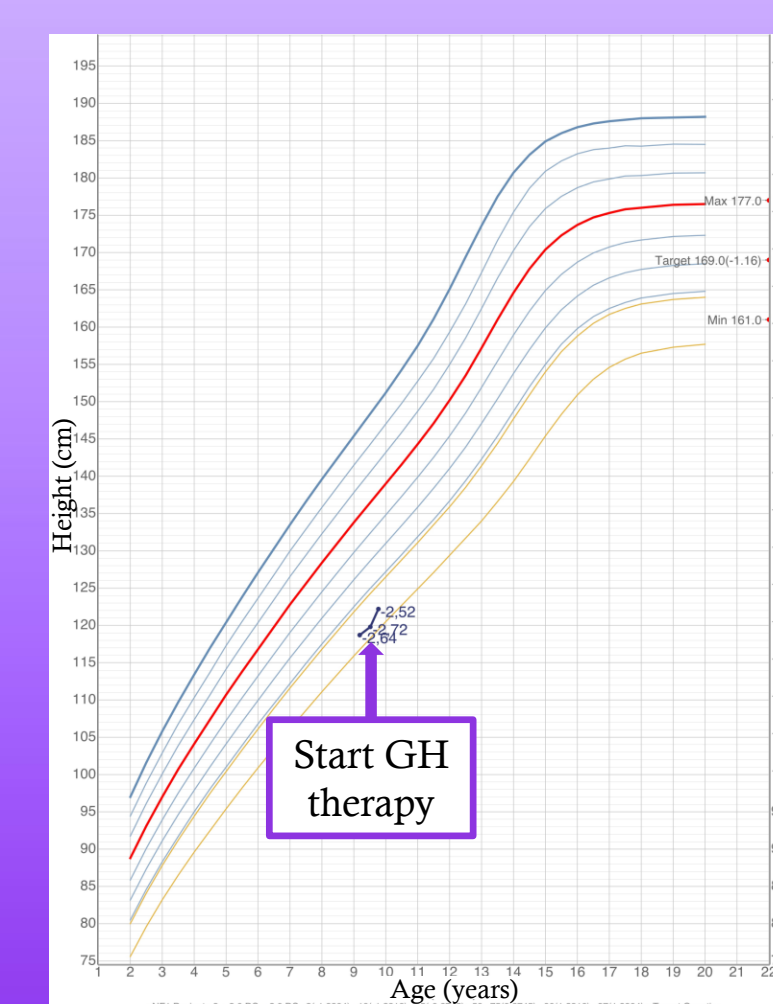
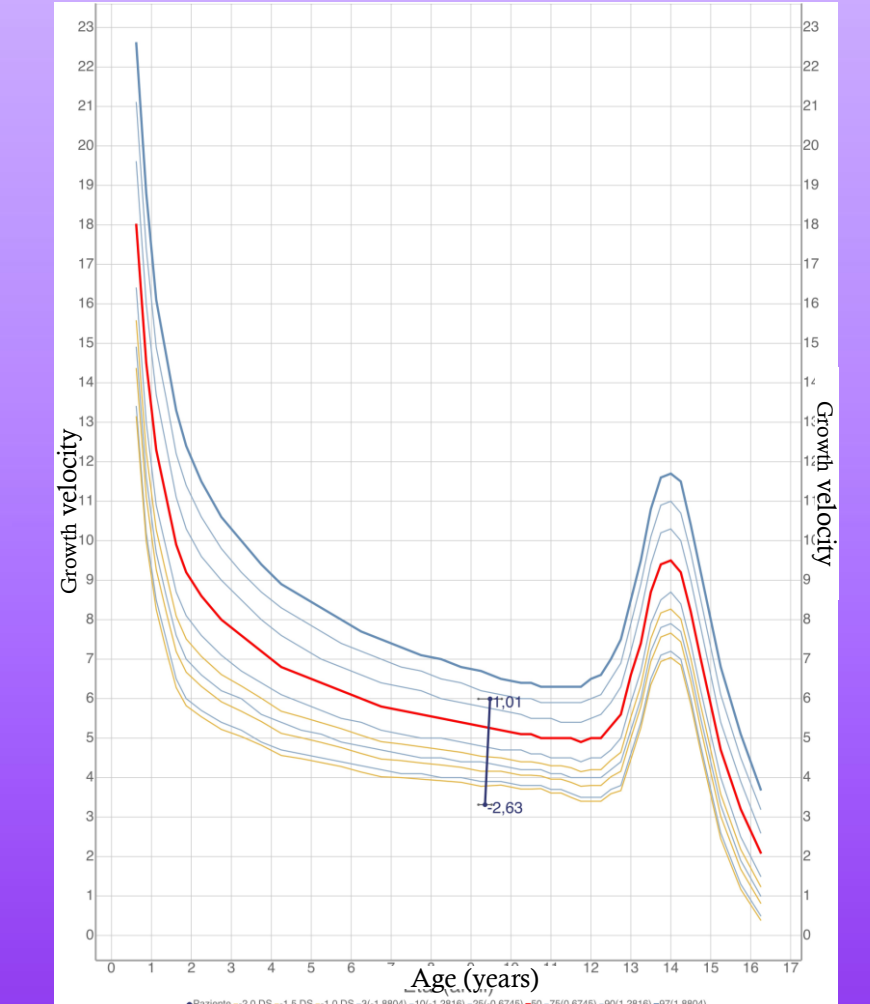


Figure 6



### Patient 4

The boy started GH replacement therapy at the CA of 8.8 years, height was -2.2 SD, TH -1.1 SD and BA 7 yrs.

After three months on GH replacement therapy height increased from -2.2 SD to -2.0 SD. (Figure 7-8)

Figure 7

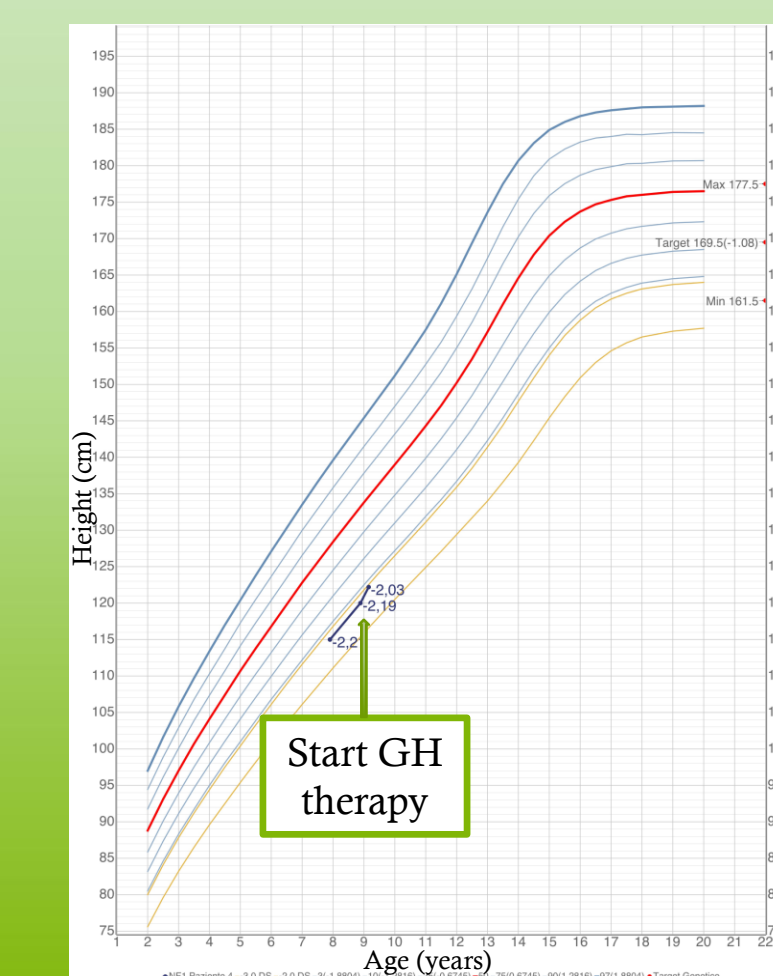
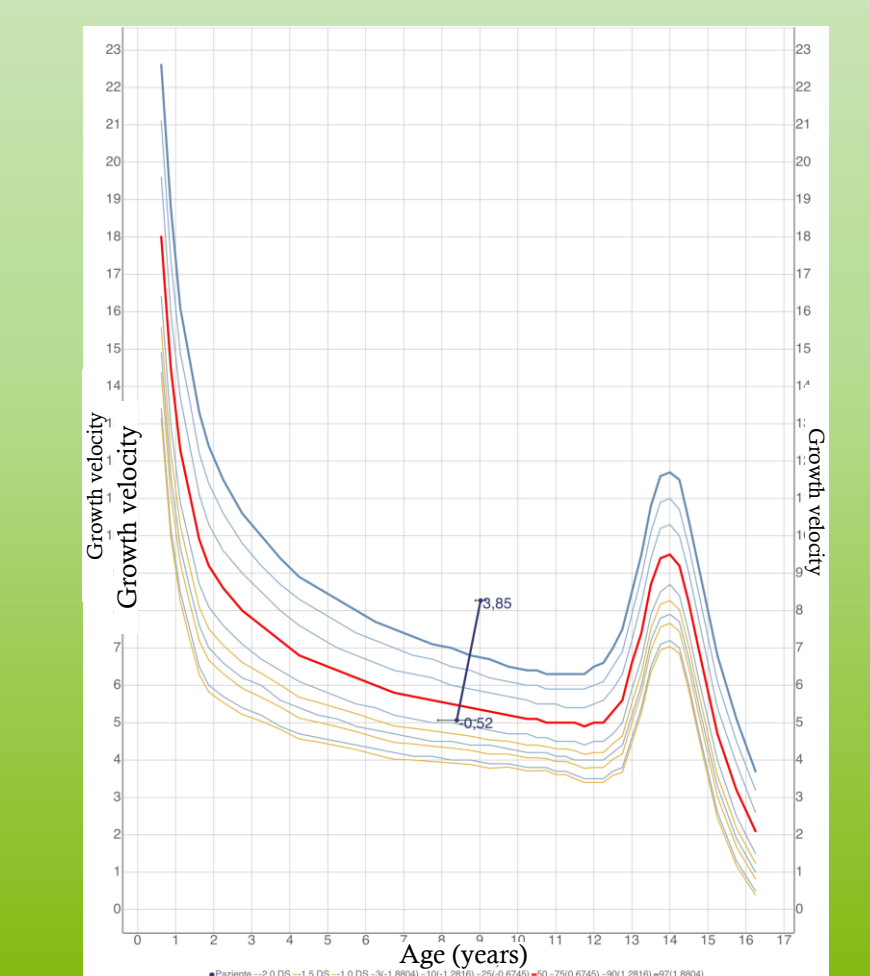


Figure 8



## Conclusions

Evaluation of GH secretion in children with NF-1 and short stature, in the absence of other identifiable causes of short stature, is necessary because GH therapy may significantly improve their growth rate. GH therapy has proven to be safe in NF patients and it is not associated with increased risk of malignancy.

## References

Growth hormone and neurofibromatosis. Howell SJ, Wilton P, Lindberg A, Shalet SM. Horm Res. 2000;53 Suppl 1:70-6. Review.

Growth Hormone Deficiency in a Child with Neurofibromatosis-Noonan Syndrome. Vuralı D, Gönç N, Vidaud D, Özön A, Alikışifoğlu A, Kandemir N. J Clin Res Pediatr Endocrinol. 2016 Mar 5;8(1):96-100.

