

Syndromic Patients With Negative Islet Autoantibodies Should Be Tested For Monogenic Diabetes: Lessons From Patients With TRMT10A Mutation

Zeynep Şıklar¹, Kevin Colclough², Kashyap A Patel³, Tuğba Çetin¹, Merih Berberoğlu ¹
¹ Ankara University School of Medicine , Pediatric Endocrinology, Ankara, Türkiye
² Molecular Genetics laboratory, Royal Devon and Exeter hospital, Exeter, UK
³ University of Exeter Medical School, Exeter, UK

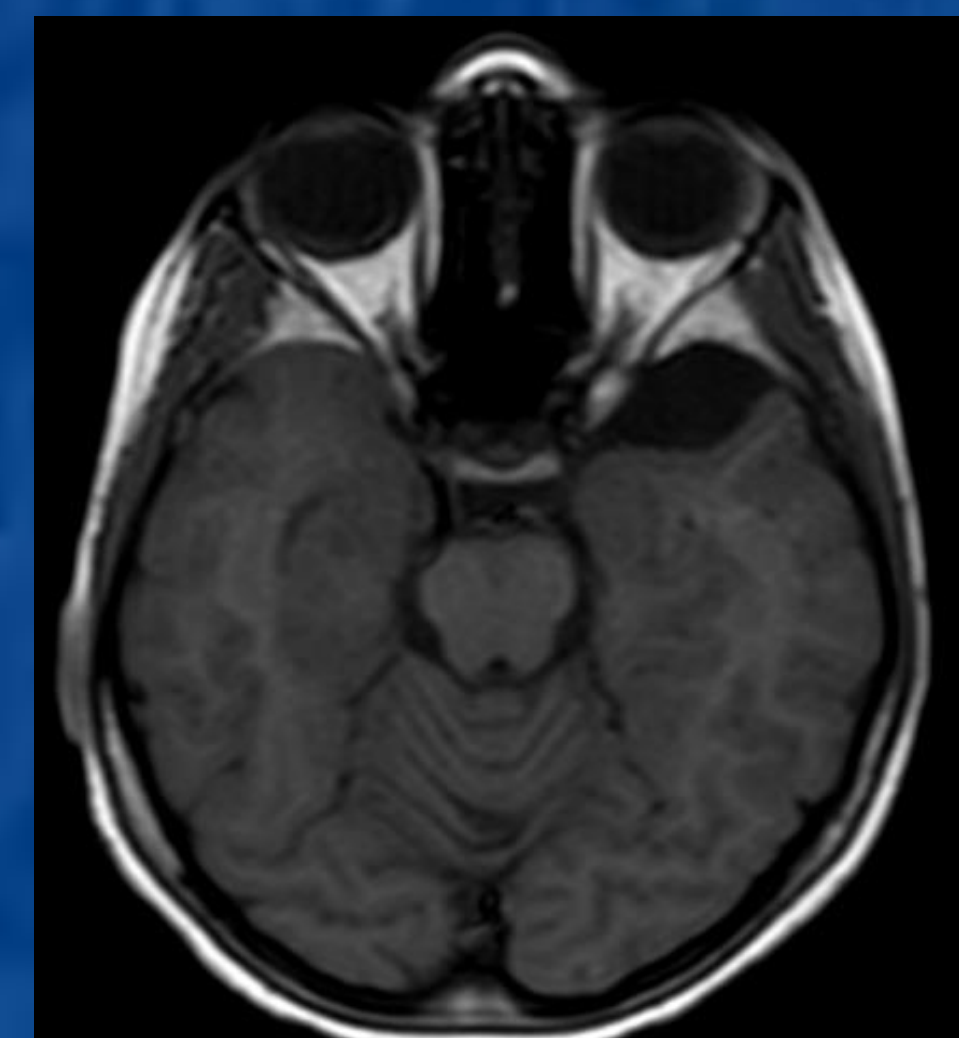
Aim:

Glucose metabolism can be affected by several genes, and some of them represent distinctive clinical and laboratory features. tRNA methyltransferase 10 homologue A (TRMT10A) gene is a tRNA methyl transferase, and localised to the nucleolus, where tRNA modifications occur. Very recently, a novel syndrome of abnormal glucose homeostasis or nonautoimmune diabetes associated with microcephaly, epilepsy, intellectual disability, failure to thrive, delayed puberty caused by mutations in the TRMT10A were reported in four families.

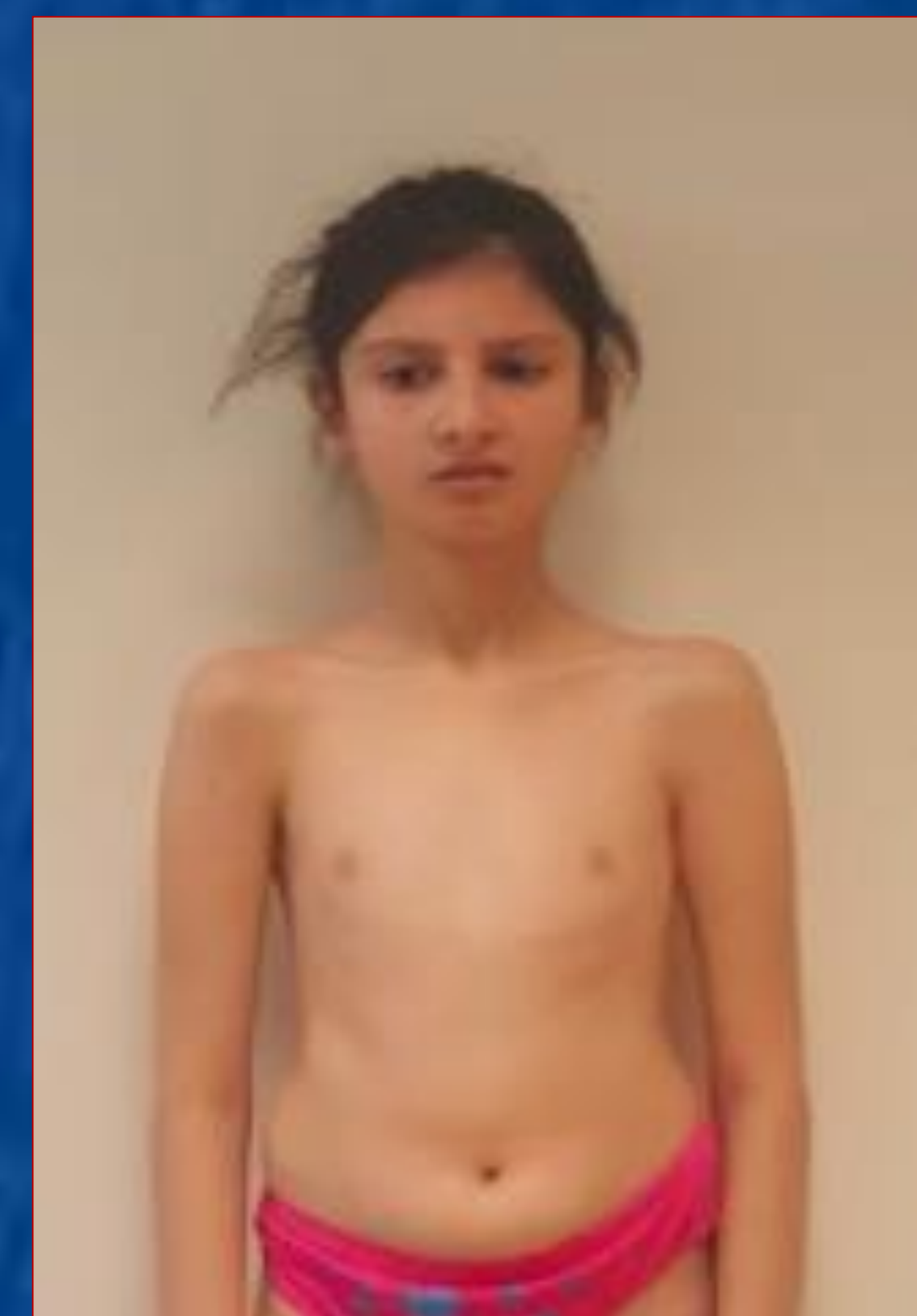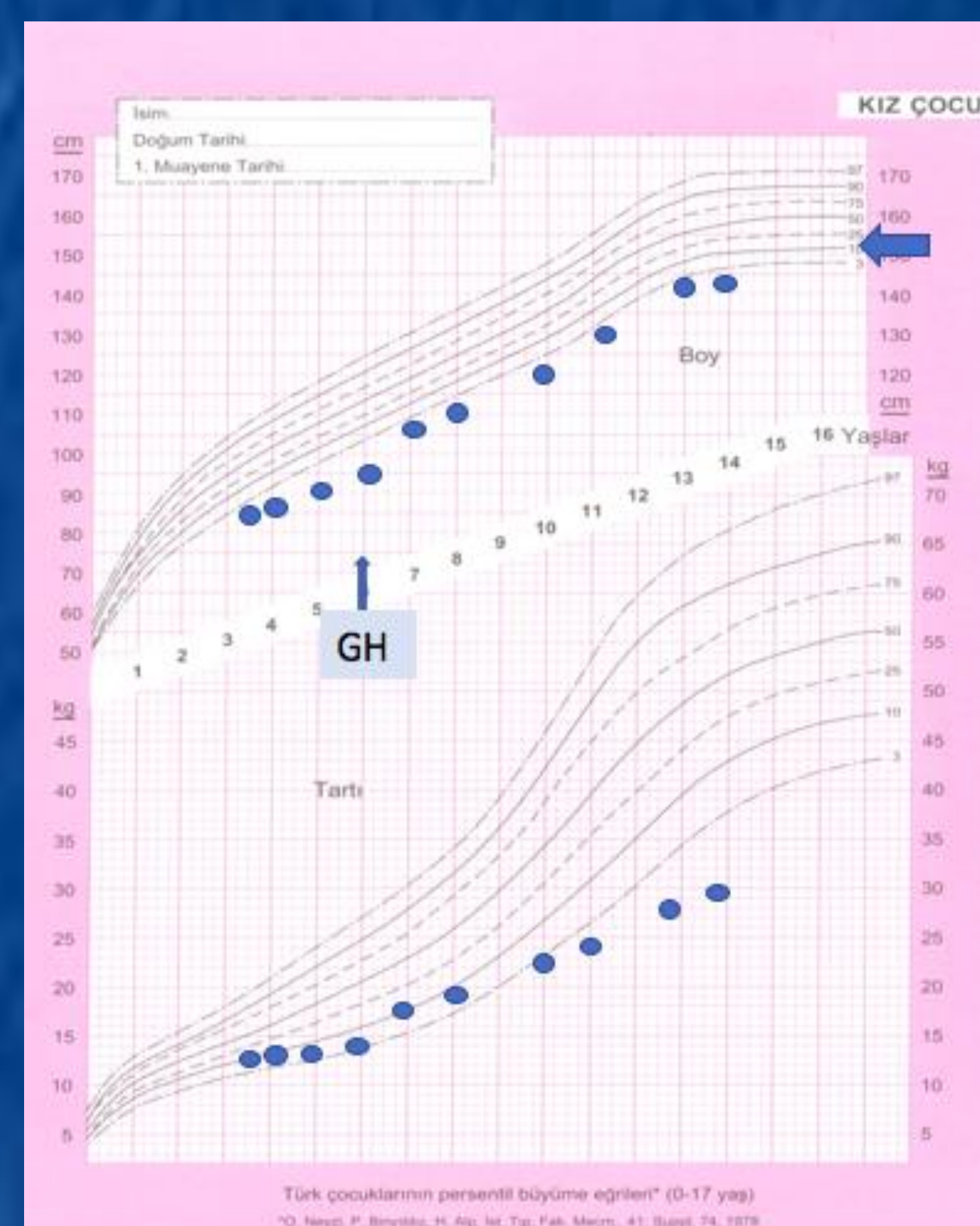
Case:

The patient was the second child born to non-consanguineous parents. The child's birth weight was 2100 g and she had microcephaly. She was found to have difficulty in feeding at the first two years of age, not getting enough weight, fasting hypoglycemia and retarded neuromotor development with mild intellectual disability (24 months walking, 36 months speech). Dysmorphic features were apparent from early age, including a small face and deeply located eyes. She was diagnosed with epilepsy at 2.5 years old and treated with phenobarbital. At 3.65 years of age, her height was SDS: -3.26, weight was SDS:-2.22, and bone age was 2 years and 6 months. Growth hormone stimulation tests appropriate with partial growth hormone deficiency. Growth velocity was low during follow-up, then at 5.47 years of age rhGH therapy was initiated. She had incidental diagnosis of diabetes at age 11.41 years. She had no antibodies, normal c-peptide level (1.29 ng/ml) and treated with Metformin. Pubertal delay and low basal and stimulated gonadotropins were detected at the age of 13 years, and the patient underwent estrogen replacement.

At last examination, she is 14,25 years of age while receiving GH therapy. Height: 142 cm (Hsds:-2,95), Weight: 29,4 kg, RBMI: 72% and bone age is 13 years old. With metformin therapy, blood glucose level were normal and HbA1c level was 6.8%.



On the cranial imaging, a pituitary normal structure, but an anterior arachnoid cyst of the left temporal lobe 3.5x2 cm was detected.



Mutation of the *TRMT10A* NM_001134665.2:c.379C>T (p.Arg127*) was detected

Conclusion:

TRMT10A gene mutation appears to cause a syndrome of intellectual disability, microcephaly and delayed puberty. These features are associated with an unusual form of impaired glucose metabolism presenting in early childhood with hypoglycemia and nonautoimmune insulinopenic diabetes becomes evident as in our patient. Arachnoid cyst, although not reported before, and hypophyseal dysfunction can be additional findings of this syndrome. Slow onset diabetes with antibody negative with extra pancreatic features should be tested for monogenic diabetes.

