

THYROID NODULES IN PRADER-WILLI SYNDROME

Graziano Grugni¹, Alessandro Minocci², Alessandro Sartorio^{1,2} and Antonino Crinò³

¹Division of Auxology and ²Division of Metabolic Diseases, Italian Auxological Institute, Research Institute, Piancavallo (Verbania); ³Autoimmune Endocrine Disease Unit, Bambino Gesù Children's Hospital, Research Institute, Rome; ITALY.

Disclosure statement: all authors have nothing to disclose.

Introduction

Prader-Willi syndrome (PWS) is a complex multisystem disorder due to loss of expression of paternally derived genes in the PWS critical region on chromosome 15q11-q13. The majority of the cases are due to the deletion of this region (del15), while 20-30% are caused by a maternal uniparental disomy of chromosome 15 (UPD15). The syndrome affects multiple organ systems (Box1), including numerous endocrine abnormalities. Disturbances in the hypothalamic-pituitary-thyroid axis are observed with variable frequency in PWS. Hypothyroidism is the most frequent alteration, mainly but not exclusively of central origin. Other thyroid abnormalities in PWS subjects are rarely reported, including congenital hypothyroidism caused by an ectopic sublingual thyroid gland and fetal goiter. On the other hand, data on the ultrasonographic examination of the thyroid gland in PWS subjects are not currently available.

Objectives

Aim of this study was to evaluate the thyroid morphology and function in a group of young adults with PWS.

Patients and Methods

The patients' group consisted of 20 subjects with typical PWS clinical phenotype [12 females, aged 30.6±5.9 yr (mean±SD) (range 18-39 yr), Body Mass Index (kg/m²) 46.7±8.8 (range 35.8-63.5)]. Thyroid function tests (fT3, fT4 and TSH), including anti-thyroid antibodies (TPOAbs and TGABs), and thyroid ultrasonography (TUS) were performed in all individuals. All TUS were performed and analyzed by the same operator.

Results

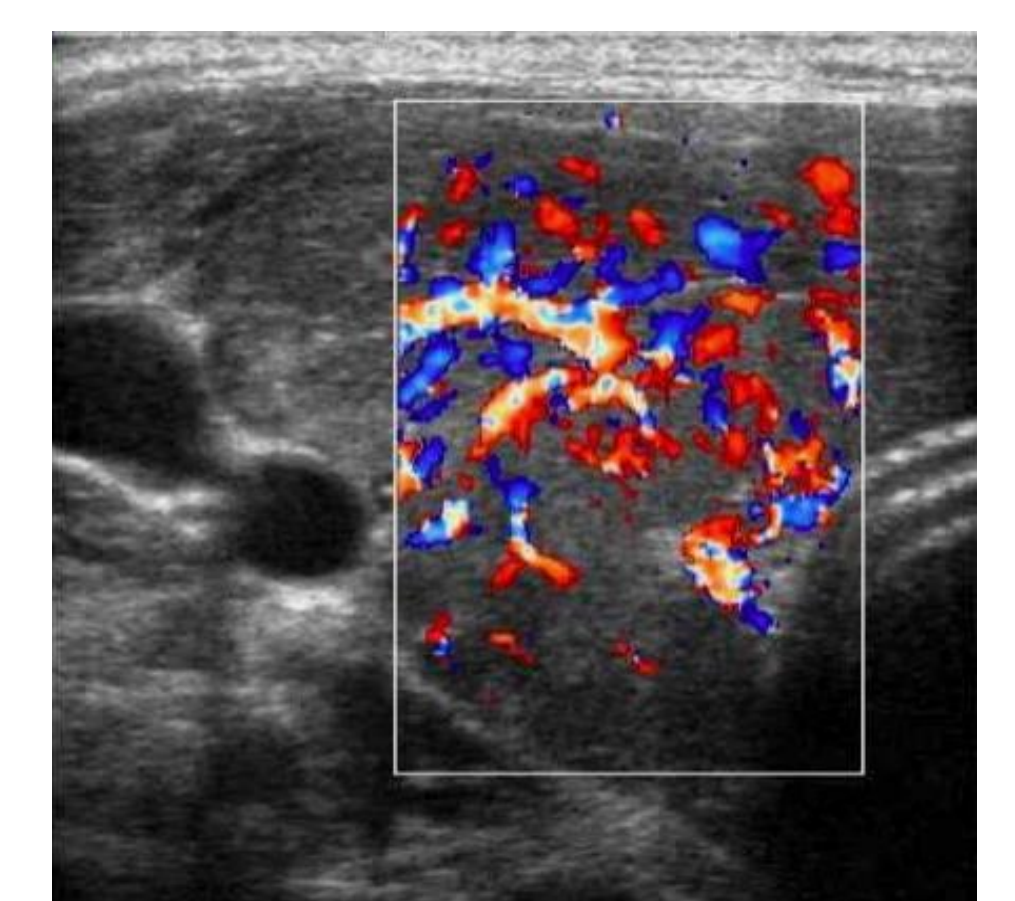
Eighteen PWS subjects were euthyroid, while 1 female had central hypothyroidism and 1 female showed an overt hyperthyroidism. Anti-thyroid antibodies were negative in all patients (including thyrotropin receptor antibody in the hyperthyroid individual). TUS characteristics of the study group are reported in Tables 1 & 2.

Table 1

	Thyroid vascularization	%	Echogenicity	%
Normal	15 pts	75	13 pts	65
Hypo-	5 pts	25	6 pts	30
Hyper -	0 pts	0	1 pts	5

Table 2

	yes	%	no	%
Microcalcifications	2 pts	10	18	90
Nodule(s) (>5 mm)	6 pts	30	14	70
single	2 pts	10		
2 or more	4 pts	20		



pts 16

Conclusions

Up until the last decade the thyroid axis of PWS subjects was generally considered to be normal or slightly altered, with a similar frequency of hypothyroidism in comparison to the general population. More recently, other studies reported a higher prevalence of hypothyroidism in PWS, mostly due to a central defect of central origin (hypothalamic hypothyroidism). At present, data on the incidence of other thyroid alterations, including primary hypothyroidism, are inconsistent in these patients. In this context, no data on ultrasonographic features of the thyroid in PWS subjects has been previously reported. Overall we found that alterations in thyroid structure can be frequently observed in young adults with PWS, indicating that screening for altered thyroid morphology should be a routine element of care for people with PWS.

References

- *Insoft RM, Hurvitz J, Estrella E, Krishnamoorthy KS. Prader-Willi syndrome associated with fetal goiter: a case report. *Am J Perinatol.* 1999;16:29-31.
- *Tauber M, Barbeau C, Jouret B, Pienkowski C, Malzac P, Moncla A, Rochiccioli P. Auxological and endocrine evolution of 28 children with Prader-Willi syndrome: effect of GH therapy in 14 children. *Horm Res.* 2000; 53(6):279-87.
- *Sher C, Bistrizter T, Reisler G, Reish O. Congenital hypothyroidism with Prader-Willi syndrome. *J Pediatr Endocrinol Metab.* 2002;15:105-7.
- *Butler MG, Theodoro M, Skouse JD. Thyroid function studies in Prader-Willi syndrome. *Am J Med Genet A.* 2007;143:488-92.
- *Festen DA, Vissert TJ, Otten JB, Wit JM, Duivenvoorden HJ, Hokken-Koelega ACS. Thyroid hormone levels in children with Prader-Willi syndrome before and during growth hormone treatment. *Clin Endocrinol.* 2007;67:449-56.
- *Vaiani E, Herzovich V, Chaler E, Chertkoff L, Rivarola MA, Torrado M, Belgorosky A. Thyroid axis dysfunction in patients with Prader-Willi syndrome during the first 2 years of life. *Clin Endocrinol.* 2010;73(4):546-50.
- *Diene G, Mimoun E, Feigerlova E, Caula S, Molinas C, Grandjean H, Tauber M. French Reference Centre for PWS. Endocrine disorders in children with Prader-Willi syndrome—data from 142 children of the French database. *Horm Res Paediatr.* 2010;74:121-8.
- *Sharkia M, Michaud S, Berthier MT, Giguère Y, Stewart L, Deladoëy J, Deal C, Van Vliet G, Chanoine JP. Thyroid function from birth to adolescence in Prader-Willi syndrome. *J Pediatr.* 2013;163:800-5.
- *Bocchini S, Fintini D, Grugni G, Boiani A, Convertino A, Crinò A. Congenital hypothyroidism due to ectopic sublingual thyroid gland in Prader-Willi Syndrome: a case report. *It J Pediatr* 2017;43:87.

Box 1 | Clinical characteristics of PWS

Obesity and its comorbidities

Hyperphagia and early onset of severe obesity (if uncontrolled); type 2 diabetes mellitus; right heart dysfunction; arterial hypertension; sleep disorders; gallstones; hepatic steatosis

Endocrine abnormalities

Short stature and GH-IGF-1 axis dysfunction; hypogonadism; premature adrenarche; central hypothyroidism; central adrenal insufficiency (rare)

Musculoskeletal issues

Muscular hypotonia (causing decreased fetal movements, initial poor feeding and failure to thrive); scoliosis and/or kyphosis; osteoporosis; hip dysplasia

Cognitive, behavioural and psychiatric disturbances

Mental retardation; typical behavioural problems; skin picking; psychiatric illness; speech articulation defects

Dysmorphic features

Characteristic facial appearance; small hands and feet; narrow hands with straight ulnar border

Miscellaneous

Hypopigmentation; esotropia and/or myopia; viscous saliva; high pain threshold; reduced incidence of vomiting; thermoregulatory disorders; unusual skill with jigsaw puzzles

Abbreviations: GH, growth hormone; IGF-1, insulin-like growth factor 1; PWS, Prader-Willi syndrome.