

A case of combination of multinodular goiter and Sertoli-Leydig cell ovarian tumor due to mutation in *DICER1* gene

Anna Kolodkina, Nina Makretskaya, Anatoly Tiulpakov
Endocrinology Research Centre, Moscow, Russian Federation

Background.

Pathogenic germline *DICER1* variants cause a hereditary cancer predisposition syndrome with a variety of manifestations. In addition to conferring increased cancer risks for pleuropulmonary blastoma (PPB) and ovarian sex cord-stromal tumors, particularly Sertoli-Leydig cell tumor, Individuals with pathogenic germline *DICER1* variants may also develop lung cysts, cystic nephroma, nodular hyperplasia of the thyroid, ciliary body medulloepithelioma, genitourinary embryonal rhabdomyosarcoma and brain tumors including pineoblastoma and pituitary blastoma.

Objective

To present a case of the patient with Sertoli-Leydig cell tumor of the ovary and multinodular goiter due to a novel *DICER1* gene mutation.

Clinical case

A girl presenting at 16 years with complains of voice coarsening, irregular cycle, clitoral hypertrophy, pains in the lower abdomen and thyroid enlargement.

Disease history

Menarche was at the age of 11, regular menstrual cycle was until the age of 13, there after irregular. The last cycle at the age of 15. Voice coarsening was revealed at age of 14. A multinodular goiter was identified at the age of 16 (histologically – colloid goitre)

Hormonal tests

LH 17.2 IU/L (2.4-5.4), FSH 2.59 IU/L (1.9-3.7), estradiol 18.35 pmol/l (143-264), testosterone 8.85 nmol/l (0.6-2.3), DHEA-S 6.13 μ mol/l (0.9-11.7), androstenedione 30.2 nmol/l (1-12, 2), TSH 1.25 mIU/l (1.3-4.9), f.T4 15.3 pmol/l (10-25).

Pelvic Ultrasound: a tumor (11.0 x 7.5 x 11.0 cm) with a dense capsule, with multiple cystic components in the right ovary

Oncomarkers (CA19-9, HE-4, alpha fetoprotein) were negative.

The patient underwent the resection of the right ovary. Histological examination: Sertoli-Leydig cell ovarian tumor with areas of hemorrhage and decay.

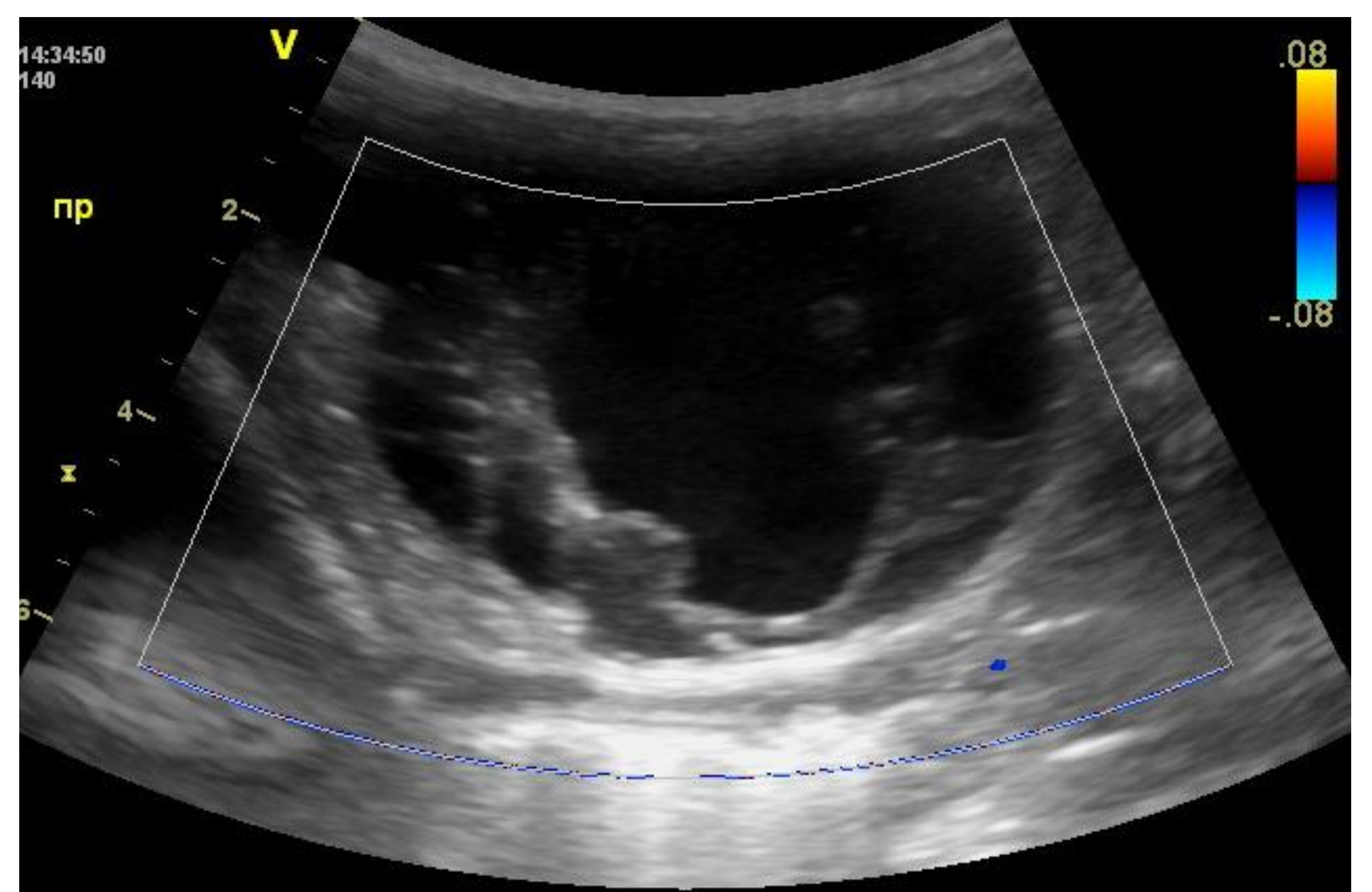
Family history: a multinodular goiter in the mother.

Methods

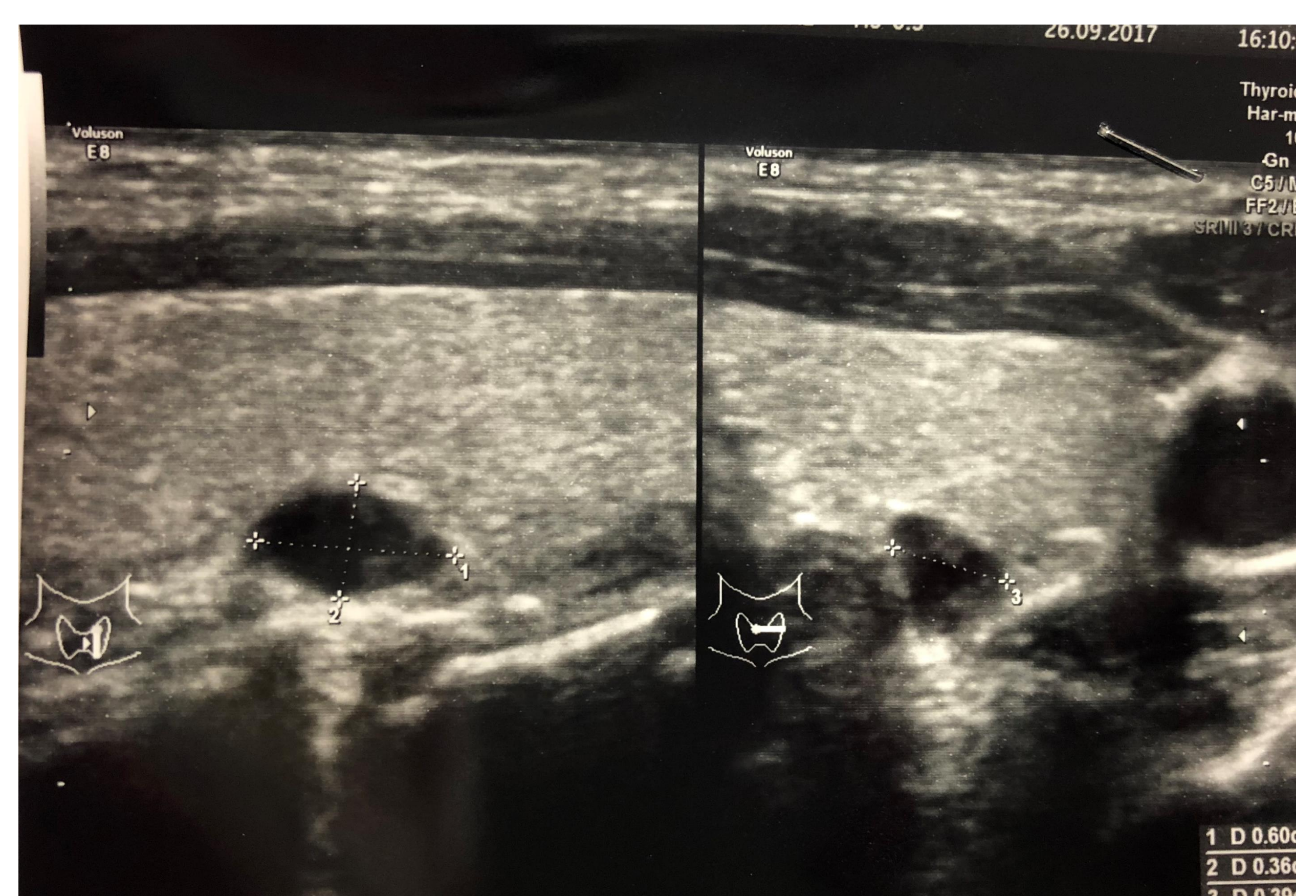
'Pituitary adenomas panel' genes were sequenced using a custom Ion Ampliseq gene panel and PGM semiconductor sequencer (Ion Torrent).

Results.

A heterozygous mutation p.A969CfsX5 was found in *DICER1* gene.



Multiple cystic components were detected in the right ovary



Multinodular goiter



Financial support:

This work was supported by Alfa-Endo Program of Charities Aid Foundation (CAF) Russia.