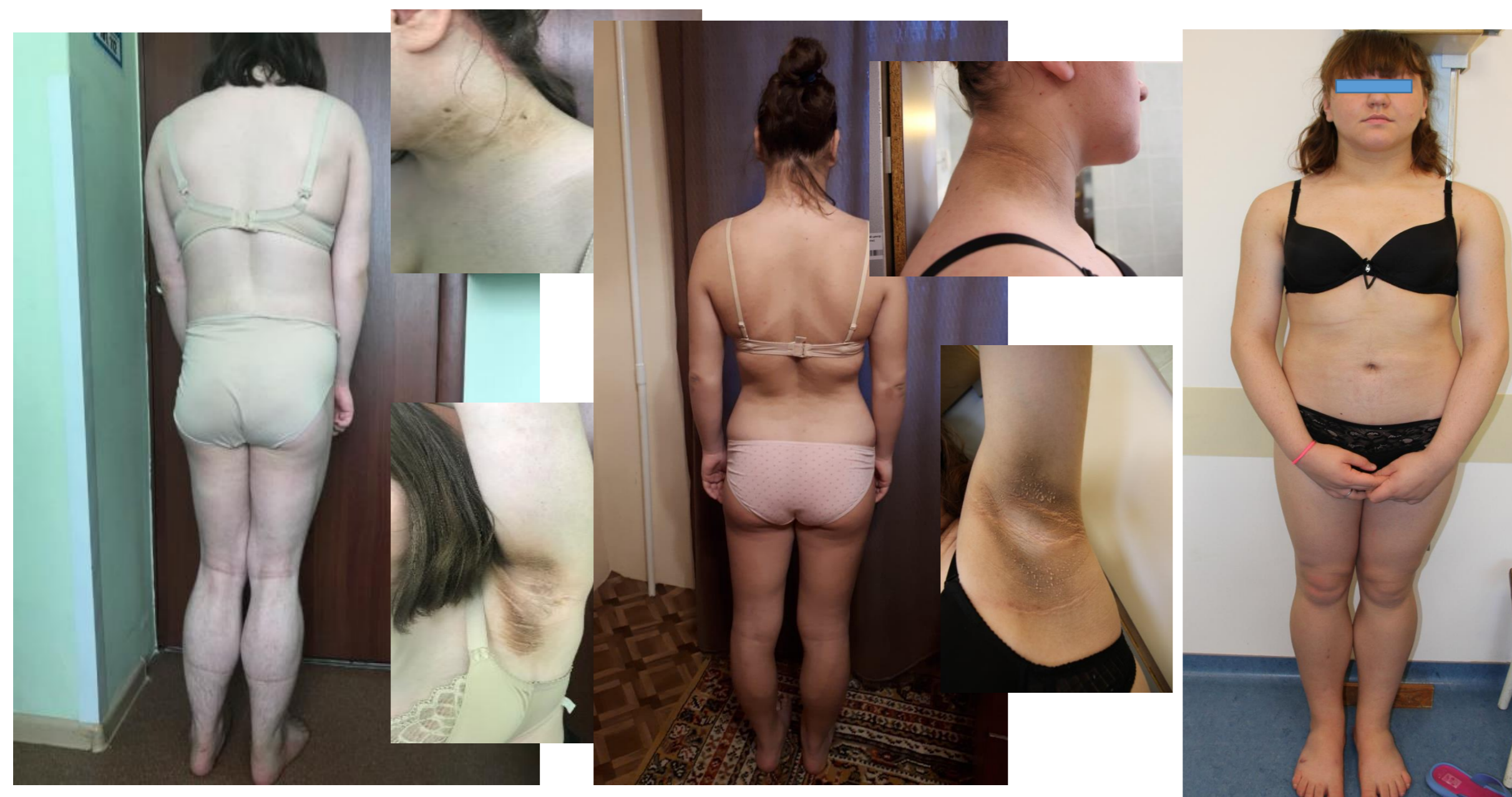

**Background.** The *PLIN1* gene encodes perilipin - a lipid droplet coat protein expressed in adipocytes where it inhibits basal and facilitates stimulated lipolysis. Mutations in *PLIN1* have been described in several families with partial lipodystrophy, dyslipidemia and insulin resistance (partial lipodystrophy type 4, Familial, FPLD4) [1, 2]. Herein we describe a novel heterozygous c.1210-1delG splicing variant in *PLIN1* gene in three unrelated Russian patients with FPLD4 phenotype.

**Aims.** To present the three patients with partial lipodystrophy and characterize a novel *PLIN1* mutation.

**Methods.** Molecular genetic analysis using a custom Ion AmpliSeq next generation sequencing ‘Lipodystrophy’ panel and PGM sequencer (Thermo Fisher Scientific, USA) was performed in all three subjects. NGS results were confirmed by Sanger sequencing. Total RNA was isolated from subcutaneous fat obtained by a needle biopsy in one of the patients. cDNA was synthesized using random hexamer primers and *PLIN1* transcripts covering exons 8-9 were amplified by PCR and sequenced.

**Phenotype.** Two girls (14.1 and 15.3 years) were referred to our clinic with suspicion of acromegaly, one girl (14.2 years) was referred with polydipsia, polyuria. All three patients shared similar clinical (Fig. 1) and metabolic findings: acromegalic features, loss of subcutaneous fat from extremities, excess fat depots of the face and neck, prominent muscular appearance of the calves, acanthosis nigricans, hirsutism, steatohepatitis, mild hypertension; hypertriglyceridemia and insulin resistance. 2 of 3 girls had mild diabetes mellitus. One girl had a history of recurrent pancreatitis and partial resection of the pancreas due to pancreatic necrosis. Her mother showed a similar phenotype. The family histories of the two other patients were unremarkable.



**Figure 1.** Clinical presentation of the patients with FPLD4.

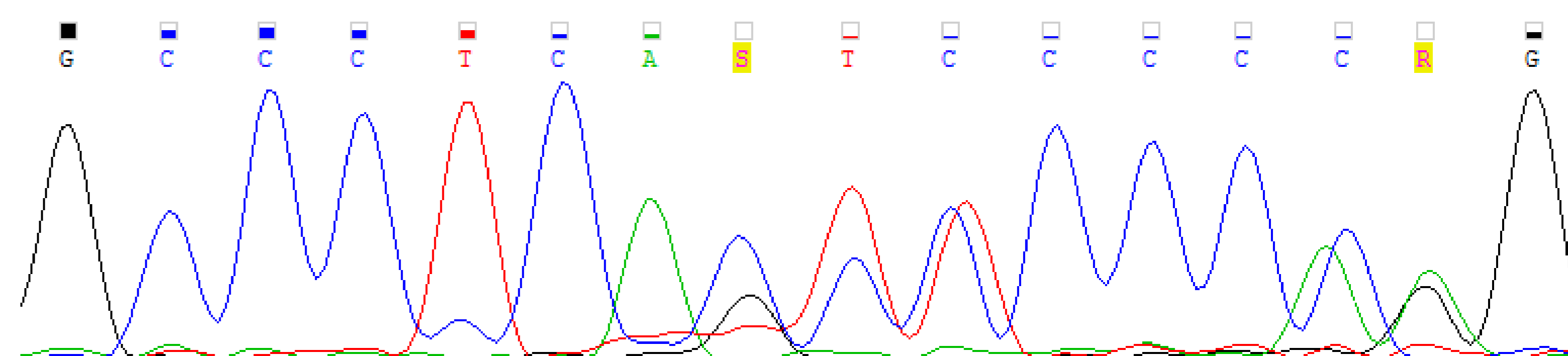
**Table 1 Clinical data**

	Age, yr	BMI SDS	Dx of LD, yr	Dx of DM, yr	PCOS	Pancreatitis
Case 1	14.2	1.96	12	13.5	+	-
Case 2	15.3	1.83	11	14.7	+	-
Case 3	14.1	1.89	11	-	+	+

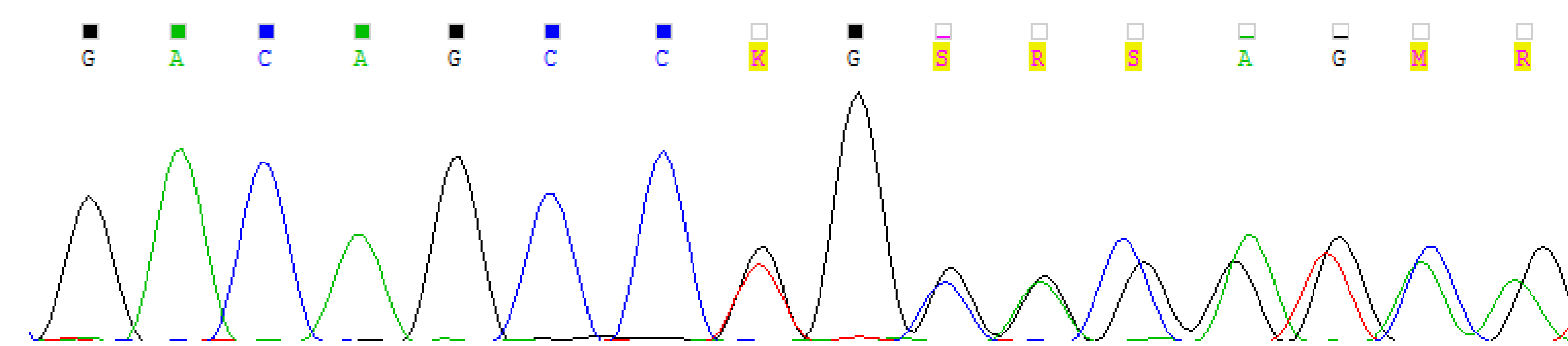
**Table 2 Laboratory data**

	HbA1c, %	HOMA -IR (<3.2)	TG mmol/L (0.1-1.7)	Cholesterol mmol/L (3.3-5.2)	AST U/L (0-34)	ALT U/L (0-55)
Case 1	6.7	25.7	3.9	7.6	51	64
Case 2	7.1	5.9	4.2	7.1	14	16
Case 3	5.4	10.8	9.8	6.5	79	141

**DNA analysis.** A novel heterozygous variant in intron 8 of *PLIN1* gene NM\_002666.4: c.1210-1delG (Fig. 2) was found in all three subjects. Sanger sequencing of cDNA showed an abnormal *PLIN1* transcript: c.1209\_1216delCTCCCCAG p.L404AfsX159 (Fig. 3), similar to those described previously in patients with the other two C-terminal *PLIN1* defects [1, 2].



**Figure 2.** Electropherogram of gDNA sequence of intron 8/exon 9 junction showing a heterozygous c.1210-1delG *PLIN1* variant.



**Figure 3.** Electropherogram of cDNA sequence (reverse strand) of *PLIN1* splicing products showing a heterozygous c.1209\_1216delCTCCCCAG variant.

**Conclusion.** The novel splicing variant is predicted to result in synthesis of an aberrant C-terminal part of *PLIN1* protein suggesting, similar to the previously reported cases of FPLD4, an existence of the uniform molecular mechanism in the development of this disorder.

#### References

- Gandotra S, Le Dour C, Bottomley W, Cervera P, Giral P, Reznik Y, Charpentier G, Auclair M, Delepine M, Barroso I, et al. Perilipin deficiency and autosomal dominant partial lipodystrophy. *N Engl J Med.* 2011;364(8):740–8.
- Kozusko K, Tsang VH, Bottomley W, Cho YH, Gandotra S, Mimmack M, Lim K, Isaac I, Patel S, Saudek V, et al. Clinical and molecular characterization of a novel *PLIN1* frameshift mutation identified in patients with familial partial lipodystrophy. *Diabetes.* 2015;64(1):299–310.

#### Financial support:

This work was supported by Alfa-Endo Program of Charities Aid Foundation (CAF) Russia.