

Pubertal induction amongst girls with Turner Syndrome:

A review of changing practice over 10 years

Hassan A Elechi¹, James Law², Joanna Benson², Tabitha Randel², Louise Denvir², Pooja Sachdev²

1. Dept of Paediatrics, University of Maiduguri, Nigeria; 2. Nottingham Children's Hospital, NUH NHS TRUST, Nottingham, United Kingdom

Background

Pubertal induction with oestrogen is an important component of care offered to patients with Turner Syndrome (TS)¹ for physical and psychological well-being.²

Oestrogen preparations and regimens vary due to lack of global consensus. In the United Kingdom, low dose oral ethinylestradiol is the most commonly used preparation.³ However, transdermal matrix 17-β oestradiol patches are increasingly used³ due to some evidence of a better outcome.⁴

In line with current recommendations,⁵ hypogonadal patients with TS in our Centre are offered a choice of preparations.

We undertook this audit to compare the efficacy and acceptability of oral ethinylestradiol and transdermal matrix 17-β oestradiol preparations at our centre over the past ten years.

Methods

A retrospective audit of the care of all girls with TS with biochemical evidence of hypergonadotrophic hypogonadism who underwent induction of puberty between 2008-2017 at Nottingham Children's Hospital, was undertaken, excluding those yet to commence progestogens (n=27).

The age at start (start of oestrogen) and end (start of progesterone) of induction was recorded along with the preparation used, pubertal staging and height SDS at the start and end of induction, and pelvic ultrasound and DEXA findings, if undertaken.

The data was analyzed using R: A Language and Environment for Statistical Computing. Data is mean±SD or frequency (%) as appropriate. Comparisons were made using Student's t-tests and Fisher's exact tests, respectively (significance level: p<0.05).

Results

Pubertal induction was started at 13.1±1.8 years and progestogen introduced at 16.1±1.9 years; duration of unopposed oestrogen action was 2.8±0.8 years. Most patients used one preparation (Fig. 1). Most frequently, patients were Tanner Stage 1 at the start or induction and 3 at the introduction of progesterone (Fig. 2).

Height SDS change during induction was 0.5±1.0. There was no significant difference between oestrogen regimens in height SDS change (oral: 0.4±1.0, patches: 0.8±1.1, p=0.4). Of the 3 additional patients with raised ALT at introduction of progesterone 2 used EE and 1 used patch (P=1.000). Results of imaging are shown in Table 1.

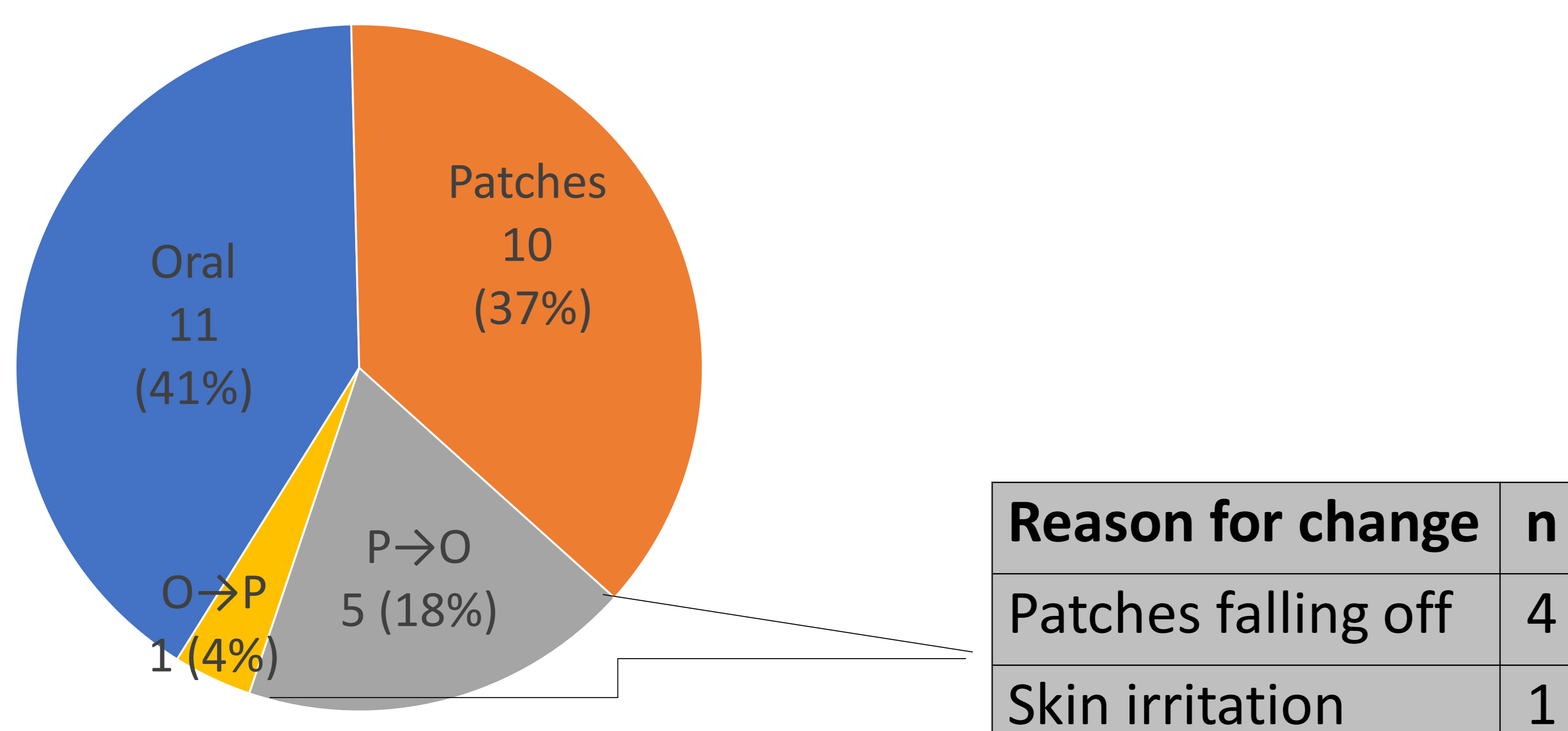


Fig. 1 Oestrogen preparation used for induction Figures are n (%). P=patch 17-β oestradiol; O=Oral ethinylestradiol

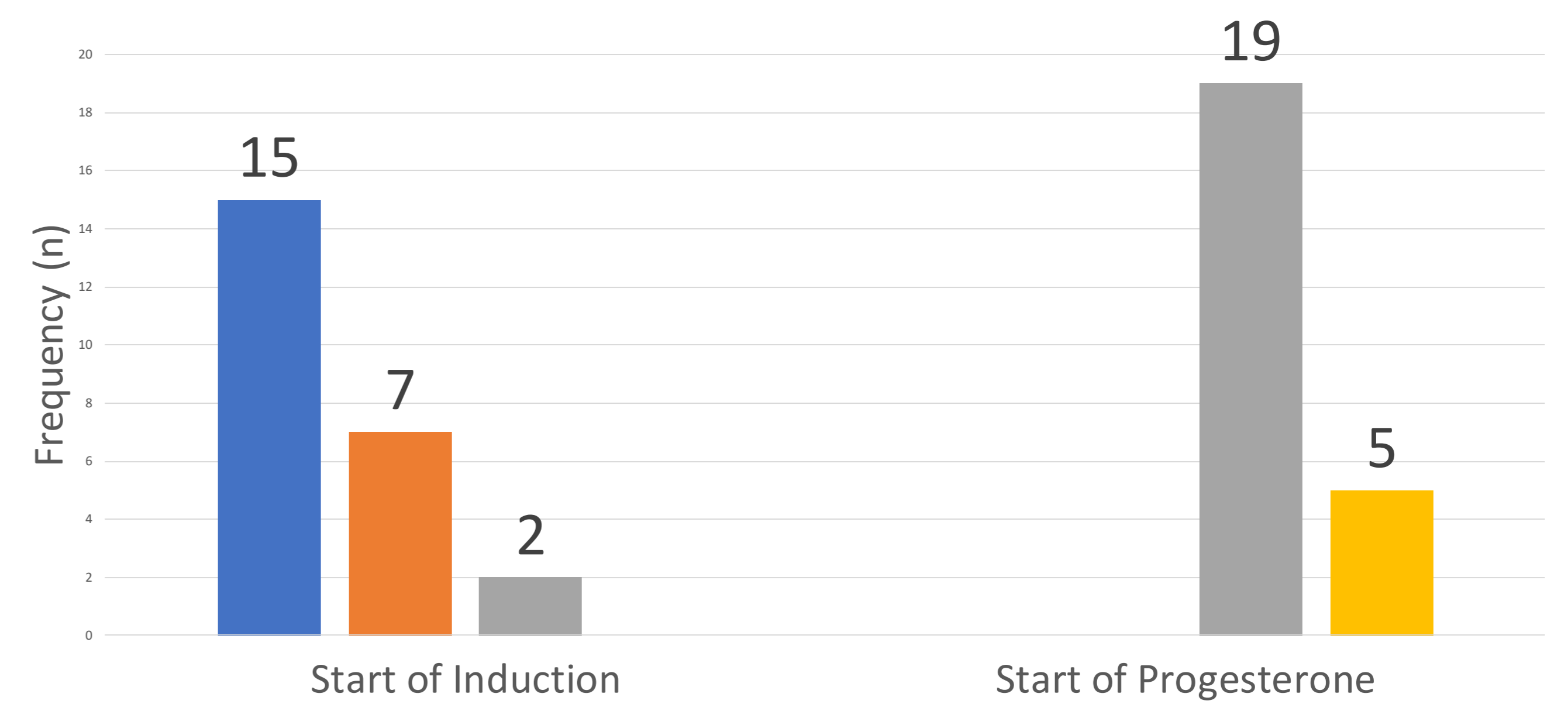


Fig. 2 Tanner stage at start of pubertal induction and commencement of progesterone. Blue: stage 1; orange: stage 2; grey: stage 3; yellow: stage 4.

Pelvic USS at start of induction: n = 9 (33.3%)

- Normal prepubertal uterus in n=8 (88.9%)
- Uterus could not be visualized in n = 1 (11.1%)
- Ovaries not seen in n = 8 (88.9%).

Pelvis USS at end of induction: n = 6 (21.4%)

- Normal sized post-pubertal uterus in n=5
- Infantile uterus in n=1.

DXA at transition: n = 17 (63.0%)

- Low bone mineral density in n=2. Both diagnosed late (13 & 16 years) with short stature and delayed puberty and used patches.

Bone mineral density was not significantly different between oestrogen regimens (p=0.5).

Table 1. Summary of imaging studies performed and findings. DXA: Dual-energy X-ray absorptiometry; USS: ultrasound scan

Conclusion

- Induction of puberty with oral or patch oestrogen appears to be equally effective in girls with Turner Syndrome.
- Patients should continue to be offered a choice of oestrogen preparations.
- Late initiation of induction, in delayed diagnosis, might result in low bone mineral accrual.

References

1. Rosenfield RL, Perovic N, Mauras N, Devine N, Moshang T, Root AW, et al. Optimizing estrogen replacement treatment in Turner's syndrome. *Pediatrics*. 1998; 102:486-8.
2. Norjavaara E, Ankarberg C, Albertsson-Wikland K. Diurnal rhythm of 17 beta-oestradiol secretion throughout pubertal development in healthy girls: evaluation by sensitive radioimmunoassay. *J Clin Endocrinol Metab*. 1996; 4095-4102.
3. Gault EJ, Donaldson MD. Oestrogen replacement in Turner syndrome: current prescribing practice in UK. *Clin Endocrinol*. 2009; 71(5):753-5.
4. Ankarberg-Lindgren C, Kriström B, Norjavaara E. Physiological estrogen replacement therapy for pubertal induction in girls: A clinical observational study. *Horm Res Paediatr*. 2014; 81:238-244.
5. Hormone supplementation for pubertal induction in girls. [online] [accessed 29th June, 2018] [24 pages]. Available from: www.bsped.org.uk/clinical-resources/guidelines