

T. Timpanaro¹; C. Bizzarri²; A. Sauna¹; M. Caruso-Nicoletti¹

¹Centro Di Endocrinologia e Diabetologia Pediatrica; AOU Policlinico-Vittorio Emanuele, Catania, Italy

²DPUO, OBG Roma Italy

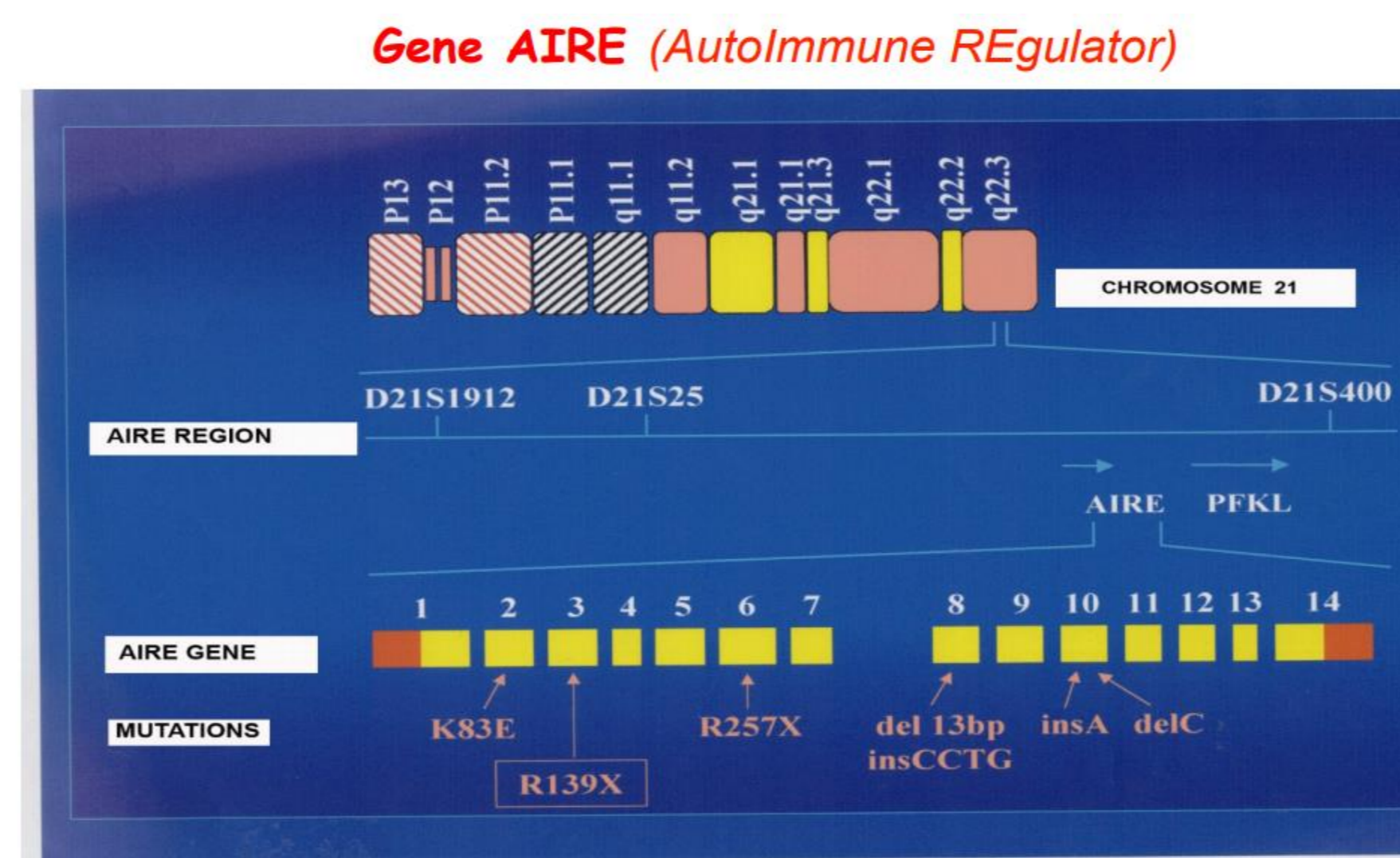
Autoimmune polyglandular syndrome type 1 (APS-1) is also known as autoimmune polyendocrinopathy-candidiasis-ectodermal dystrophy (APECED). Clinical manifestations are widely variable.

It is an autoimmune disease which is characterized by a triad of:

- hypoparathyroidism
- Addison disease
- Chronic mucocutaneous candidiasis.

However, several other manifestations may be present, non-endocrine autoimmune diseases, differing in number and severity in each patient, which are factors that contribute to be later diagnosis.

APS1 is mostly caused by mutations in the autoimmune regulator (AIRE) gene located on chromosome 21q22.

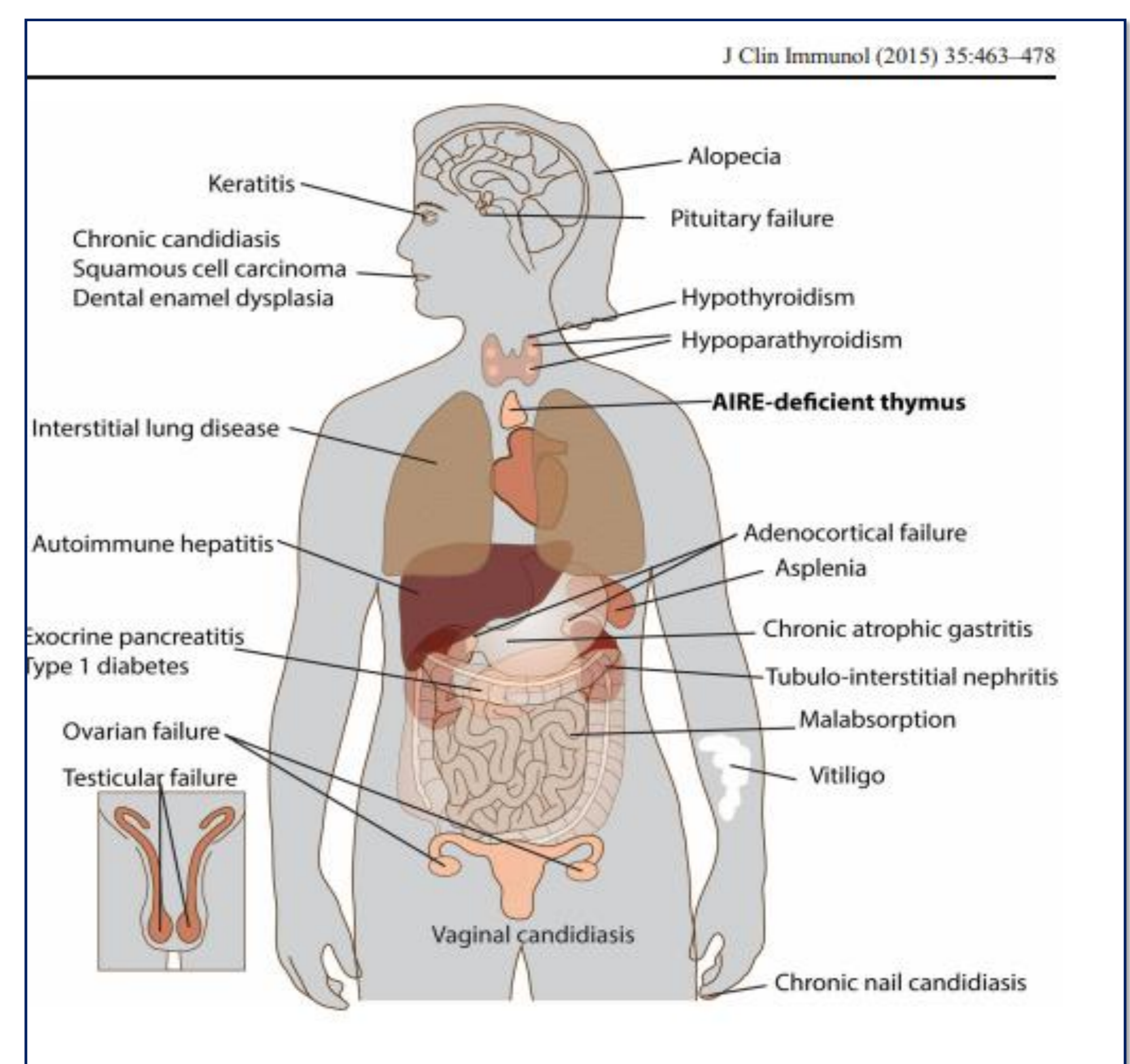


Localizzato a livello 21q22.3. Il gene è stato mappato nel 1994 e sequenziato nel 1997 da Nagamine et al (Nat Genet) – formato da 14 esoni e codifica per la proteina omonima.

We present the case of two brothers diagnosed with APS-1, both the molecular analysis revealed a compound heterozygosity for the AIRE gene c. 415C>T; 967-979 del p r139* L323Sfs* 51

- **The older brother** was diagnosed at 11 years old after presenting with **psoriasis**, recurrent mucosal and cutaneous **candidiasis** since infancy, **adrenal insufficiency and hypoparathyroidism**. In therapy with rGH for **pituitary hypoplasia**.
- **The younger brother** presented oral fungal infections and **onychomycosis** since the very first months of life. At 8 years old he showed chronic abdominal pain that led to finding hypertransaminasemia. Workup for hepatitis A, B, C, and Epstein–Barr viruses had yielded no signs of active infection. Anti-gliadin and anti-tissue transglutaminase IgA as well as anti-kidney-liver microsomal and anti-smooth muscle antibodies had been negative. A liver biopsy demonstrated brisk lymphohistiocytic infiltrate in the portal tracts with moderate interface hepatitis. He received therapy for autoimmune hepatitis with oral prednisone.

Disease component	Prevalence (%)
Endocrine components	
Hypoparathyroidism	85
Adrenal failure	72
Ovarian failure	60
Insulin-dependent diabetes mellitus	18
Testicular atrophy	14
Parietal cell atrophy	13
Hypothyroidism	6
Non-endocrine components	
Candidiasis	100
Enamel hypoplasia	77
Nail dystrophy	52
Tympanic membrane calcification	33
Alopecia	27
Keratopathy	22
Vitiligo	13
Hepatitis	13
Intestinal malabsorption	10



Autoimmune hepatitis is present in 13- 20% of patients with APS-1. It does not appear after the age of 20 years. It characteristically presents with elevated levels of AST and ALT. Its spectrum ranges from an asymptomatic self-limited to a fulminant disease with lethal outcome. Fulminant hepatitis may develop without prewarning signs Treatment involves immunosuppression with the use of glucocorticoids In according with literature, in this case the clinical APS1 presentation is extremely variable, including different manifestations, some of which rarely reported, and CMC was present in all of them.