



Background

Craniopharyngioma is a tumor of low histological malignancy. Affected children and adolescents are being studied with respect to their quality of life (QoL), PFS, and overall survival in the framework of the ongoing KRANIOPHARYNGEOM 2007 project.

Patients and methods

This study consists of a randomized trial with an adaptive design combined with a purely observational study. The randomized, unblinded trial includes pts. whose tumors have been incompletely resected and is intended to compare the outcomes of immediate postOP radiotherapy versus radiotherapy on progression. Its primary endpoint is QoL as assessed subjectively by the pts. themselves with the PEDQOL questionnaire. In exploratory analyses, linear mixed models were used to study the effect of further factors on QoL.

Results of linear mixed models for QoL

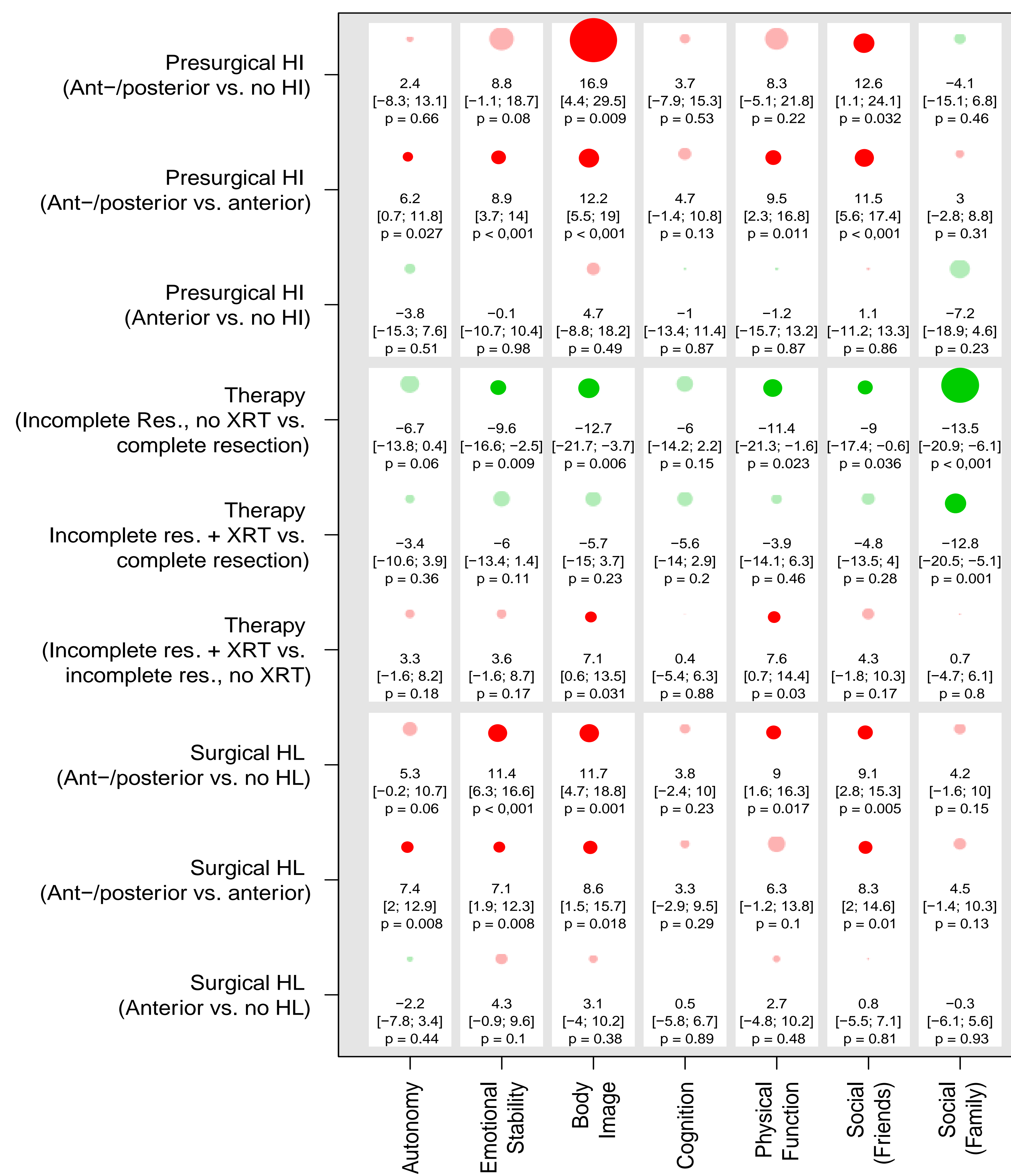


Figure 2: PEDQOL was modeled for 131 pts. separately in each domain as a function of time, the factor in question, and the interaction between time and the factor in question. The results are displayed as differences of least-square estimates, with the associated 95%-confidence intervals and p-values, describing the mean difference in PEDQOL scores between the two categories of each factor. The size of the circles is proportional to the mean difference; circles representing positive and negative effects on QoL are colored green and red, respectively (opaque when $p \leq 0.05$). A box corresponds to the results of a model. The higher the PEDQOL score, the lower the subjective QoL; a minus sign thus indicates a beneficial influence on QoL. HD, hypothalamic damage; HI, hypothalamic involvement.

Supported by Deutsche Kinderkrebsstiftung

Grading of hypothalamic lesions

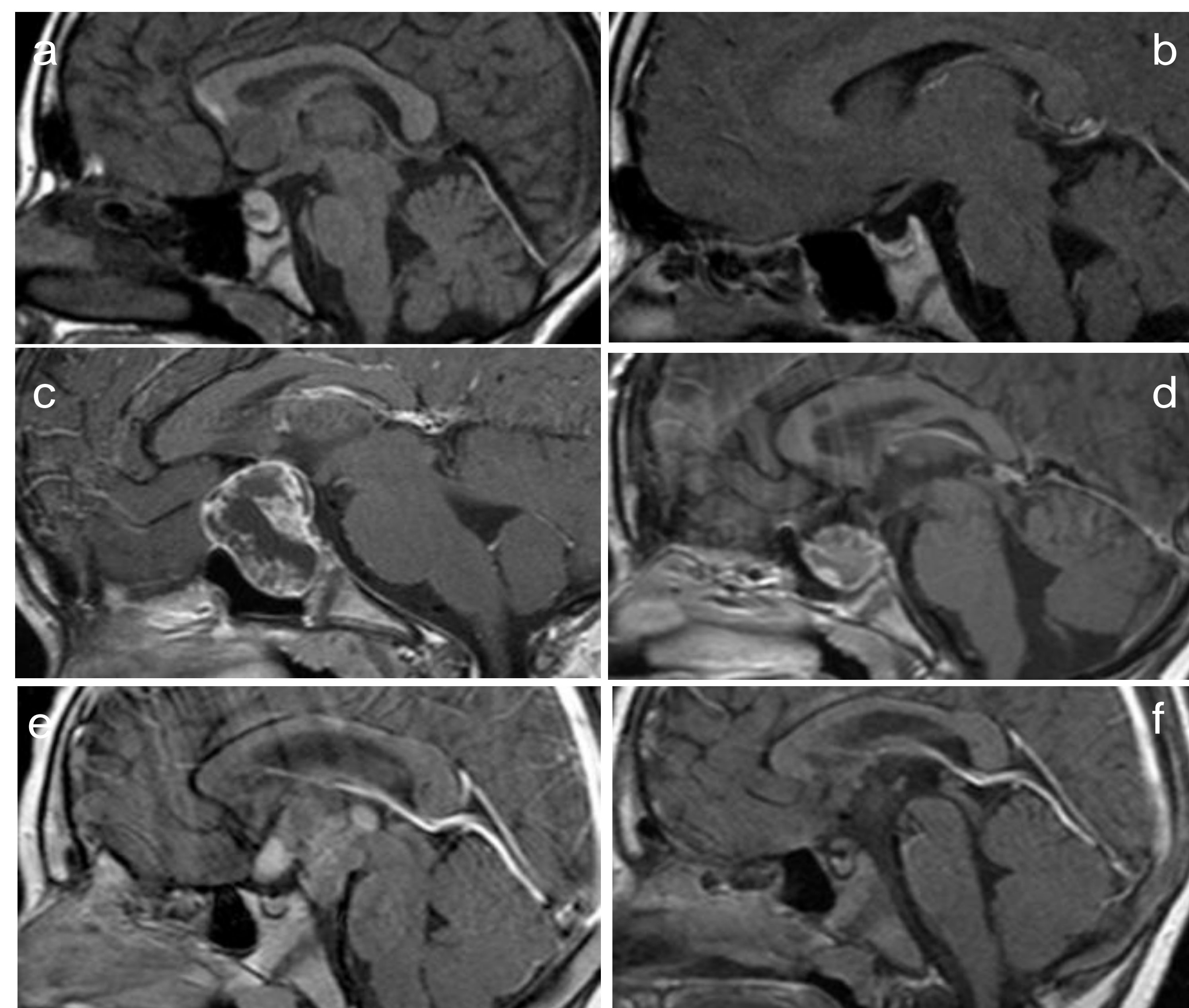


Figure 1: MRI at diagnosis and 36 months postOP in 3 CP with different degrees of preOP hypothalamic involvement (HI) and operative hypothalamic damage (HD). Figures 1a, b: sellar tumor (no HI [a]/no operative HD [b]) Figures 1c, d: preOP HI (c) and operative HD (d) of the anterior hypothalamus (not including the mammillary bodies). Figures 1e, f: preOP HI (e) und operative HD (f) of anterior+posterior hypothalamus areas (including the mammillary bodies).

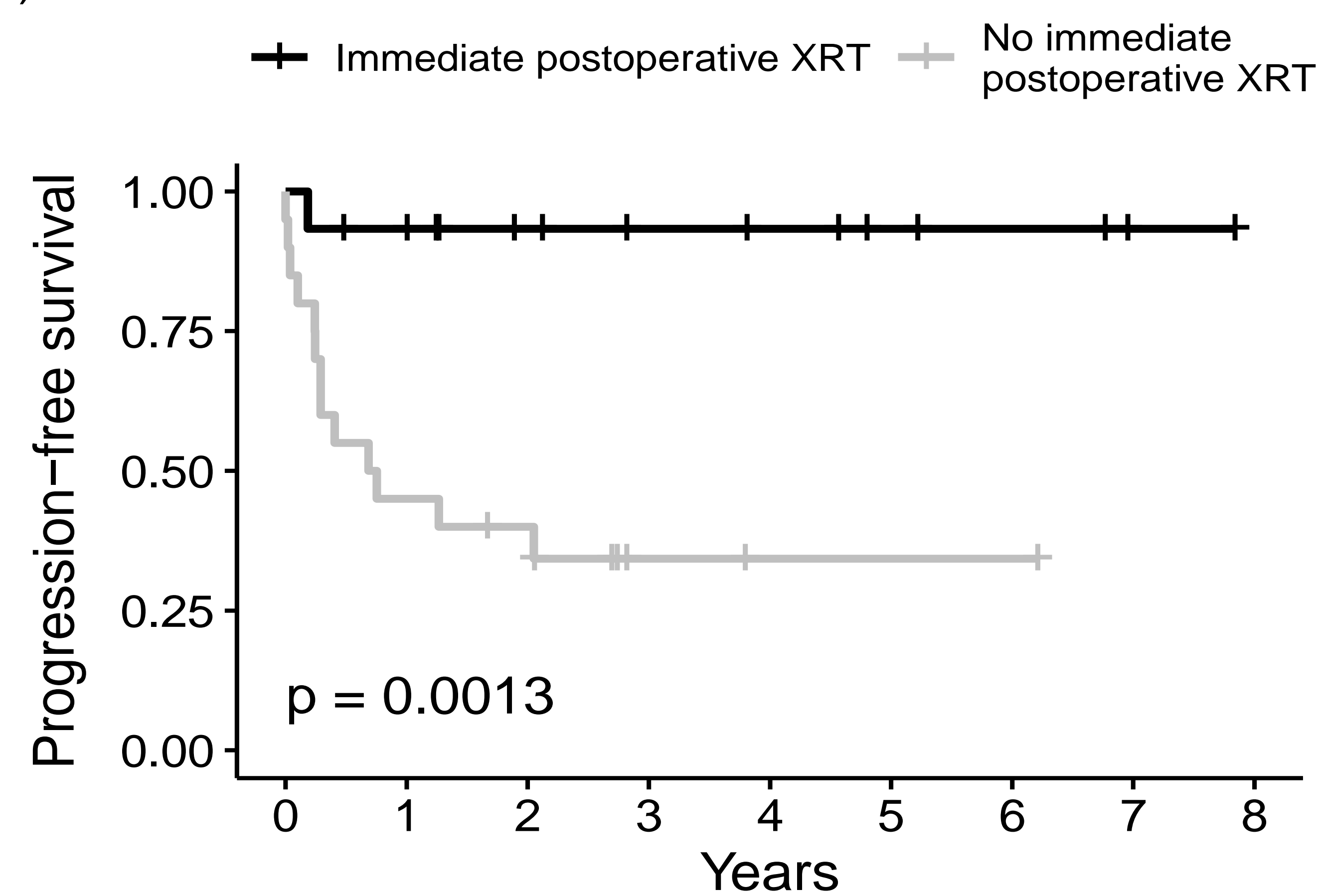


Figure 3: Kaplan-Meier estimate of progression-free survival $p=0.0013$ (log-rank test). XRT, radiotherapy

Results

An interim intention-to-treat analysis of the randomized trial revealed only minor differences between the treatment arms with respect to QoL ($n=24$). The exploratory analyses ($n=131$) showed that pre-operative involvement of, or operative damage to, the anterior and posterior regions of the hypothalamus was associated with a lower QoL. Complete resection was followed by a lower QoL than incomplete resection. Radiotherapy, a common treatment for tumors that progress after incomplete resection, was also associated with a lower QoL.

Conclusions

Hypothalamus-sparing treatment approaches are recommended to optimize the quality of life of children and adolescents with craniopharyngioma. The available evidence does not support any recommendation as to when radiotherapy should be performed after incomplete resection so that the best QoL can be achieved.

