

Long-term urological and psychosexual outcome of men born with hypospadias

L. Tack, E. Van Hoecke, A Springer, S. Riedl, U. Tonnhofer, J. Weninger, M. Hiess, E. Van Laecke, P. Hoebeke, AF Spinoit and M. Cools



Key messages

- Few patients regret childhood hypospadias surgery
- Postpubertal revision is warranted, due to long-term complications
- Aesthetic outcome is rated differently by patients and physician, so should always reflect both aspects

INTRODUCTION

According to EAU's guidelines, hypospadias repair is best performed between 6 and 18 months of age. However, childhood genital surgery is becoming increasingly controversial. Yet, little is known about the long-term patient satisfaction or urological outcome following hypospadias surgery.

AIMS

To examine the psychosexual and urological outcome of young adult men (16-21 years old) born with all forms of non-syndromic hypospadias as compared to healthy controls, as well as patient and parental satisfaction following hypospadias surgery.

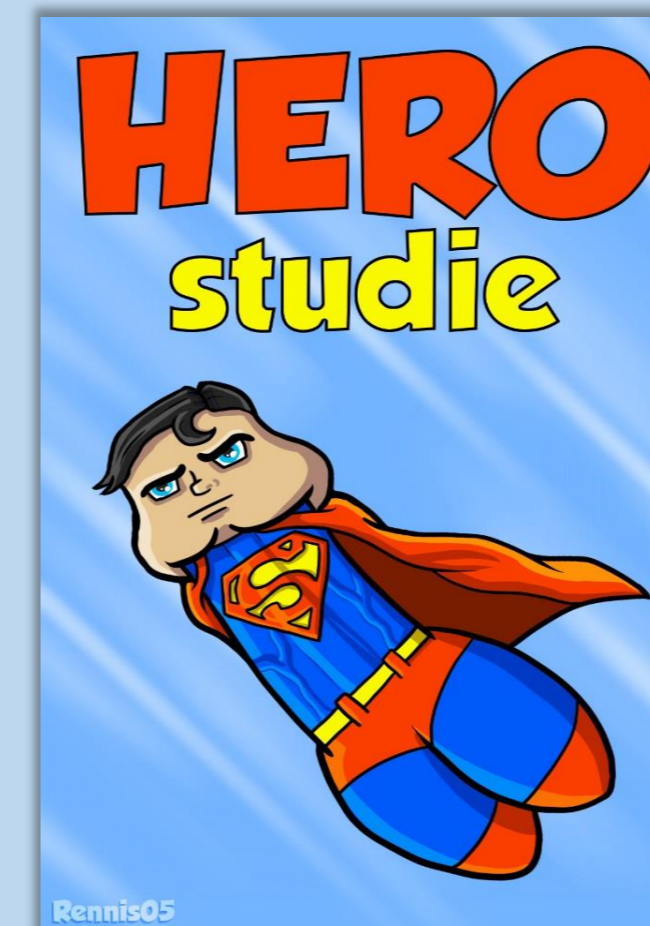
METHODOLOGY

Design: Cross-sectional assessment

Centers: Ghent University Hospital and Vienna Medical University

Psychosexual: Participants: the Decision Regret Scale (DRS), Penile Perception Score, Sexual Quality of Life – Male, International Index of Erectile Function and a custom-made questionnaire. **Parents:** The DRS and custom-made questionnaire; **Urological:** uroflow, postmictional and testicular ultrasound and genital examination (HOPE score)

Statistics: IBM SPSS® 25.0: Pearson correlation, unpaired student t-test, Mann Whitney-U test or chi-square test, as appropriate



PARTICIPANTS

Hypospadias	N= 192
Distal	132/192 (68,8%)
Midshaft	37/192 (19,3%)
Proximal	23/192 (12,0%)
Complex	20/192 (10,4%)
Controls	N=50

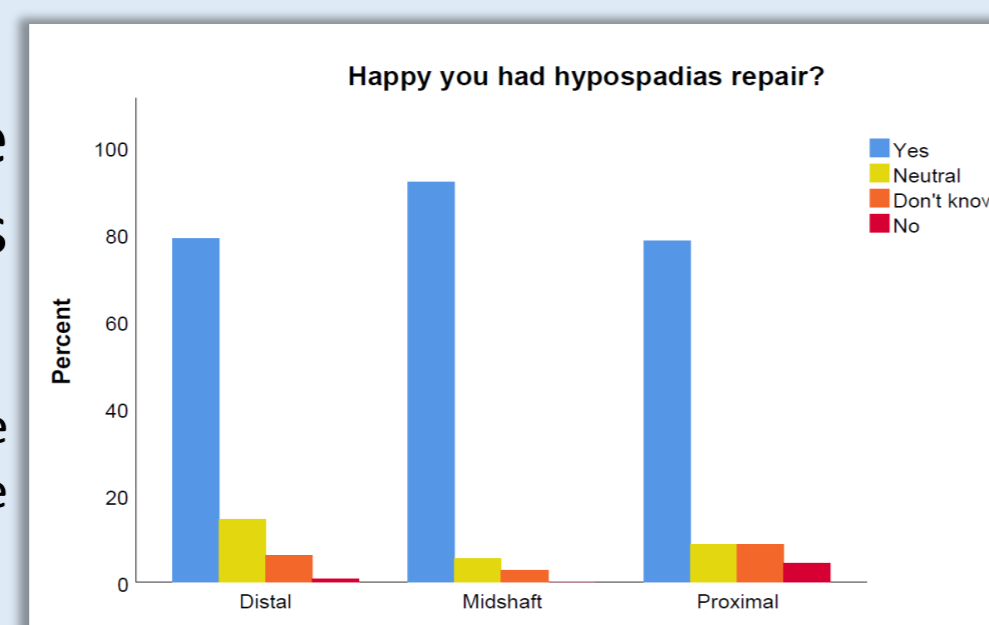
RESULTS

Hypospadias repair

Childhood repair:

- All but one midshaft case find it normal that parents decide

Figure: Distribution of answers on the question 'Are you happy you had the hypospadias repair?'



Regret:

DRS correlations	Cases		Parents	
	ρ	P	ρ	P
DRS parents	0,357	<0,001	NA	NA
Number of surgeries	0,189	0,012	0,282	<0,001
Stretched penile length	-0,169	0,049	-0,097	0,269
PPS: penile appearance	0,263	<0,001	0,206	0,007
IIEF-5	-0,165	0,123	NA	NA
SQoL-M	-0,423	<0,001	NA	NA

Worries:

- Parents: 95/189 (50,3%) worry about their son's fertility, sexual experience and/or puberty / maculinity
 - Complex: 13/19 (68,4%)
 - Proximal: 17/23 (73,9%)

Cases	Fertility	Hormones	Puberty
Total	50/192 (26%)	15/192 (7,8%)	7/192 (3,6%)
Complex hypospadias	10/20 (50%)	2/20 (10%)	2/20 (10%)
Proximal hypospadias	10/23 (43,5%)	4/23 (17,4%)	4/23 (17,4%)

Psychosexual

Mocked:

- 50/192 cases (26%) fear being mocked when naked
 - 19 (9,9%) have been mocked
- Higher in proximal and complex hypospadias:
 - Fear: 12/23 (52,2%) and 12/20 (60%), respectively
 - Mocked: 4/23 (17,4%) and 4/20 (20%), respectively

IIEF-5:

- No difference in IIEF-5 score was found between cases and controls, nor between controls and proximal or complex hypospadias (NS)

Cases	Cases	Proximal	Complex	Controls
Mild erectile dysfunction	5/84 (6,0%)	1/8 (12,5%)	1/8 (12,5%)	0/38 (0%)

SQoL-M:

- No difference case/control & complex (NS)
- Proximal hypospadias cases had significantly lower scores as compared to distal hypospadias (p=0,023) and non-significantly lower than controls (p=0,051)

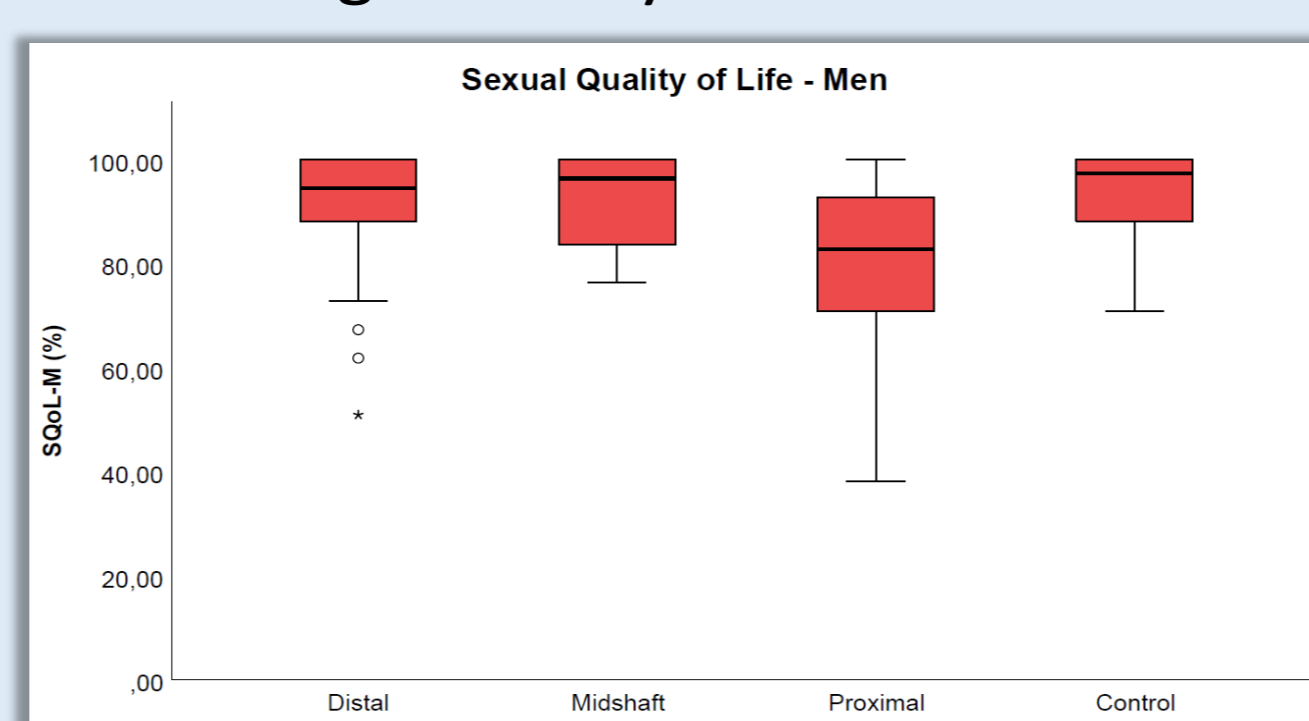

Figure: SQoL-M total score.

Urological outcome

Suboptimal penile appearance	PPS	HOPE
Hypospadias	25/192 (13%)	41/192 (21,4%)
Distal	16/132 (12,1%)	18/132 (13,6%)
Midshaft	3/37 (8,1%)	8/37 (21,6%)
Proximal	6/23 (26,1%)	15/23 (65,2%)
Complex	3/20 (15%)	11/20 (55%)

Testicular microcalcifications:

- Hypospadias: 13/191 (6,8%)
- No difference: Controls (6%); Severity of hypospadias (NS)

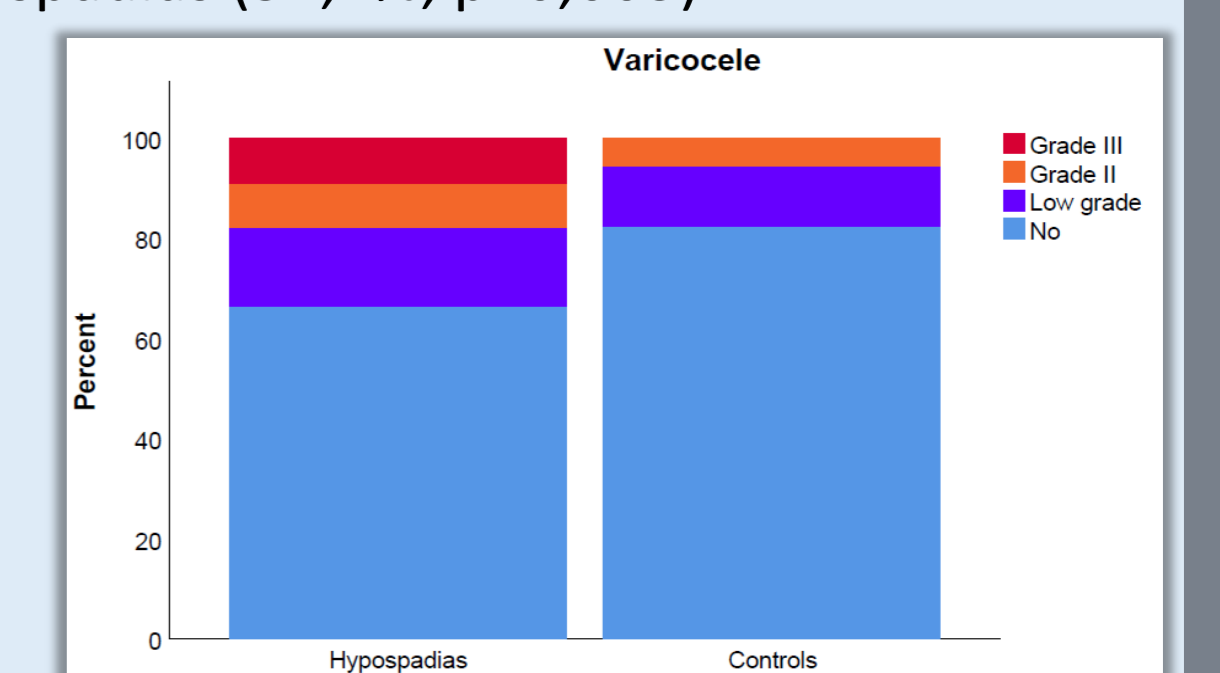
Uroflow:

- Abnormal: 36/192 (18,8%)
- No difference: Severity of hypospadias (NS)
- Only 5 with residue (no proximal cases)

Genital exam:

- Fistulae: 11/192 (5,7%)
 - No difference severity hypospadias (NS)
- Residual hypospadias: 47/192 (24,5%)
 - More in proximal hypospadias (52,2%, p=0,003)

Figure: prevalence of varicocele. Low grade: grade I (palpable during valsalva) or subclinical varicocele. Grade II: palpable without valsalva. Grade III: visible.



CONCLUSIONS

Very few patients regret having had hypospadias surgery in childhood. Patients and physicians value outcome of hypospadias surgery according to different criteria. We found a high rate of varicocele post hypospadias surgery of unclear origin so far. Our data highlight the need for postpubertal revision of hypospadias cases as long-term complications may occur that require surgical intervention at some times. In some cases, psychosexual counseling may be recommended.

Funding

