



# A rare case of neonatal hypocalciuric hypercalcemia complicated by cardiac arrhythmia

Yuto Arai, Ryo Okumura, Soichiro Wada, Keiji Haseyama, Shuji Sai  
Teine Keijinkai Hospital, Sapporo, Japan

## Introduction

Familial hypocalciuric hypercalcemia is a rare, lifelong, and usually benign hereditary disorder which is usually asymptomatic. Here we present a rare case of neonatal hypocalciuric hypercalcemia complicated by cardiac arrhythmia.

## Patients

### History of presenting illness

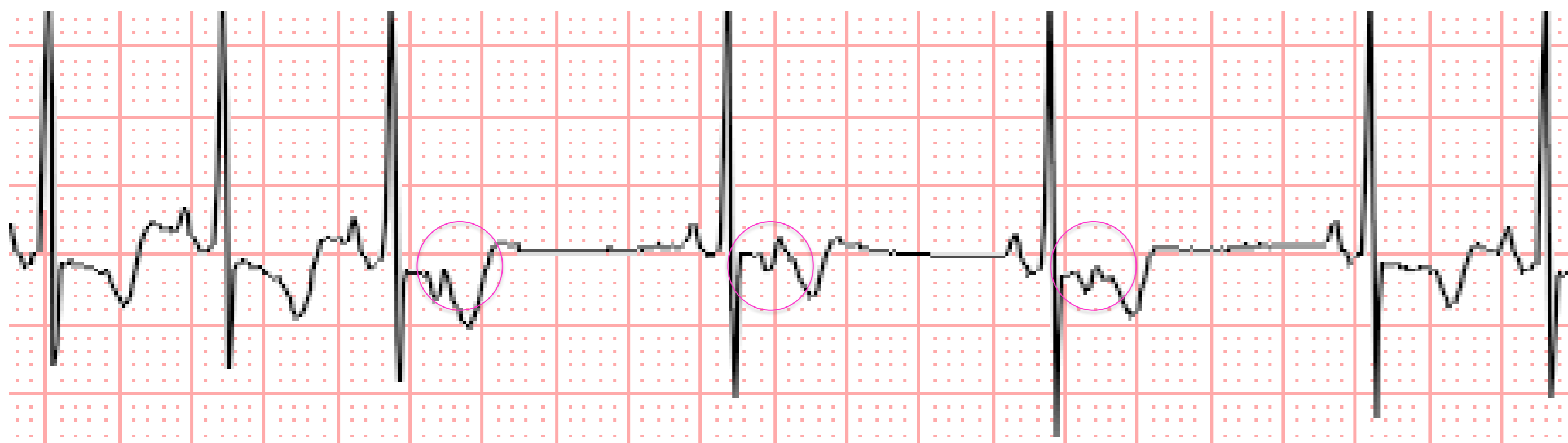
A healthy male infant weighing 2636g was delivered by spontaneous vaginal delivery at term. The pregnancy had progressed normally, but neonatal arrhythmia was found by physical examination after birth. Electrocardiography demonstrated isolated premature atrial ectopics. The baby was otherwise well and was discharged on day 6 with outpatient follow-up. On day 10, he represented with fever and hypercalcemia was coincidentally discovered. Further investigation was subsequently carried out. There was no family history of hypercalcemia.

### Physical Examination

The only abnormal finding was an irregular pulse. BW:2.6 kg. BT 37.2, HR 80-140 bpm, RR 30, SpO2 98%(RA)

## Imaging study

### ECG



### Premature atrial contractions (PAC) with block

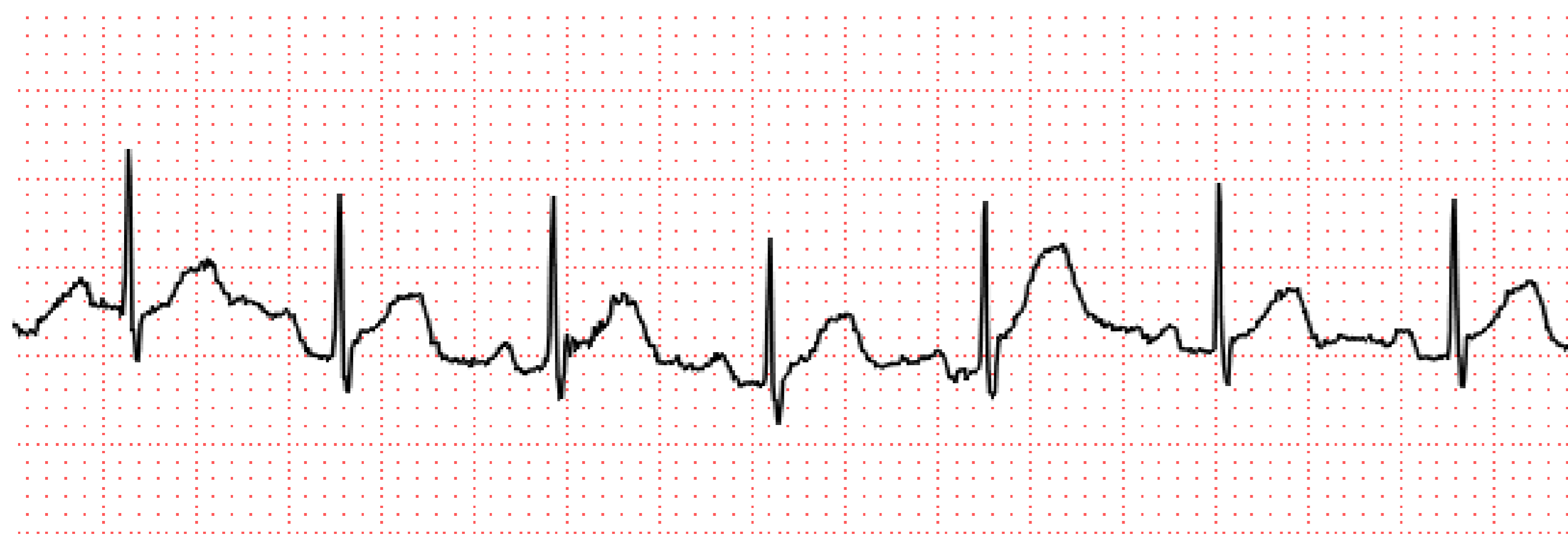QTc (Bazett) 0.42 s (normal range; 0.35-0.44 s)

X-ray of distal ulna No signs of impaired mineralization

Ultrasound No hyperplasia of parathyroid gland

## Clinical course

### ECG following Vit D supplementation



- He was diagnosed with hypocalciuric hypercalcemia on the basis of clinical and laboratory findings.
- The arrhythmia did not worsen until day 30 and the total calcium level remained stable.
- Vitamin D supplementation was prescribed on day 30 because he suffered from vitamin D deficiency (persistent high levels of ALP and PTH), which was also diagnosed with her mother after his admission.
- The arrhythmia gradually disappeared corresponding to decline in ALP and PTH levels following treatment.

## Discussion

- Hypocalciuric hypercalcemia itself rarely causes arrhythmia without shortening of QT interval. However, high levels of PTH concomitant with vitamin D deficiency could induce premature atrial contraction as seen in this case.
- PTH is reported to exert a direct action on cardiac myocytes and influence cardiac contractility linked to arrhythmia. **Furthermore, previous literatures showed hypercalcemia in patients with primary hyperparathyroidism increased the occurrence of arrhythmia such as premature atrial contraction, which often disappeared following parathyroidectomy.**
- Therefore, it is possible that normalization of PTH levels by vitamin D blunted susceptibility to arrhythmia.

## Conclusion

- Clinicians should consider electrolyte abnormalities including parathyroid hormone which regulates calcium homeostasis in the differential diagnosis of neonatal arrhythmia.

## Laboratory data

Blood test	Serum measurement	Normal range
Ca	3.06 mmol/L	2.10-2.50 mmol/L
iCa	1.64 mmol/L	1.22-1.32 mmol/L
P	1.39 mmol/dL	0.70-1.40 mmol/L
ALP	1868 U/L	500-1600 U/L
PTH-intact	89 pg/mL	10-65 pg/mL
25-OH VitD	<4 ng/mL	10-30 ng/mL

Urine test 24-hour Fraction excretion of Ca 0.97 %  
(Diagnostic criteria for hypocalciuric hypercalcemia is less than 1%)

## Course of laboratory data

	Day 10	Day 30	Day 60	Day 120
Ca	3.06	2.91	3.17	3.24
ALP	1863	2852	2285	1496
PTH-intact	89	85	53	32

Vit D

