



Background

- FHHNC is an autosomal recessive disorder, caused by mutations in either claudin 19 or claudin 16.
- A rare disorder of magnesium (Mg) metabolism with fewer than 400 reported cases throughout the literature. Somewhat underdiagnosed disorder, not being commonly observed.

Case presentation

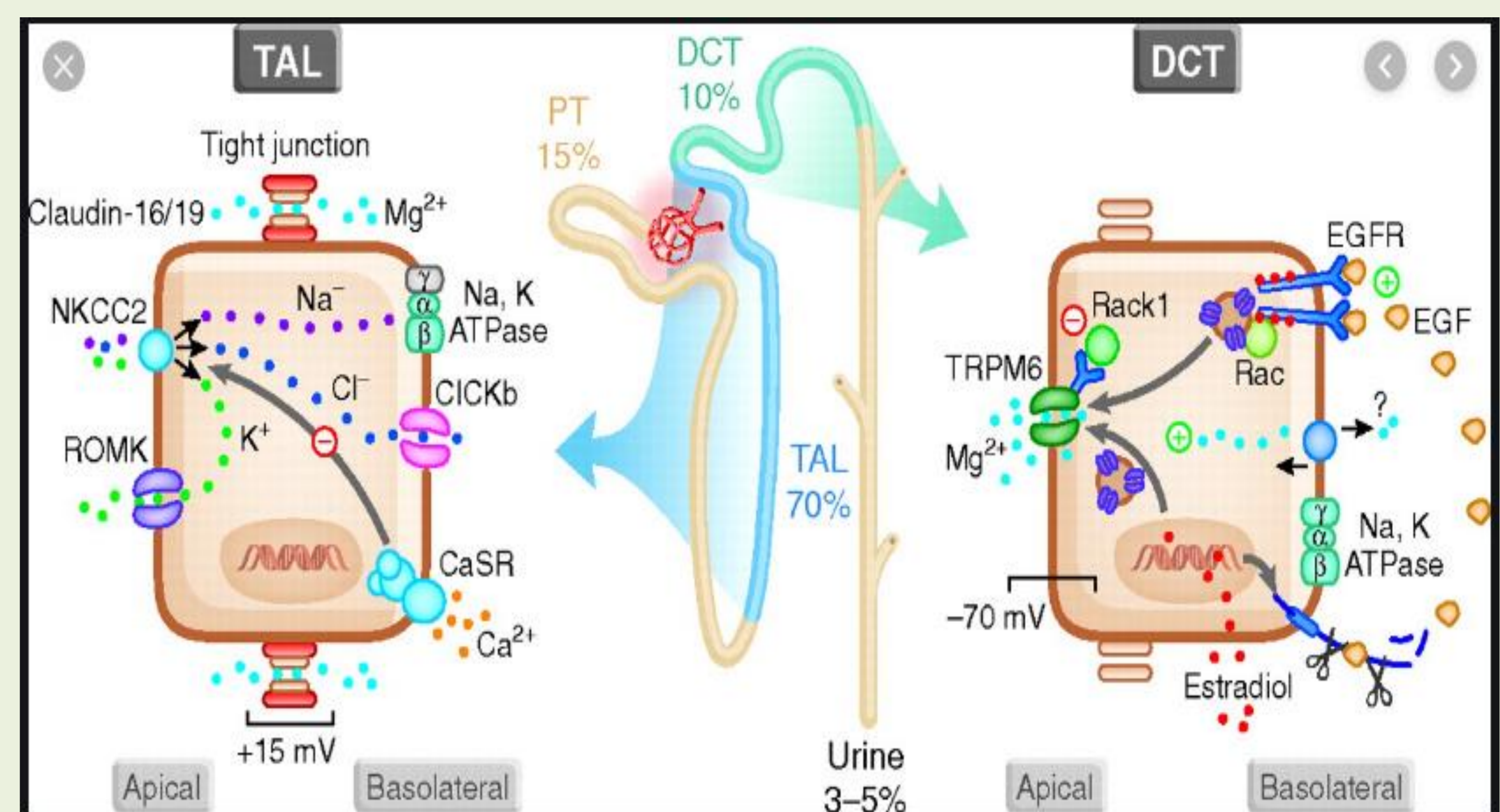
- 2 years old female who was incidentally noted to have nephrocalcinosis as part of evaluation for urinary tract infection.
- Initial workup by renal service revealed elevated PTH, hence prompting a referral to endocrine.
- Labs: 25-OH vitamin D 37ng/ml, 1,25-OH vitamin D 57ng/ml, Alkaline phosphatase 215 U/L, PTH 128 pg/ml, Calcium (Ca) 10.2 mg/dL, Phosphorus 4.3mg/dL, Mg 1.6mg/dL. Urine Ca/Cr 0.6.
- PTH level remained elevated for her Ca level on multiple repeats. A Parathyroid scan did not reveal any adenoma or nodule. On one of follow-up labs, hypomagnesemia (1.4mg/dL) was noted.
- At age 4, she started to have vision problem. An ophthalmology evaluation showed macular scarring. At this time, a suspicion of FHHNC was raised and genetic testing confirmed a C59G mutation in CLDN 19.
- Patient has been on thiazide to decrease Ca excretion and also on Mg supplement.

Discussion

- CLDN16 and CLDN19 encode the tight-junction (TJ) proteins claudin-16 and claudin-19, respectively, which are expressed in the thick ascending limb of Henle's loop and form an essential complex for the paracellular reabsorption of Mg and Ca.
- Claudin-19 is also expressed in retinal epithelium and peripheral neurons. Defects in CLDN19 are the cause of hypomagnesemia renal with ocular involvement.
- Clinical traits of FHHNC usually occurs early in childhood or before adolescence.
- Patients usually present with recurrent urinary tract infections, nephrolithiasis, polyuria, polydipsia and/or failure to thrive.
- Characterized by primary renal magnesium wasting with hypomagnesemia, hypercalciuria and nephrocalcinosis. Elevated PTH levels observed in FHHNC patients contrast with the normal or reduced PTH levels associated with hypomagnesaemia.

Characteristics of FHHNC and other inherited types of renal hypomagnesemia

Disease	Mutated gene (protein)	Pattern of inheritance	Serum Mg	Urine Mg	Serum Ca	Urine Ca	Renal failure	Other symptoms
FHHNC type 1	CLDN16 (claudin-16)	AR	low	high	-	high	+	nephrocalcinosis
FHHNC type 2	CLDN19 (claudin-19)	AR	low	high	-	high	+	Nephrocalcinosis Severe ocular defects
Gitelman syndrome	SLC12A3 (NCC)	AR	low	high	-	high	-	Muscle weakness, tetany, hypokalemia
Hypomagnesemia with secondary hypocalcemia	TRPM6 (TRPM6)	AR	low	high	low	-	-	Tetanus, muscle spasms, mental retardation
Isolated dominant hypomagnesemia	FXR2 (Na/K ATPase r subunit)	AD	low	high	-	Low	-	Convulsions
Isolated recessive hypomagnesemia	EGF (EGF)	AR	low	high	-	-	-	Tetanus, mental retardation



Conclusion

- FHHNC is a rare disorder of Mg metabolism and often underdiagnosed. In particular, Mg levels are often not checked and there is a spectrum of FHHNC in which the Mg could be normal.
- FHHNC is a progressive disease in both renal and eyes however, the clinical course is not completely clear.
- No known cure, and treatment is largely supportive with thiazide diuretics and Mg supplementation, although whether this helps to slow the rate of progression to end-stage renal disease is not clear at present.
- Multidisciplinary approach is helpful in monitoring and management of this disease.

Reference:

- "Familial hypomagnesaemia with hypercalciuria and nephrocalcinosis: clinical and molecular characteristics. Clinical Kidney Journal, 2015, vol. 8, no. 6, 656-664

