

# Thiamine responsive megaloblastic anemia syndrome with restrictive cardiomyopathy : a case report



Wafaa Laimon

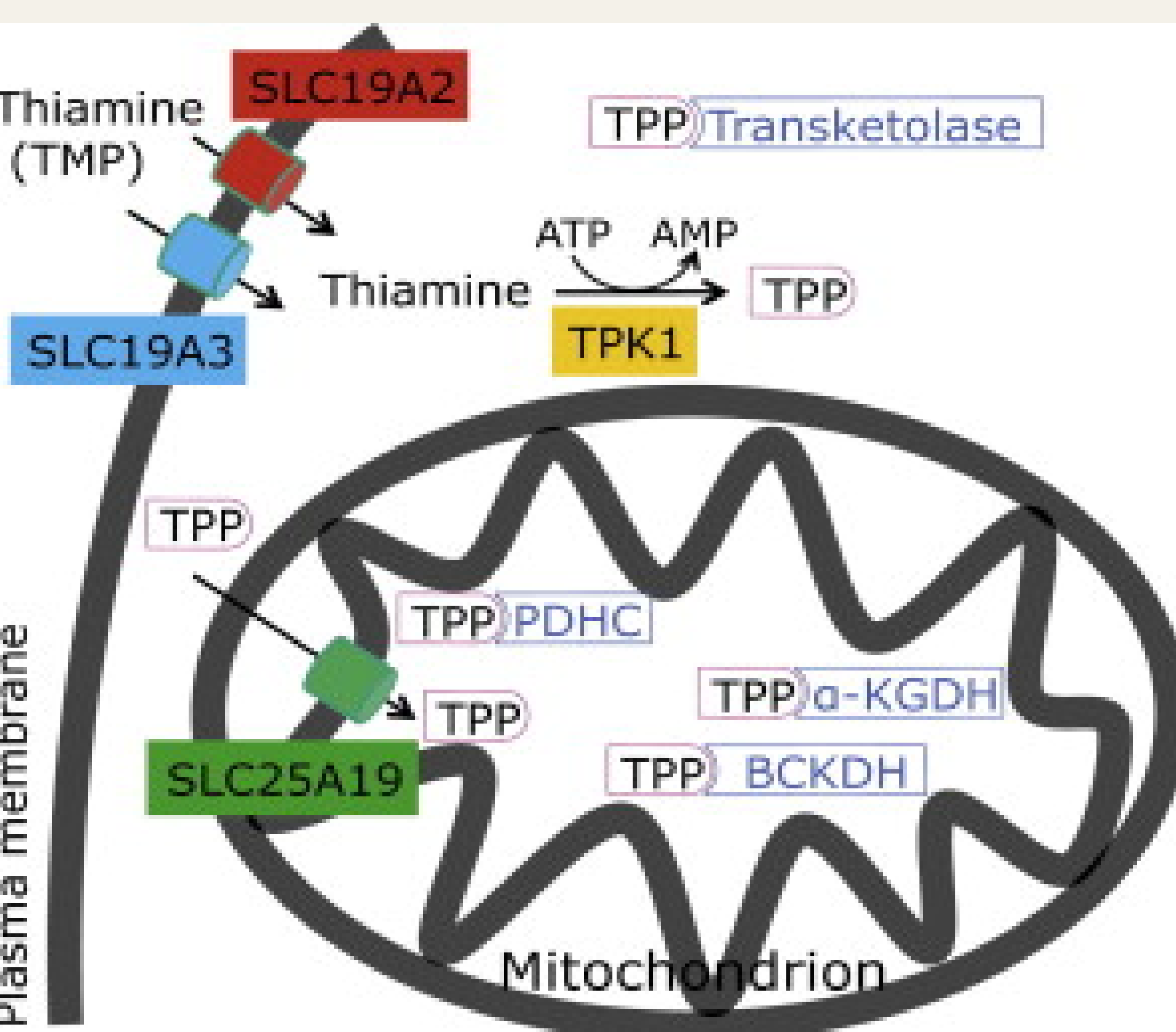
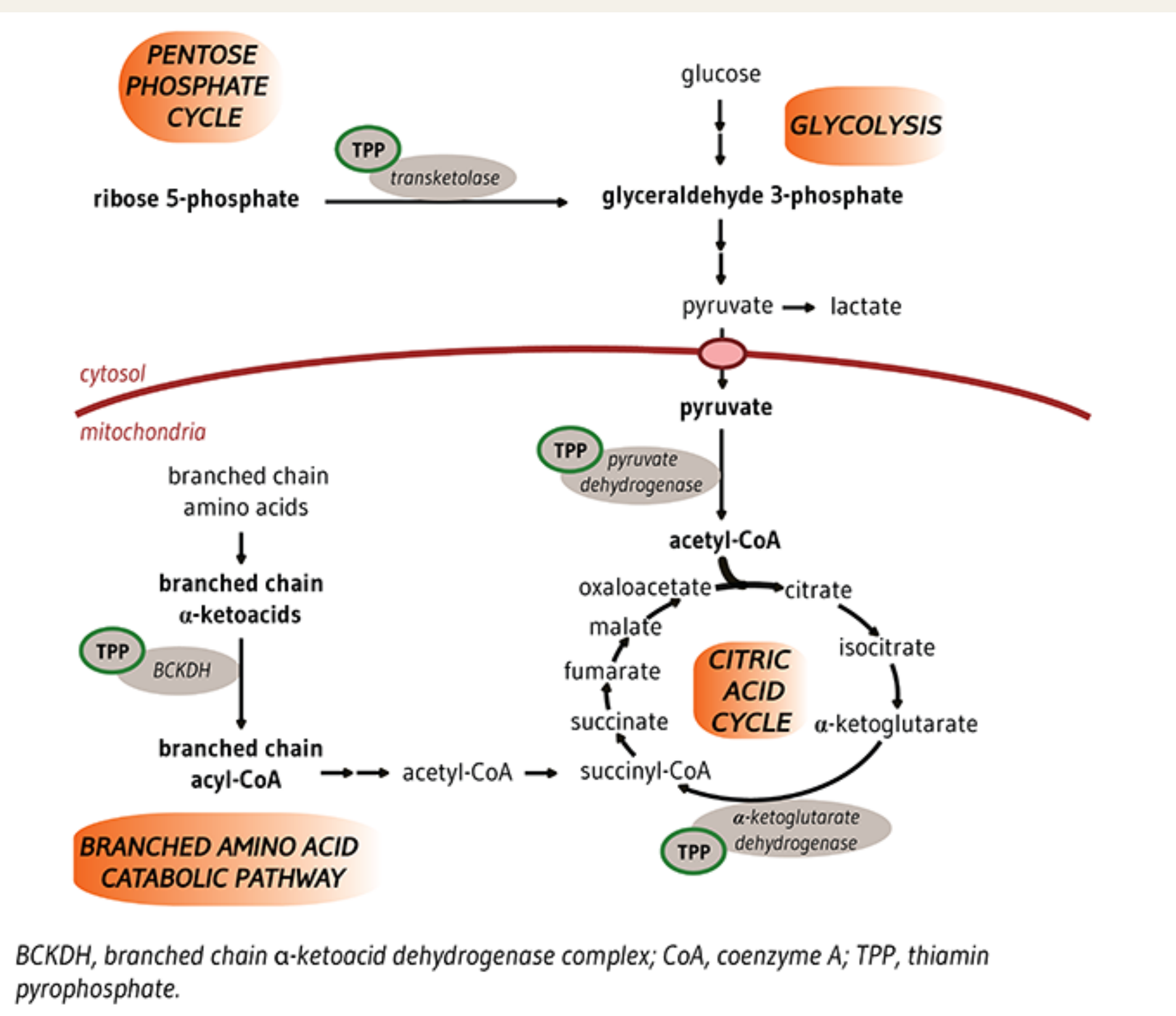
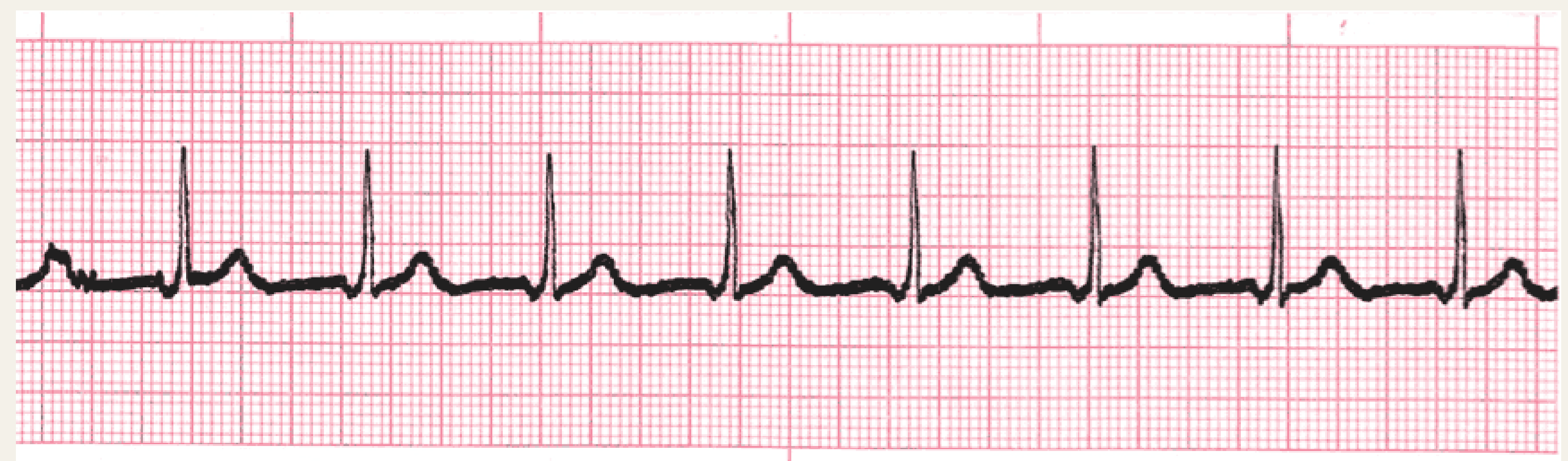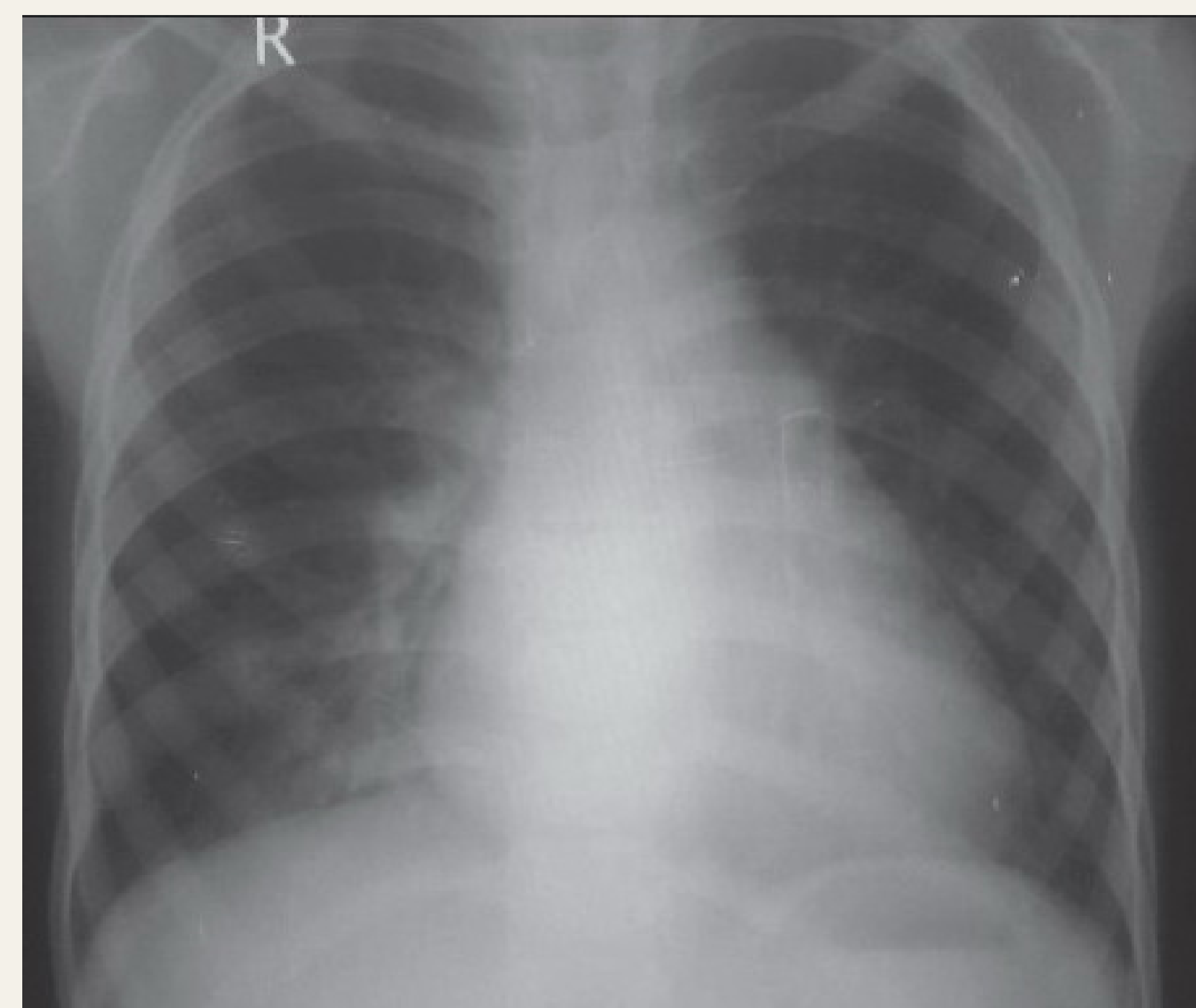
Pediatric Endocrinology and Diabetes Unit, Faculty of Medicine, Mansoura University, Egypt

## Background

Thiamine-responsive megaloblastic anemia (TRMA) is a very rare autosomal recessive disorder in which patients suffer from megaloblastic anemia, diabetes mellitus and hearing loss. Other symptoms include pancytopenia, optic nerve and retinal abnormalities, cardiac abnormalities, epilepsy, and stroke-like episodes. TRMA is caused by mutations in the SLC19A2 gene which encodes for a plasma membrane thiamine transporter protein (THTR-1). This mutation leads to reduced intracellular thiamine with subsequent apoptosis of cochlear inner hair cells, pancreatic islets cells and erythropoietic precursor cells. (1) TRMA has been reported in less than 80 cases worldwide. (2) This is the first reported Egyptian case to have TRMA with cardiac rhythm abnormality and restrictive cardiomyopathy.

## Case presentation

The patient is an 8 years old boy, product of consanguineous marriage. At the age of 6 months, he was diagnosed to have diabetes of non-immune aetiology. He was maintained on insulin (2 IU/kg/day) without achievement of good glycemic control. At the age of 8 months, he was diagnosed to have macrocytic anemia (MCV 105 fl) and since then he was transfusion dependent. At the age of 12 months, hearing assessment revealed bilateral sensorineural hearing loss. He lost follow up then presented at the age of 7 years with dyspnea and abdominal enlargement. Examination revealed pallor, mild hepatomegaly and by cardiac auscultation, there was pansystolic murmur over lower left sternal area. Investigations showed mild diabetic ketoacidosis, glycosylated hemoglobin (HBA1C) 12%, mild elevation of liver enzymes and pancytopenia with reticulocytopenia. Chest X-rays showed cardiomegaly, ECG showed accelerated junctional rhythm and 2-dimensional echocardiography (ECHO) and Doppler showed near-normal systolic function and evidence of diastolic dysfunction with a restrictive filling pattern suggestive of restrictive cardiomyopathy with mild tricuspid regurge and mitral regurge. Genetic testing identified that he was homozygous for a SLC19A2 nonsense mutation, p.Trp387Ter. Both parents were heterozygous for the same mutation. He started treatment with thiamine 50 mg/day which increased gradually to reach 150 mg/day with improvement of his complete blood count (CBC) and decrement of insulin requirements to 1.2 IU/kg/day, over a period of three weeks. Low dose diuretics were started for his cardiac condition. After one year of follow up, his HBA1C is 7 %, he has normal CBC and ECHO showed improvement of diastolic dysfunction but he still has absent P wave in his ECG.



## Conclusion

Patients with the classic triad of megaloblastic anemia, sensorineural hearing loss, and diabetes mellitus should undergo genetic testing for SLC19A2 mutations. Prompt recognition and genetic diagnosis of TRMA syndrome would allow for targeted treatment with thiamine and the dose should be titrated according to the clinical response. To our knowledge, this is the first case of TRMA reported to have restrictive cardiomyopathy.

## References

1. Pomahačová R, Zamboryová J, Sýkora J, et al. First 2 cases with thiamine-responsive megaloblastic anemia in the Czech Republic, a rare form of monogenic diabetes mellitus: a novel mutation in the thiamine transporter SLC19A2 gene-intron 1 mutation c.204+2T>G. *Pediatr Diabetes*. 2017 Dec;18(8):844-7.
2. Mikstiene V, Songailiene J, Byckova J, et al. Thiamine responsive megaloblastic anemia syndrome: a novel homozygous SLC19A2 gene mutation identified. *Am J Med Genet A*. 2015;167(7):1605-9.

## Acknowledgement

For Molecular Genetics Laboratory, Royal Devon & Exeter NHS Foundation Trust, Barrack Road, Exeter, United Kingdom for doing genetic testing.