

Severe Neonatal Hyperparathyroidism due to a Novel Homozygous Mutation of the Calcium-Sensing Receptor (CaSR)

Amir Hacoheh-Solovitz¹, Yardena Tenenbaum-Rakover^{2,3}, Ronen Spiegel^{1,3}, Jeffrey Weinberger⁴, David Gillis⁵, Gershon Goor Zamir⁶, Michael A. Levine⁷, Tal Almagor^{1,2}

¹Pediatric Department B, Ha'Emek Medical Center, Afula, Israel; ²Pediatric Endocrine Institute, Ha'Emek Medical Center, Afula, Israel; ³Rappaport Faculty of Medicine, Technion, Haifa, Israel; ⁴Department of Otolaryngology and Neck Surgery, Hadassah-Hebrew University Medical Center, Jerusalem, Israel; ⁵Department of Pediatrics, Hadassah - Hebrew University Medical Center, Jerusalem, Israel; ⁶Pediatric Intensive Care Unit, Ha'Emek Medical Center, Afula, Israel; ⁷Center for Bone Health, Division of Endocrinology and Diabetes, Children's Hospital of Philadelphia, PA, USA

Background

Homozygous loss-of-function mutations of the CaSR are associated with neonatal severe hyperparathyroidism (NSHPT), a life-threatening condition with a challenging treatment approach.

Case description

A 7-day-old-female infant admitted to our Pediatric Department due to feeding difficulties, lethargy and hypotonicity.

Laboratory evaluation revealed:

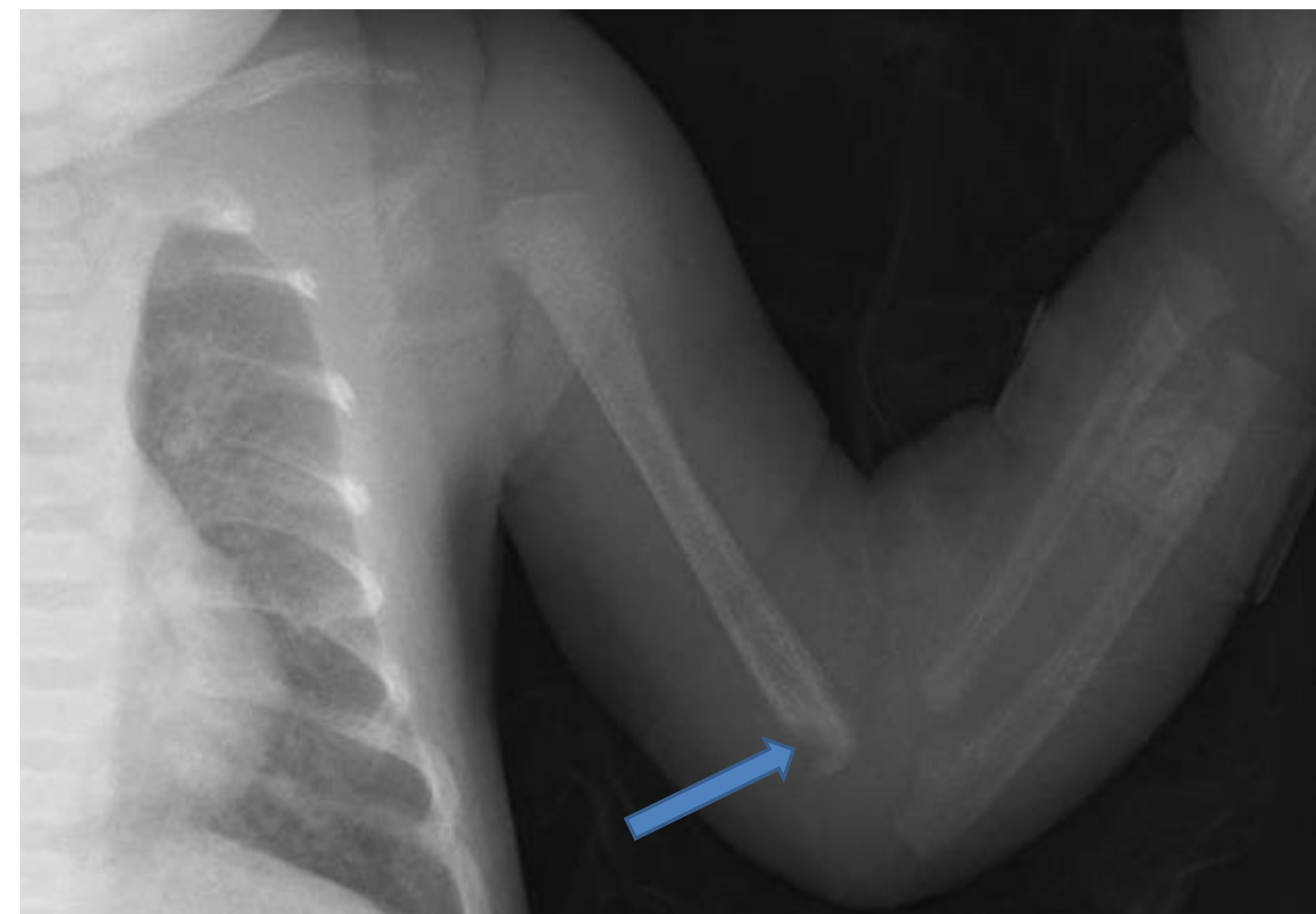
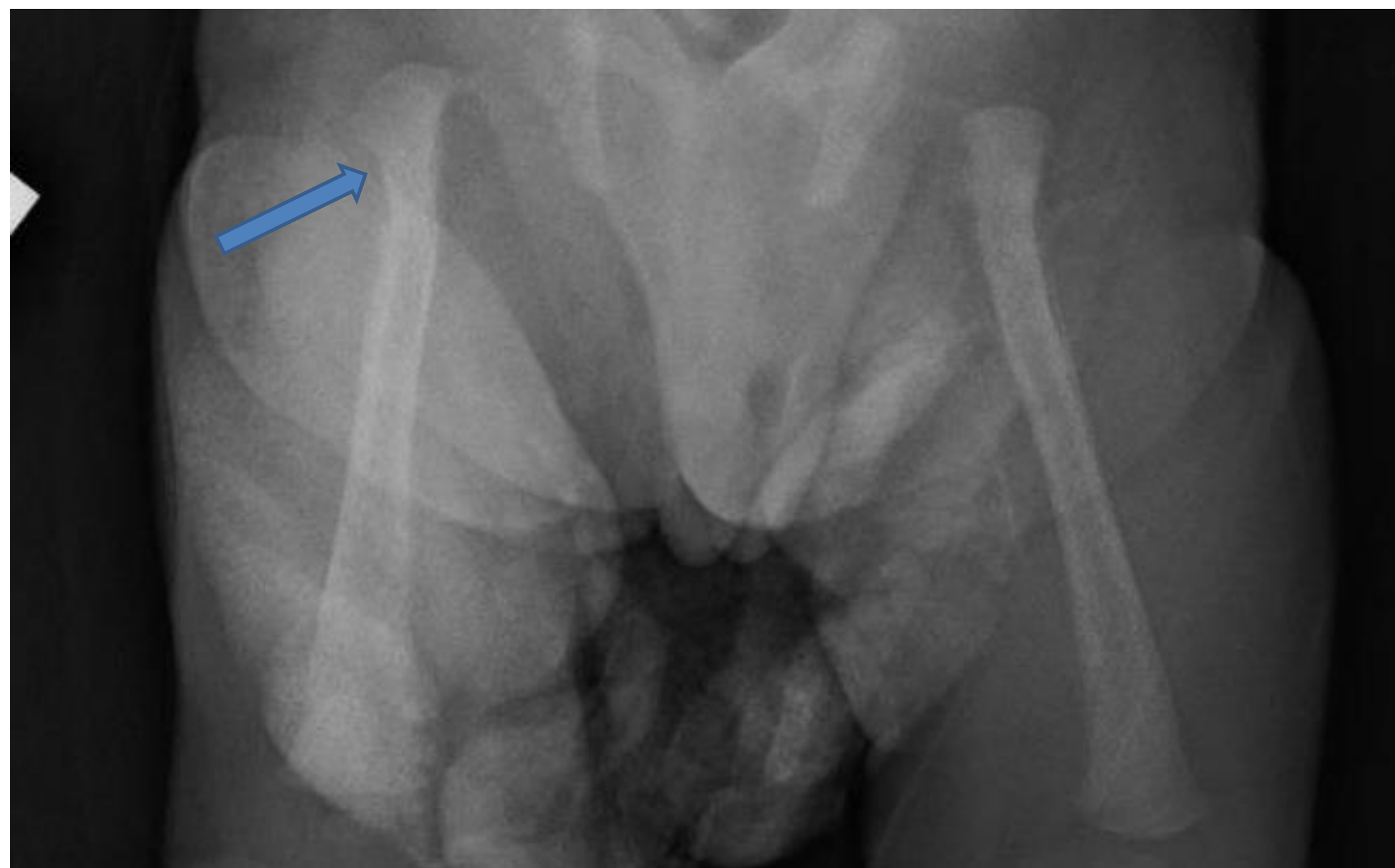Extreme hypercalcemia of 23.54 mg/dL (7.6–10.4)

Low phosphorus levels of 2.16 mg/dL (4.0–6.5)

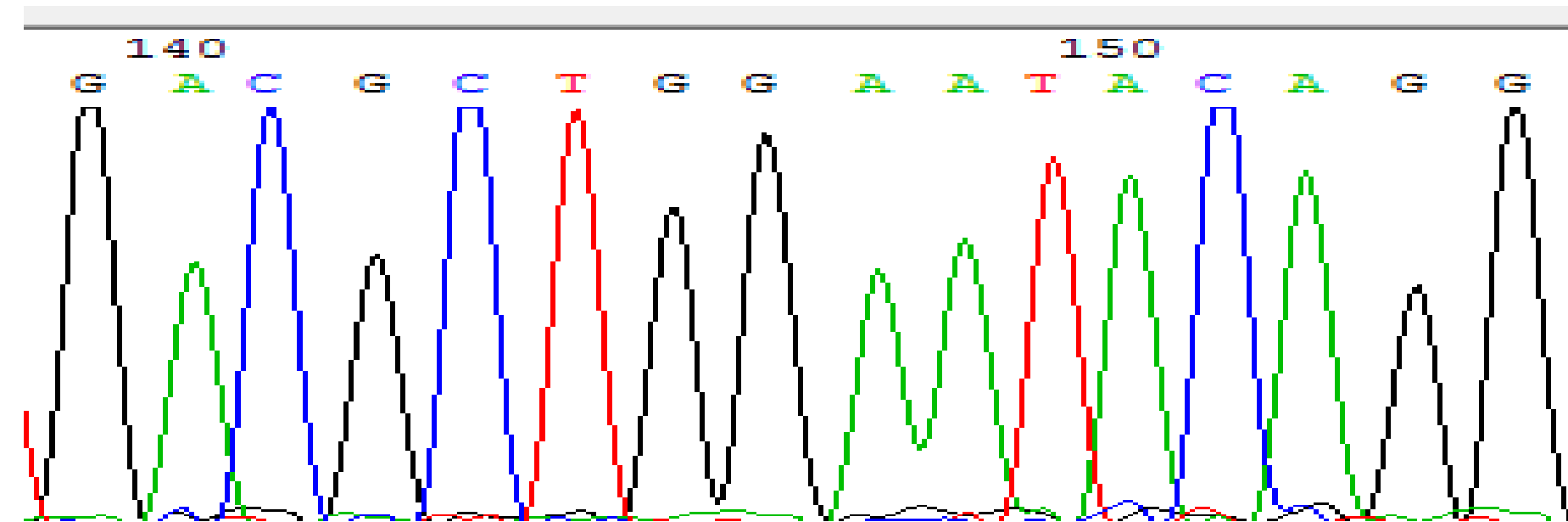
High PTH of 568 pg/mL (18.4–80.1)

Skeletal survey revealed bone deformities with evidence of growth-plate injury and severe osteopenia.

These findings indicate NSHPT.



Sequencing of CaSR identified a novel homozygous mutation: c.281G>A (p.Gly94Glu).

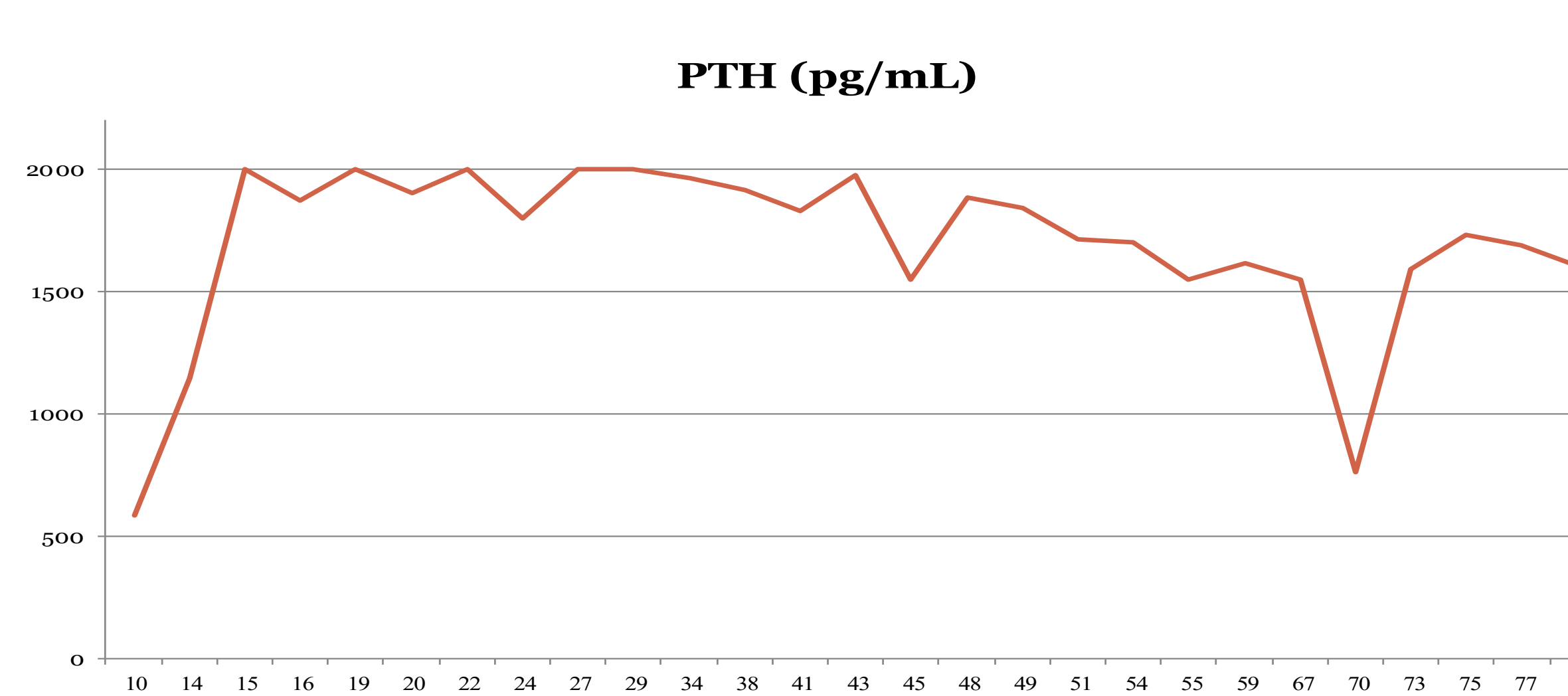
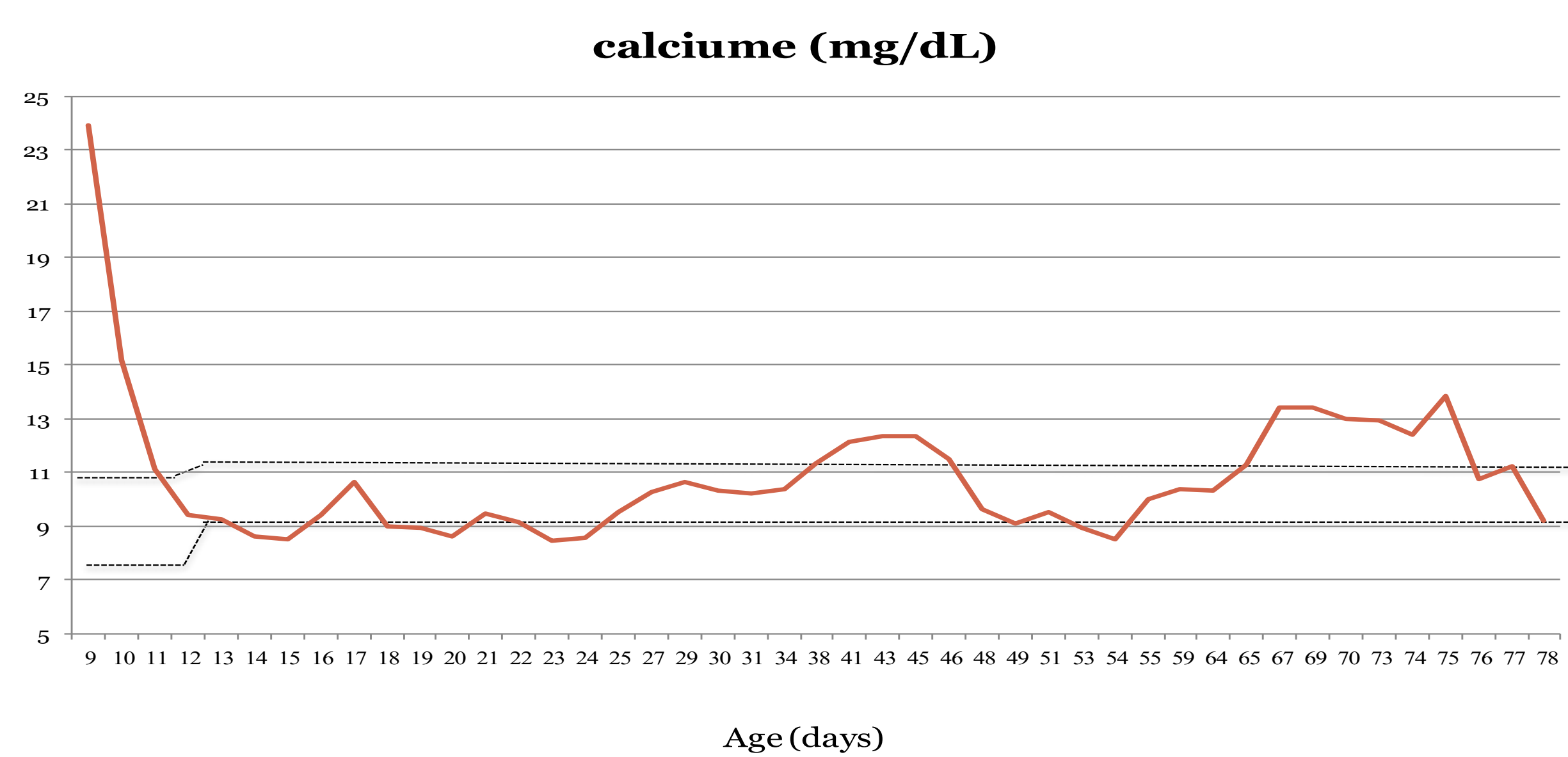


Treatment

Treatment was initiated with aggressive hydration, bisphosphonate IV and calcitonin for the first 24 hours that reduced calcium levels to normal range within days.

Cinacalcet was initiated at a dose of 0.35 mg/kg per day with an increase up to 7.5 mg/kg per day.

Despite normal calcium levels, PTH remained elevated and progressive bone disease was demonstrated.



At 9 weeks of age, **total parathyroidectomy with auto-transplantation** of one gland in the thigh was performed. Later she developed hypoparathyroidism with hypocalcemia of 5.94 (9-11) that necessitated oral calcium and alfacalcidol therapy. Today, at the age of 11 months, the toddler is developing well and maintains normal calcium levels.

Conclusions

- This case report demonstrates the challenges of treating NSHPT and indicates that the therapeutic goal must be to reduce serum levels of both calcium and PTH, as elevated PTH by itself can cause severe bone deformities.
- Cinacalcet treatment should be considered as initial treatment, but if it is ineffective, a definitive hyperparathyroidectomy surgery should not be delayed.