

Valenzise M, Passanisi S, Li Pomi A, Messina MF, Zirilli G, Aversa T

Department of Human Pathology of Adulthood and Childhood "Gaetano Barresi", University of Messina, Messina, Italy.

TOPIC: Growth and syndromes P2-186

Introduction

Turner syndrome (TS) patients are at risk for a wide spectrum of neurocognitive and psychosocial diseases. TS is associated with an increased risk for difficulties with visual-spatial reasoning, visual-spatial memory, attention, executive functioning, motor, and math skills. Additionally, increased rates of social difficulties, anxiety, and depression are observed.

Case presentation

We report the case of a 16-years-old Caucasian girl. She first presented to our Clinic at the age of 18 months due to short stature and clinical signs of TS. Genetic testing showed a single X chromosome and a pericentric inversion of chromosome 9 [45,X,inv(9) karyotype]. Imaging revealed no cardiovascular malformations and/or renal abnormalities. To date no autoimmune diseases have been detected.

At the time of diagnosis she presented a mild mental retardation. During the follow-up years her parents did not attend educational programs prescribed by the neuropsychiatry specialist, and the patient developed a severe emotional disturbance with anxiety and a behaviour pattern characterized by complete language impairment. This behavioural phenotype was consistent with a diagnosis of autism spectrum disorder.

Discussion

Inv(9)(p11q13) is the most commonly observed structurally balanced rearrangement of chromosome involving the heterocromatic region. The estimated frequency varies from 1 to 4 %. Although it is widely debatable, most cytogenetists believe that this variant is a chromosomal polymorphism of the normal human karyotype without any clinical significance. Contradictorily, many clinical investigators have suggested several association of inv(9) with clinical diagnoses, particularly with idiopathic reproductive failure, schizophrenia, and behavioural and neurodevelopmental disorders.

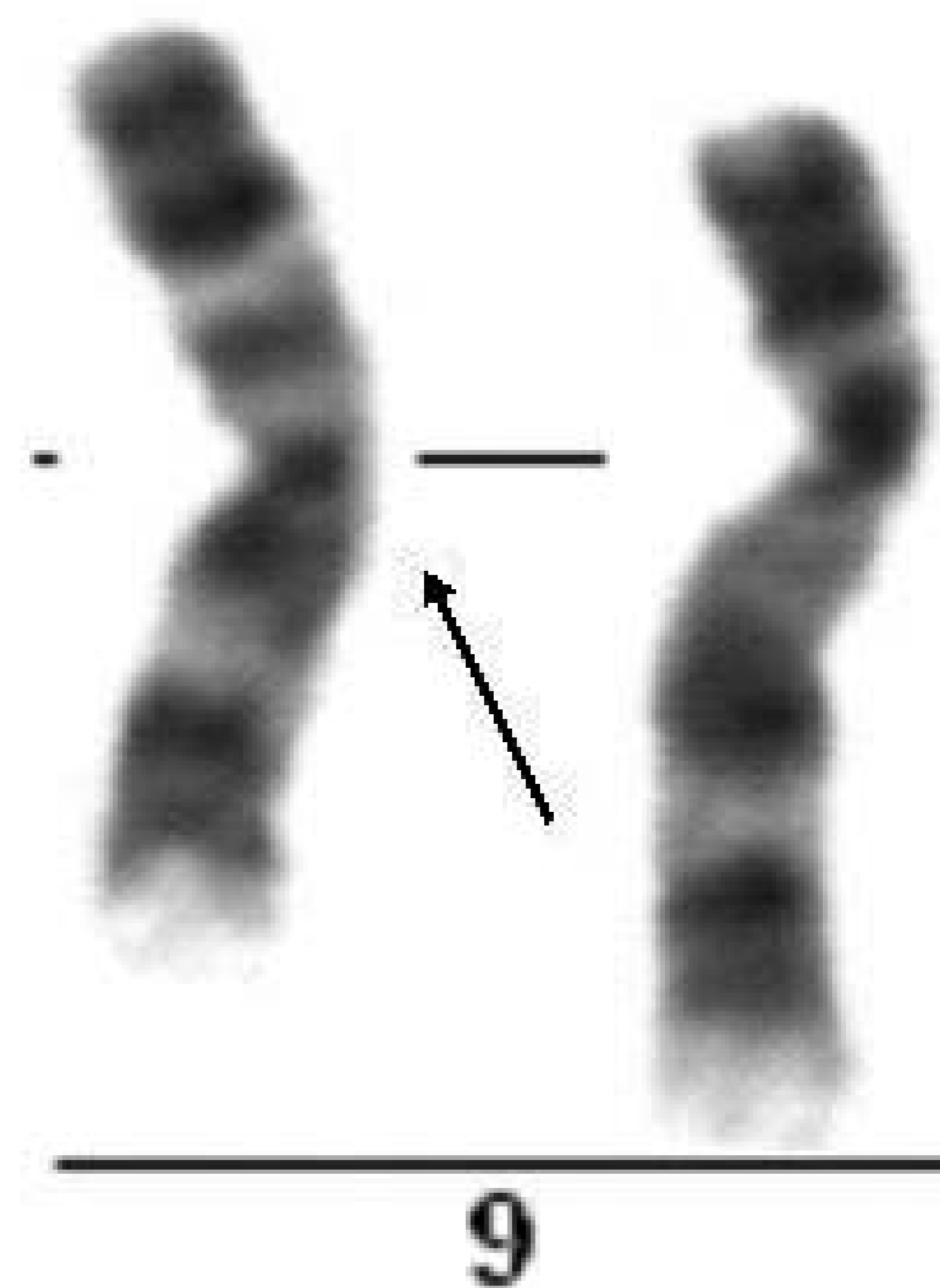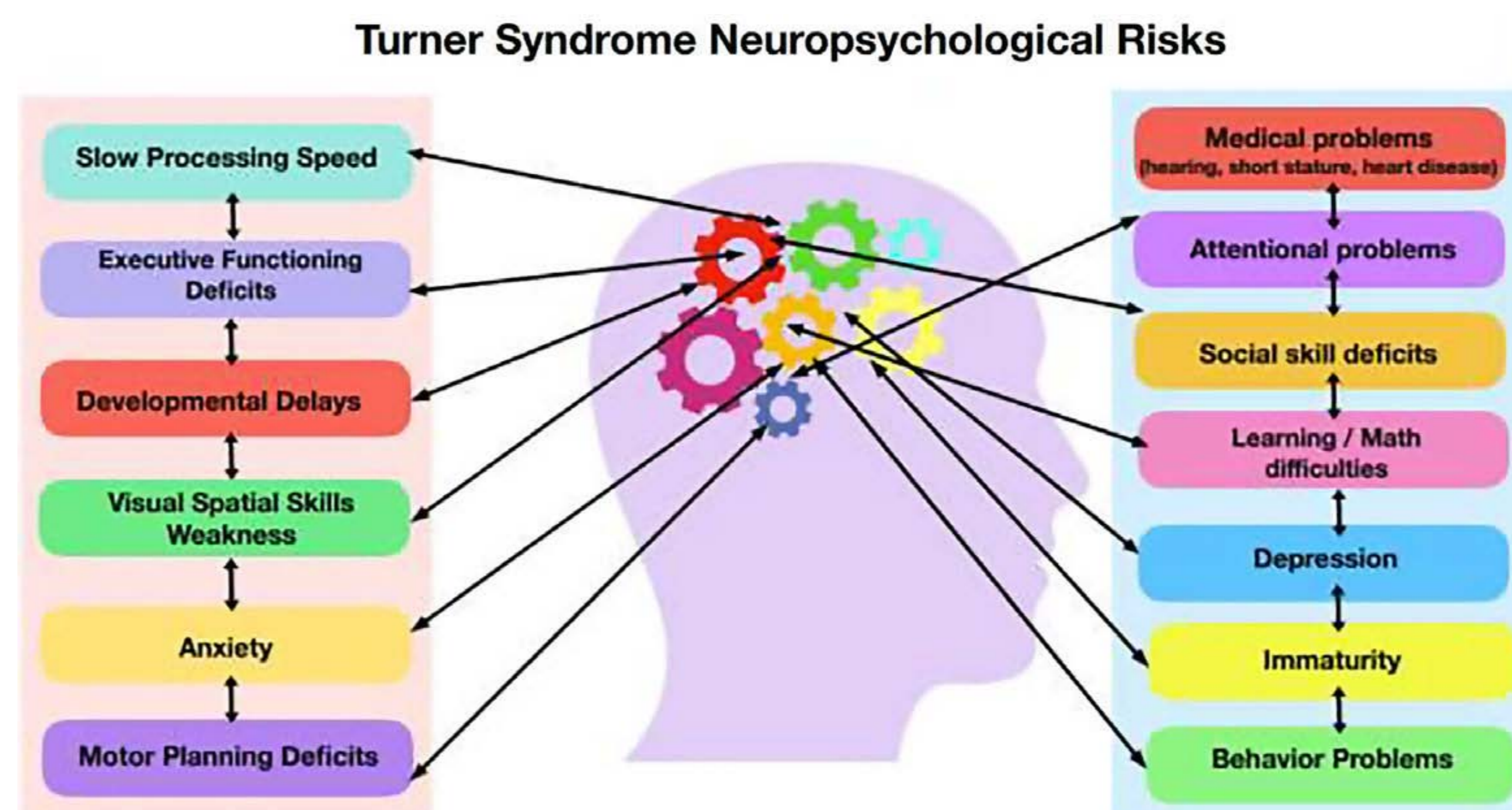
The association of this rearrangement in our patient could explain the severe neurodevelopmental disorder.

Conclusions

Our case report highlights the importance to evaluate eventual associated chromosomal abnormalities in TS patients in order to predict certain phenotypic features of these individuals. As in our patient, the presence of pericentric inversion of chromosome 9 would increase the risk of developing neuropsychiatric disorders. According to the most recent literature, the early identification of psychosocial disease may facilitate the improvement of social deficits through the prompt application of appropriate educational strategies and therapeutic programs.

References

Hutaff-Lee C et al. Clinical developmental, neuropsychological, and social-emotional features of Turner syndrome.. Am J Med Genet C Semin Med Genet. 2019;181:126-134
Šípek A Jr et al. Pericentric Inversion of Human Chromosome 9 Epidemiology Study in Czech Males and Females. Folia Biol (Praha). 2015;61:140-6.



Microphotograph of human chromosome 9 with the most common type of pericentric inversion: inv(9)(p11q13) on the left; G-banding.