

Subcutaneous ossifications in children - think about AHO!

M. Flury¹, F. Quitter¹, O. Hiort², A. Huebner¹

¹Division of Pediatric Endocrinology and Diabetes, Department of Pediatrics, Universitätsklinikum Carl Gustav Carus, Dresden, Germany, ²Division of Pediatric Endocrinology and Diabetes, Department of Pediatrics, University of Lübeck, Lübeck, Germany

Background

Pseudohypoparathyroidism (Albright hereditary osteodystrophy (AHO)) is a rare congenital disorder mainly affecting bone and thyroid metabolism as a result of **resistance of parathyroid hormone (PTH) and thyrotropin (TSH), gonadotropins, growth hormone-releasing hormone (GHRH) and calcitonin in the target tissues**. According to the consensus statement "Diagnosis and management of pseudohypoparathyroidism and related disorders" published in 2018, the specific diagnosis is often delayed owing to lack of recognition of the syndrome and associated features.

Case 1

- Two year old boy
- Early onset obesity
- Motor delay
- Abdominal skin/ leg: **lividly discoloured lesions (Fig. 1a)**

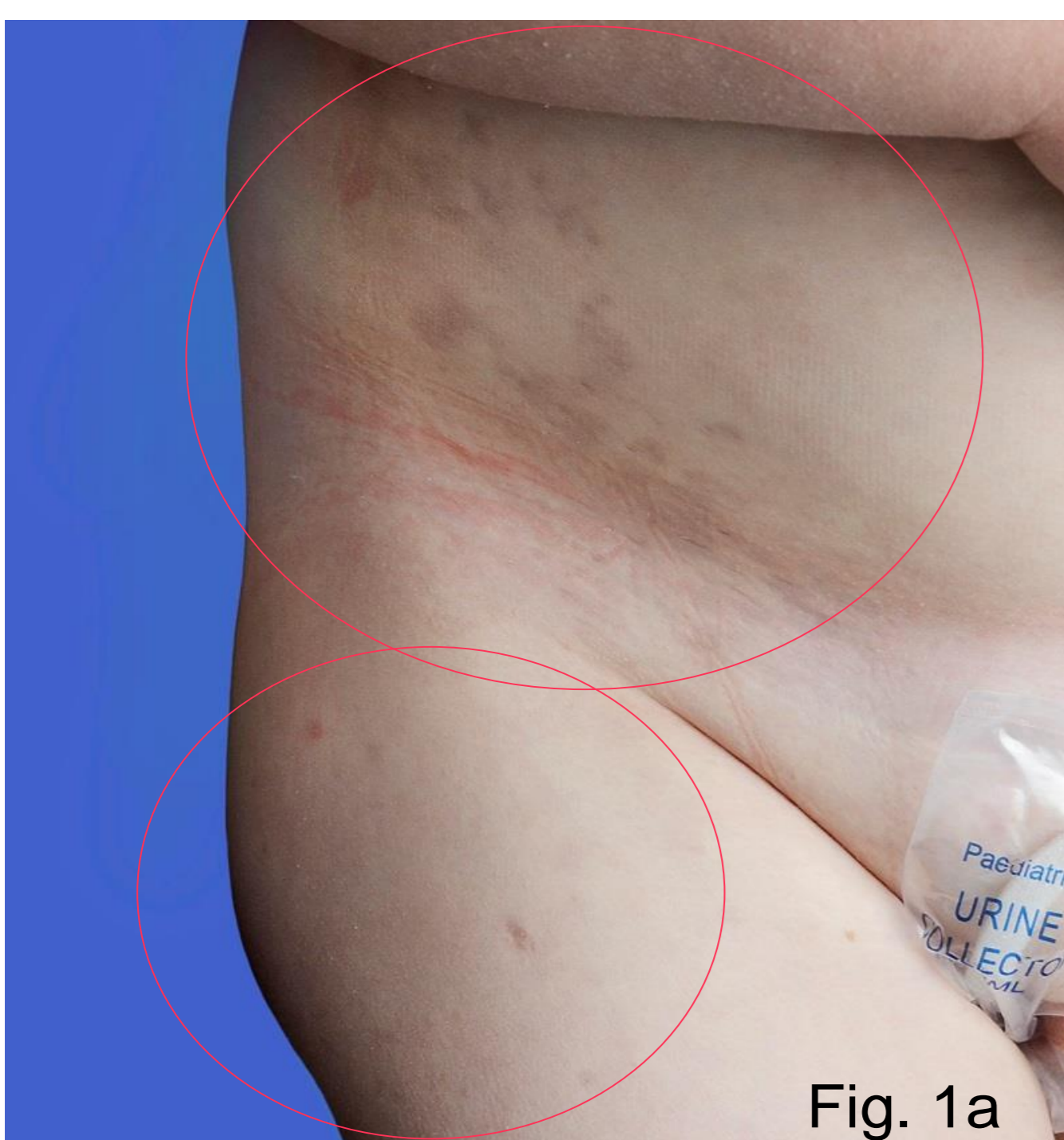


Fig. 1a

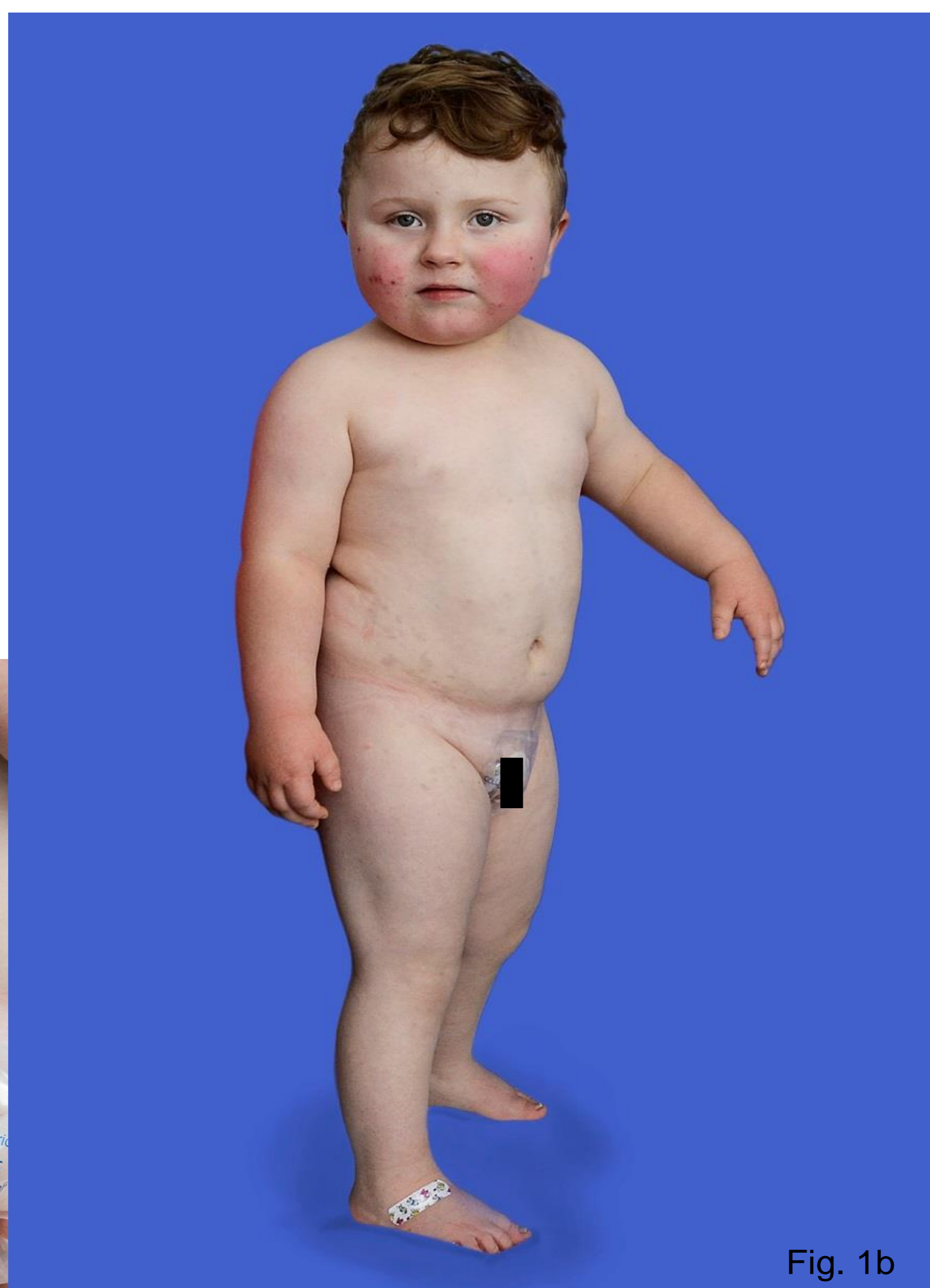

Fig. 1b

Case 2

- Unrelated eight months old boy
- Early onset obesity since the age of five months
- Mild motor delay
- **Intracutaneous calcifications (Fig. 2)**

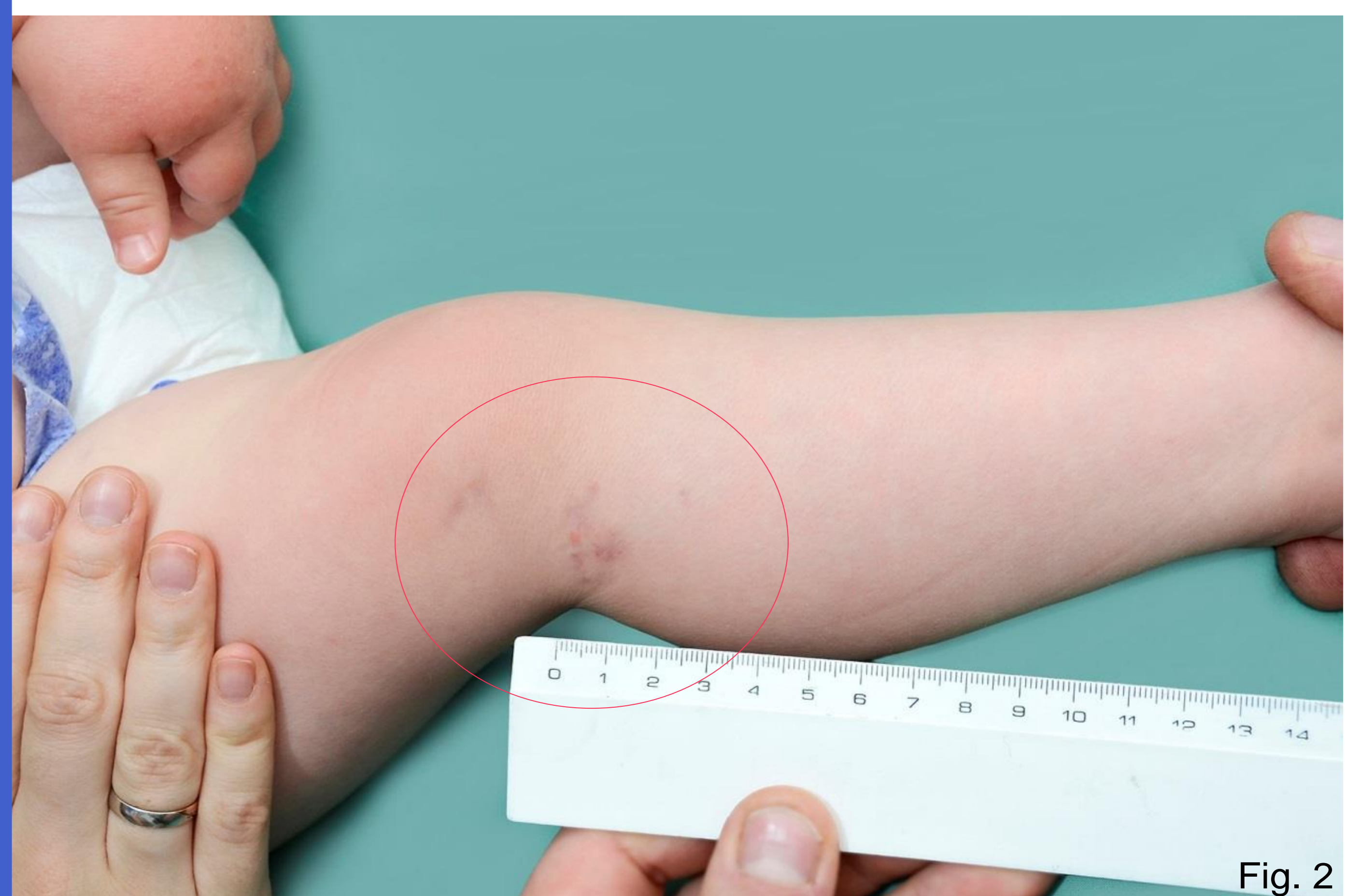

Fig. 2

Results

In both children we found high parathyroid hormone serum levels (442 pg/mL and 88 pg/mL, normal range: 11-67 pg/mL) in combination with elevated levels of TSH (9.71 mU/l and 7.24 mU/l, normal range 0.7-5.97). In both patients sequencing revealed a **heterozygous mutation c.565_568delGACT; p.ASP189Metf*14 in the GNAS gene**. This particular mutation has already been described and confirmed the diagnosis AHO.

Clinical features of AHO:

- Subcutaneous ossifications
- Early onset obesity
- Motor delay
- (Cognitive Impairment)

Therapy

Levothyroxine and calcitriol treatment as well as physiotherapy were immediately started.

Levothyroxine
1,5 -2 µg/kg

Calcitriol
15-25 ng/kg

Physiotherapy

Additional
symptomatic
therapy

Conclusion Subcutaneous ossifications combined with motor delay and early onset obesity may often be the single clinical signs of pseudohypoparathyroidism. Paediatric endocrinologists should therefore advise their paediatric colleagues about this syndrome and its clinical picture and motivate them to transfer these patients to a paediatric endocrine centre for further management.

References Diagnosis and management of pseudohypoparathyroidism and related disorders: first international Consensus Statement. Nat Rev Endocrinol. 2018 August ; 14(8): 476–500.