

# Family Perrault syndrome in two Tunisian sisters

Dr W. Safi(1), Dr F. Hadj Kacem(1), Dr I. Gargouri(1), Dr A. Zargni(1), Dr N. Rekik(1); Dr N. Charfi(1), Dr S. Masmoudi(2), Dr M. Mnif Feki(1), Dr H. Hadj Kacem(2), Dr M. Abid(1)  
 (1)Endocrinology Departement , Hedi Chaker Hospital.Sfax, Tunisia  
 (2)Center of Biotechnology of Sfax/Tunisia

## Introduction:

Perrault syndrome (PS) is a rare disease characterized by a premature ovarian failure (with primary or secondary amenorrhea) and a sensorineural deafness. In this context we report the case of two sisters issuing from consanguineous parents presenting the association of these two anomalies.

## Cases:

	Case 1	Case 2
Age (years)	16	21
Sexe	Female	Female
Deaf-mutism	+	+
Height (cm)	150	156
Tanner stage	S1A2P2	S1A2P2
Karyotype	46,XX	46,XX
Pelvic ultrasound	absence of ovaries, hypoplastic uterus	absence of ovaries ,hypoplastic uterus

Fig.1: Family Pedigree

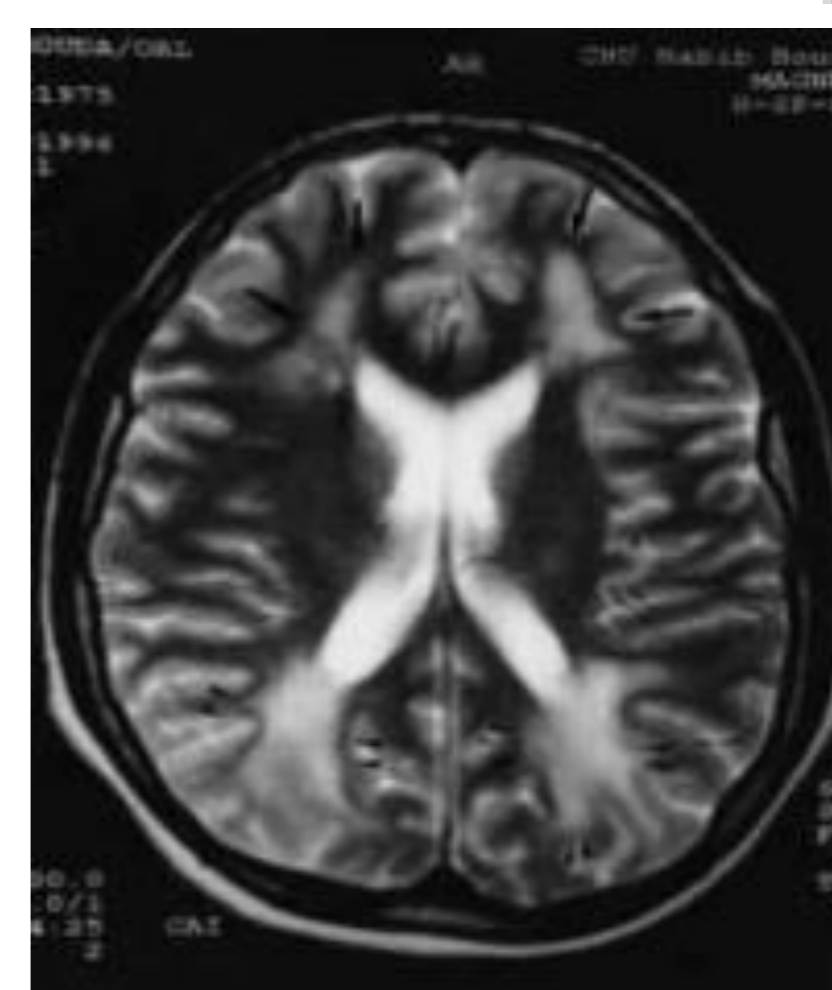
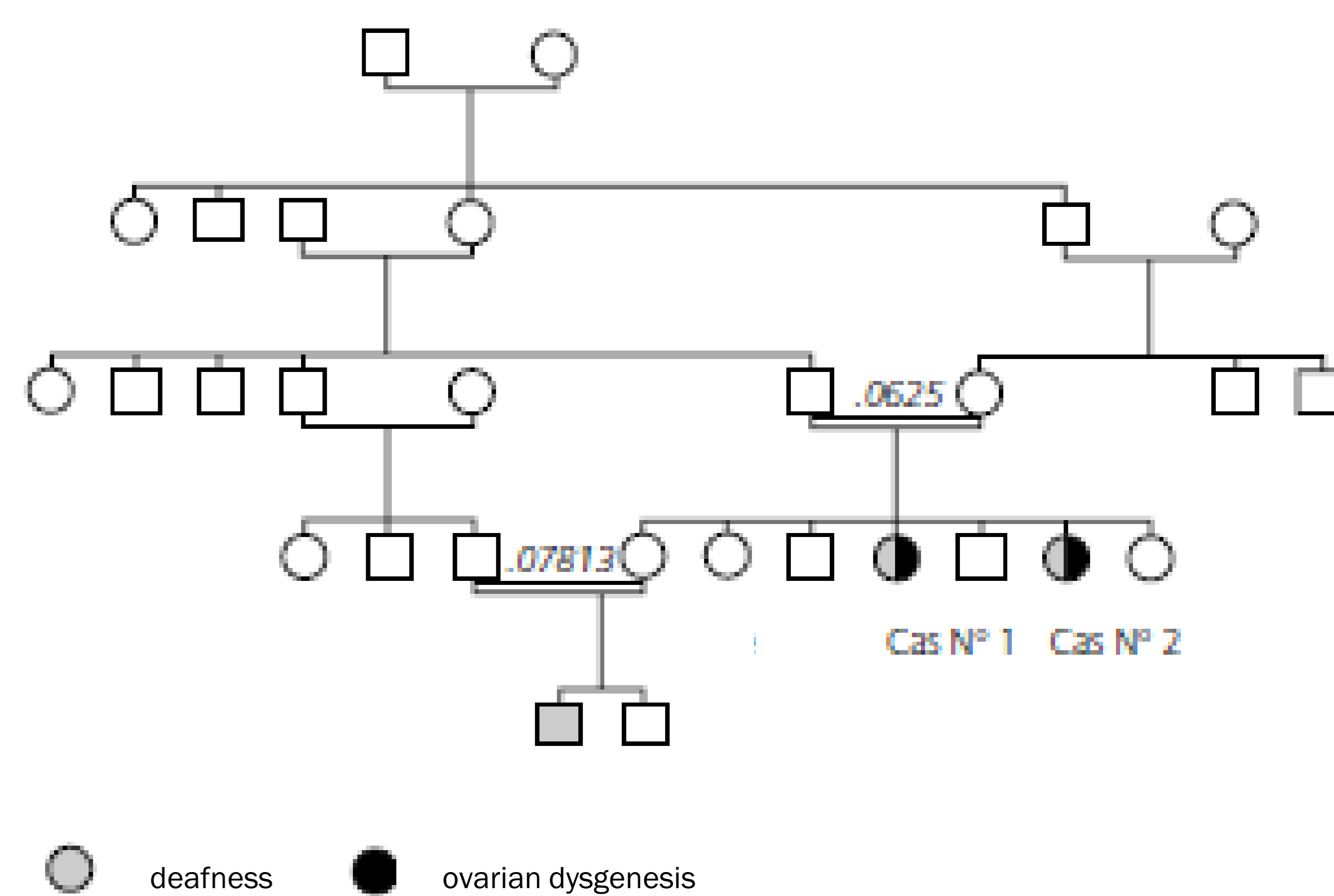


Fig.2: T2 weighted MRI axial section of the brain high signal lesion of the periventricular and subcortical white substance

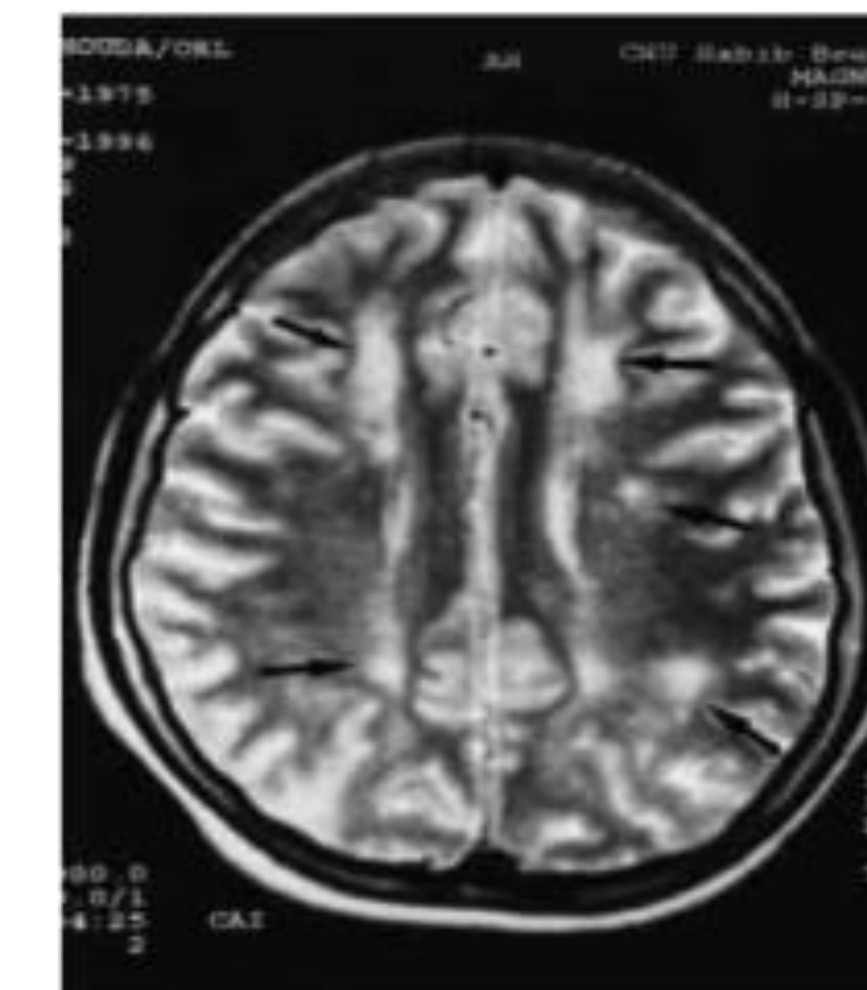


Fig3.:T2 weighted MRI axial section of the brain high signal lesion of the centrum semiovale

Our patients were two sisters (Fig.1) with primary amenorrhea in both cases aged 16 and 21 years respectively. On examination the assessment of their tanner stage was S1P2A2 and both girls also suffer from congenital deaf-mutism and a strictly normal clinical examination, in particular their neurological state because some neurological features are often described such as cerebral ataxia, neuropathy, mild development delay or oculomotor disorders in Perrault Syndrome.

The hormonal exploration objectified a typical profile with hyper-gonadotropic hypogonadism and their karyotypes highlight a chromosomal formula compatible with gonadal dysgenesis 46 XX. The pelvic ultrasound confirms the absence of ovaries in both cases and the presence of a hypoplastic uterus.

An additional medical imaging by cerebral magnetic resonance (Fig2,3) in the second daughter shows the presence of signs of cerebral leukodystrophy without clinical manifestations from where the interest a regular follow-up of the patient with neurologic examination and repeated audiograms could allow detecting precociously a deafness or neurologic troubles which could appear later on Perrault syndrome.

DNA of family members will be explored by hole exon sequencing to identify a pathogenic mutation of already reported genes( up to date 6 genes involved in Perrault syndrome ) or new ones.

Table2	Case 1	Case 2
FSH mU/l (1-10)	82	89
LH mU/l (1-8,5)	47	39
PRL ng/ml (0-25)	5,6	10
Estradiol pg/ml (10-55)	<9	<9
TSH mU/ml (0,2-6)	3,6	3,7

## Conclusion:

Perrault syndrome is a heterogeneous disorder, which is an agreement with different etiological mechanisms. And this syndrome is underestimated in adult patients. Etiopathogenic link between premature ovarian failure and sensorineural deafness may involve genes implied in ovarian development and differentiation and/or neurosensoriel system development or differentiation .