

Pseudo-precocious puberty in children triggered by incidental transdermal contamination with topical sex steroids through parents

Yakovenko V., Choukair D., Mittnacht J., Duffert C., Klose D., Bettendorf M.

Zentrum für Kinder – und Jugendmedizin Heidelberg, Klinik I – Sektion Pädiatrische Endokrinologie und Diabetologie
Im Neuenheimer Feld 430 · 69120 Heidelberg, Germany ·

Conclusion: Incidental contamination by topical sex steroids from parental medication is a rare but potential cause of iso- or heterosexual pseudo-precocious puberty in children. Parents are unaware of the chance of passive transfer to their child. Therefore, patients need to be educated before starting treatment with topical sex steroids in order to avoid transdermal transmission of sex steroids to family members. Discontinuation of contact, switch to oral or iv medication, change of attitudes (stop use 1 towel, avoid direct skin contact after application) resulted in a decrease of sex steroids levels and regression of symptoms.

Background: Pseudo-precocious puberty may be triggered by either endogenous or exogenous sex steroids. The overall incidence of sexual precocity is estimated to be 1:5,000 to 1:10,000 children. The female-to-male ratio is approximately 10:1. Accidental ingestion of contraceptives, anabolic steroids or life style products containing sex steroids as well as transdermal transmission of topical sex steroids may cause early onset of secondary sexual development. We report the clinical course of incidental contamination with topical sex steroids in children applied by their parents for replacement therapy.

Patients: Three patients (two girls and one boy) presented at 6 months, 4.9 years and 4.4 years with signs of precocious puberty for further evaluation. The boy (4.4 years) and one girl (4.9 years) presented with breast gland enlargement (Tanner stage 2). Both patients' mothers reported self-application of transdermal-estradiol for treatment of ovarian failure. The second girl aged 6 months presented with premature pubarche and hyperpigmentation of the labia majora. Her father applied testosterone gel.

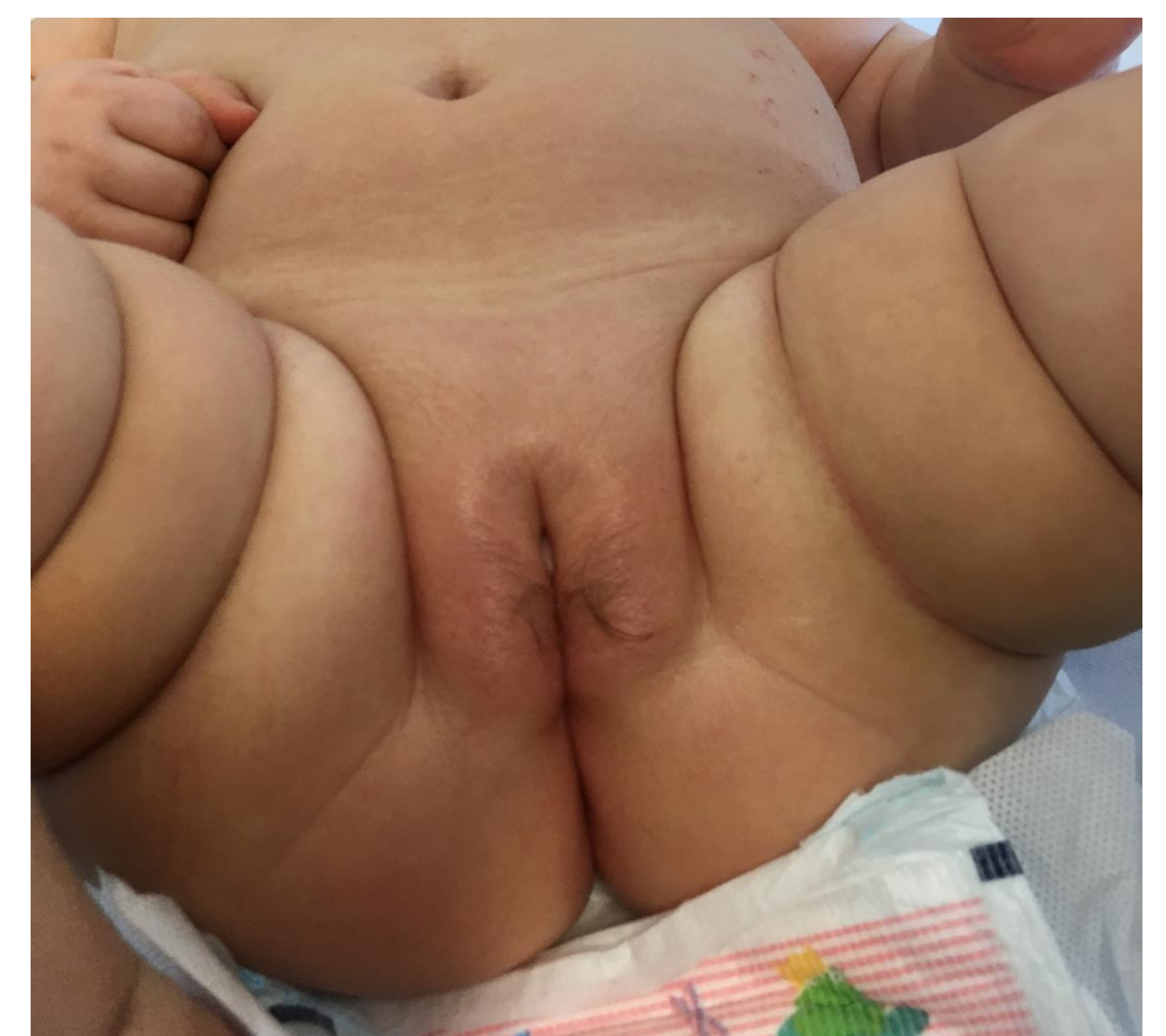
Diagnostic and clinical course

Height velocity was accelerated in all patients (table 1). Bone age according to Greulich & Pyle was accelerated by 6 months in 6 month girl and by 2 years in 4.9 years girl. The two children with breast enlargement had detectable serum concentrations of 17β-estradiol with 18.1ng/ml in the girl and 25.6 ng/ml in the boy. The girl with premature pubarche presented with total testosterone level above age and gender related references (546 ng/dl) Serum gonadotropins were low and appropriate to age in all patients (LH<0,1U/L, FSH 2.1-5.8U/L).

Table 1: Anthropometry and Diagnostic

	Pat. A		Pat. B		Pat. C		
	First examination	Control	First examination	Control	First examination	Control 1	Control 2
Height SDS	-0,15	-0,18	0,12	0,14	1,72	2,03	1,94
Height velocity SDS	4,48	3,5		5,1	5,84	4,27	-0,96
Tanner stage	PH1, B2 L breast bud 2 cm, B1-2 R, A-	PH1, B1-2 both sides, L>R, no glandular tissue, A-	PH1, G1, TV 2 ml, Breast bud 2 cm R, 1,5 cm L, A-	PH1, G1, TV 2ml, no glandular tissue, A-	PH2, labiae majores pigmented, no clitoral hyper-trophy, B1, A-	same stage	PH1, no hyper-pigmentation, discrete hairs on the edges of the labia majora, B1, A-
Testosteron	--	--	2		8,39	11,6	<0,03
Norm ng/dl	--	--	2-20		0,3-0,6	0,2-1	0,3-0,6
Estradiol	18,1	<11,8	25,6	<11,8	<11,8	<11,8	<11,8
Norm pg/ml	7-13	7-13	7-10	7-10	7-13	7-13	7-13
Bone age Greulich&Pyle	2 years ahead		3-6 Mo ahead				

Figure 1: Girl with premature pubarche at first presentation



Contact: Dr. med. Vira Yakovenko. Email: Vira.Yakovenko@med.uni-heidelberg.de URL: www.klinikum.uni-heidelberg.de