

Yijuan Yvonne Lim, Anjian Andrew Sng, Cindy Wei-li Ho, Beng-hui Nicholas Ng, Kah-Yin Loke, Yung-Seng Lee
Khoo Teck Puat-National University Children's Medical Institute, National University Health System, Singapore
Department of Paediatrics, Yong Loo Lin School of Medicine, National University of Singapore

Background:

Paraneoplastic Cushing syndrome is extremely rare in paediatric oncology. To date, there are 6 reported cases related to Wilms' tumour. The first documented case was in 1974 described by Cummins and Cohen. The 4.5-year-old boy presented with excessive weight gain, hypertension and abdominal mass. Histology revealed Wilms' tumour. Adrenocorticotrophic hormone (ACTH) was elevated in the serum and tumor material, confirming the diagnosis of Cushing's syndrome secondary to an ACTH-secreting Wilms' tumour. He was covered peri-operatively with steroids with progressive reduction after the surgery. The mechanism by which these non-endocrine neoplastic tissues develop the ability to produce ACTH or corticotropin releasing hormone (CRH) is not fully understood. We describe a patient who presented with Cushing syndrome and was subsequently found to have Wilms' tumour.

Case report:

Our patient is a 9 year-old boy, who presented with hyperphagia and excessive weight gain for 3 months. His abdomen was also progressively bigger. There was no ingestion of steroids or traditional medication. Subsequently he sought medical advice because of persistent cough and was found to be hypertensive with features of Cushing syndrome. On physical examination, his height was 123cm (50-75th centile) and his weight was 32.3kg (90-97th centile). He had features of Cushing syndrome with moon-like facies and buffalo hump. There was a firm ballotable mass in the left upper quadrant region. A Computed Tomography of the abdomen revealed a 9.2 x 12.7 cm mass arising from the upper pole of the left kidney likely to be Wilms' tumour. The adrenal glands could be visualized and looked normal. We proceeded to perform a low dose dexamethasone suppression test followed by high dose dexamethasone suppression test which confirmed the diagnosis of Cushing syndrome which is not adequately suppressed by low dose dexamethasone. While suppression during high dose dexamethasone test suggest pituitary Cushing disease, his Magnetic Resonance Imaging of the pituitary gland was normal. His ACTH level was 9.2 pmol/L. The patient underwent a left radical nephrectomy and partial adrenalectomy. He was covered with stress dose of hydrocortisone peri-operatively. Biopsy showed Stage I Wilms' tumour (Blastemal predominant). Immunohistochemistry for ACTH was negative in the tumour cells. We were not able to perform immunohistochemical studies for CRH. His hydrocortisone was eventually weaned off. By a year after the operation, he was back to his normal habitus, and there was no clinical feature of Cushing syndrome.

Conclusion:

The resolution of Cushing syndrome after the Wilms' tumour was treated showed that this was likely a case of paraneoplastic Cushing syndrome. The challenge lies in the diagnosis and the management of steroid therapy post-operatively. We also highlighted the patient's peculiar cortisol secretory pattern and his response to both dexamethasone suppression tests.

Time	12MN	8am	12MN	8am	12MN	8am	12MN
Dose of dexamethasone				0.5mg hourly	6 0.5mg hourly	6 0.5mg hourly	6 0.5mg hourly
Cortisol (nmol/L)	152	200	71	85	562	952	1040
ACTH (pmol/L)	7.9	8.2	9.2	6.5	8.7	7.6	7
24hrs urinary free cortisol (nmol/day)		29		95		1941	

Table 1. Low dose dexamethasone suppression test

Time	8am	12MN	8am	12MN	8am
Dose of dexamethasone	2mg 6 hourly	2mg 6 hourly	2mg 6 hourly	2mg 6 hourly	
Cortisol (nmol/L)	737	277	207	75	80
ACTH (pmol/L)	7.3	7	6.8	5.7	6
24hrs urinary free cortisol (nmol/day)	385		81		

Table 2. High dose dexamethasone suppression test

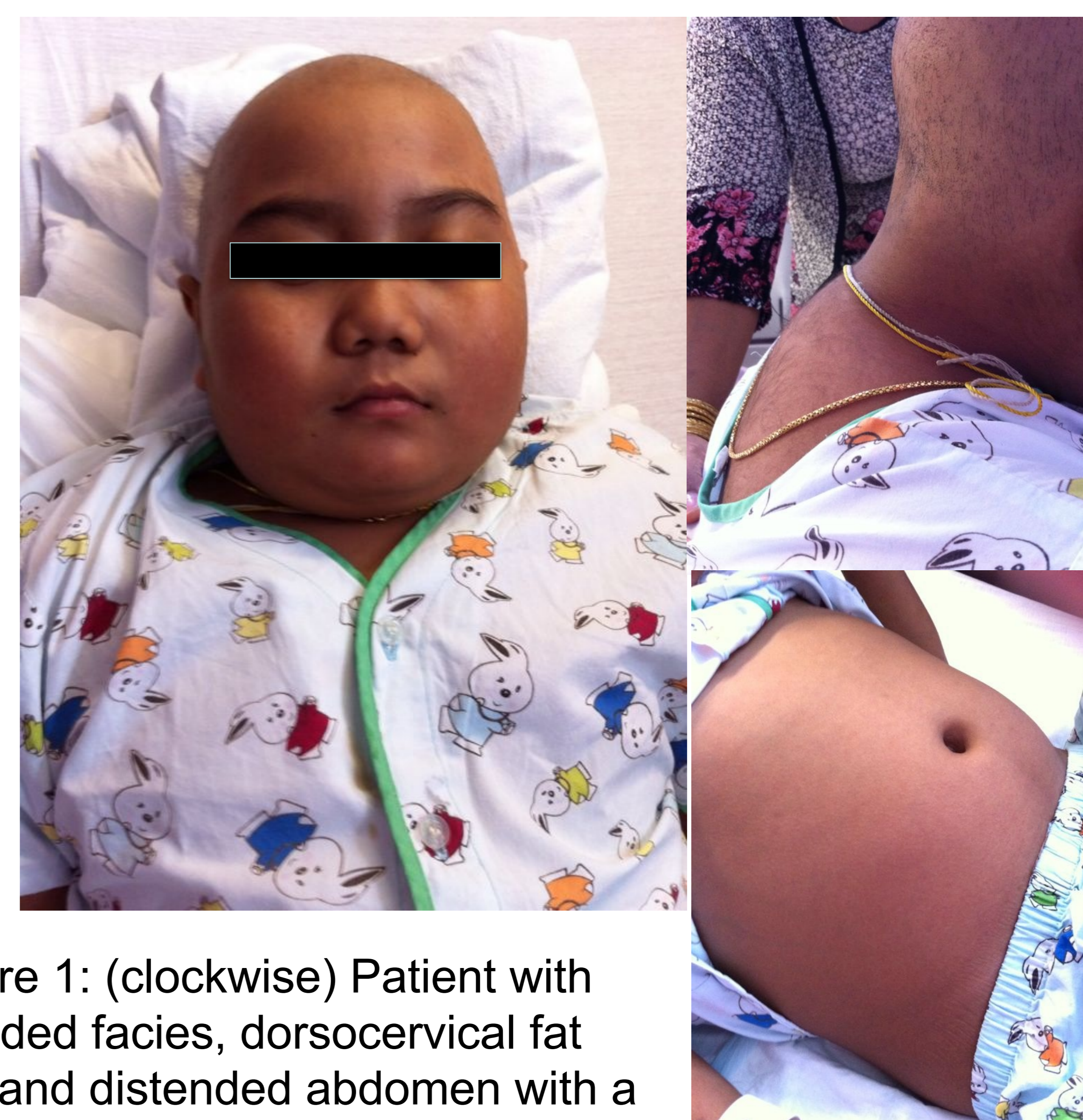


Figure 1: (clockwise) Patient with rounded facies, dorsocervical fat pad and distended abdomen with a firm ballotable mass palpable in the left upper quadrant region

References

1. Wang et al. (2008) Paraneoplastic Cushing Syndrome because of corticotrophin-releasing hormone-secreting Wilms' Tumour. Journal of Pediatric Surgery 43, 2099-2101
2. Cummins and Cohen. (1974) Cushing's Syndrome Secondary to ACTH-secreting Wilms' Tumor. Journal of Pediatric Surgery, Vol 9, No 4 (August), 1974
3. Pena et al. (1982) Ectopic Production of ACTH by Wilms' Tumor. Hormone Res 16:160-163
4. Spahr J, Demers LM, Shochat SJ. (1981) Renin producing Wilms' tumor. J Pediatr Surg. Feb;16(1):32-4.
5. Heuvel-Eibrink et al. (2009) Cushing Syndrome as a Presenting Symptom of Renal Tumors in Children. Pediatr Blood Cancer 53:211-213