

# Pneumocystis Jiroveci pneumonitis complicating neonatal Cushing's syndrome - the therapeutic dilemma

Adi Auerbach<sup>1</sup>, David Gillis<sup>2</sup>, Orly Megged<sup>1</sup>, Sarit Shahroor<sup>1</sup>, Carmit Avnon-Ziv<sup>1</sup>, Harry Hirsch<sup>1</sup>, Floris Levy-Khademi<sup>1</sup>  
<sup>1</sup>Shaare Zedek Medical Center, Jerusalem, Israel. <sup>2</sup>Hadassah Medical Center, Jerusalem, Israel.

## Background:

- Endogenous Neonatal Cushing's syndrome (CS) is a rare condition with around 100 cases reported worldwide.
- Pneumocystis Jiroveci pneumonitis (PJP) is a well described rare complication of exogenous CS.
- The pneumonitis usually occurs following reduction of glucocorticoid dosage and is therefore thought to be triggered by an inappropriate immune reaction after glucocorticoids withdrawal.
- The treatment of this condition includes both antibiotics and glucocorticoids.
- PJP has not been hitherto described in neonatal endogenous CS.

## Objective:

- To describe the problems associated with therapy of life-threatening PJP in a baby with active neonatal CS.

## Case presentation:

- A 3-month old female infant presented with failure of linear growth and mild hirsutism.
- She was diagnosed with CS, with high fasting cortisol levels (893 nmol/l) and paradoxical increase of cortisol levels to 1350 nmol/l after low dose (15 mcg/kg) dexamethasone consistent with micronodular adrenal disease.
- Adrenal size was normal for age by computerized tomography.
- Within days of diagnosis of CS, she developed hypoxemia and severe respiratory distress requiring mechanical ventilation.
- Chest x-ray showed severe pneumonitis and broncho alveolar lavage revealed Pneumocystis Jiroveci infection.

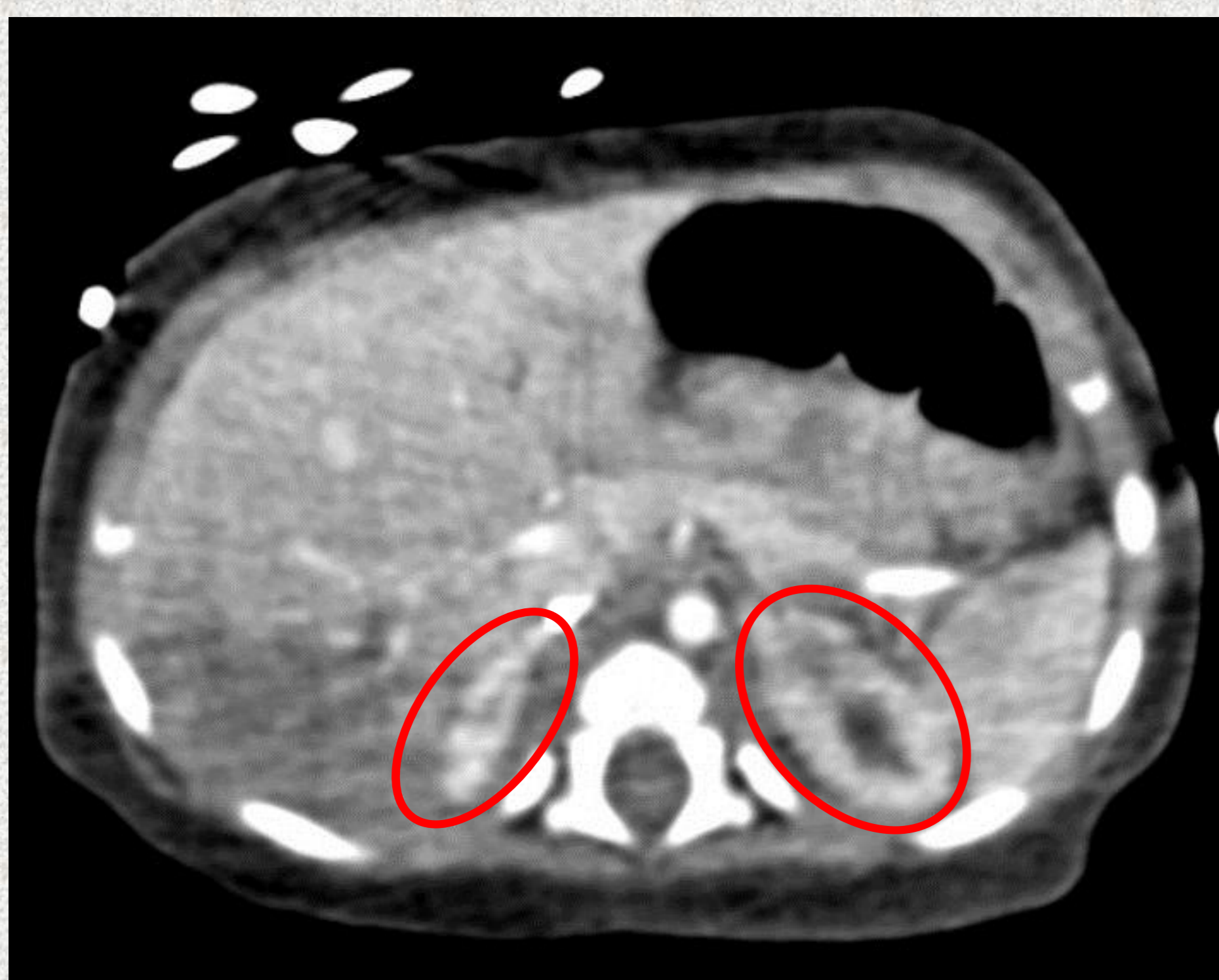

Figure 1: Hyperenhanced adrenal glands with no focal lesion. The adrenal size is normal for 3 months of age.

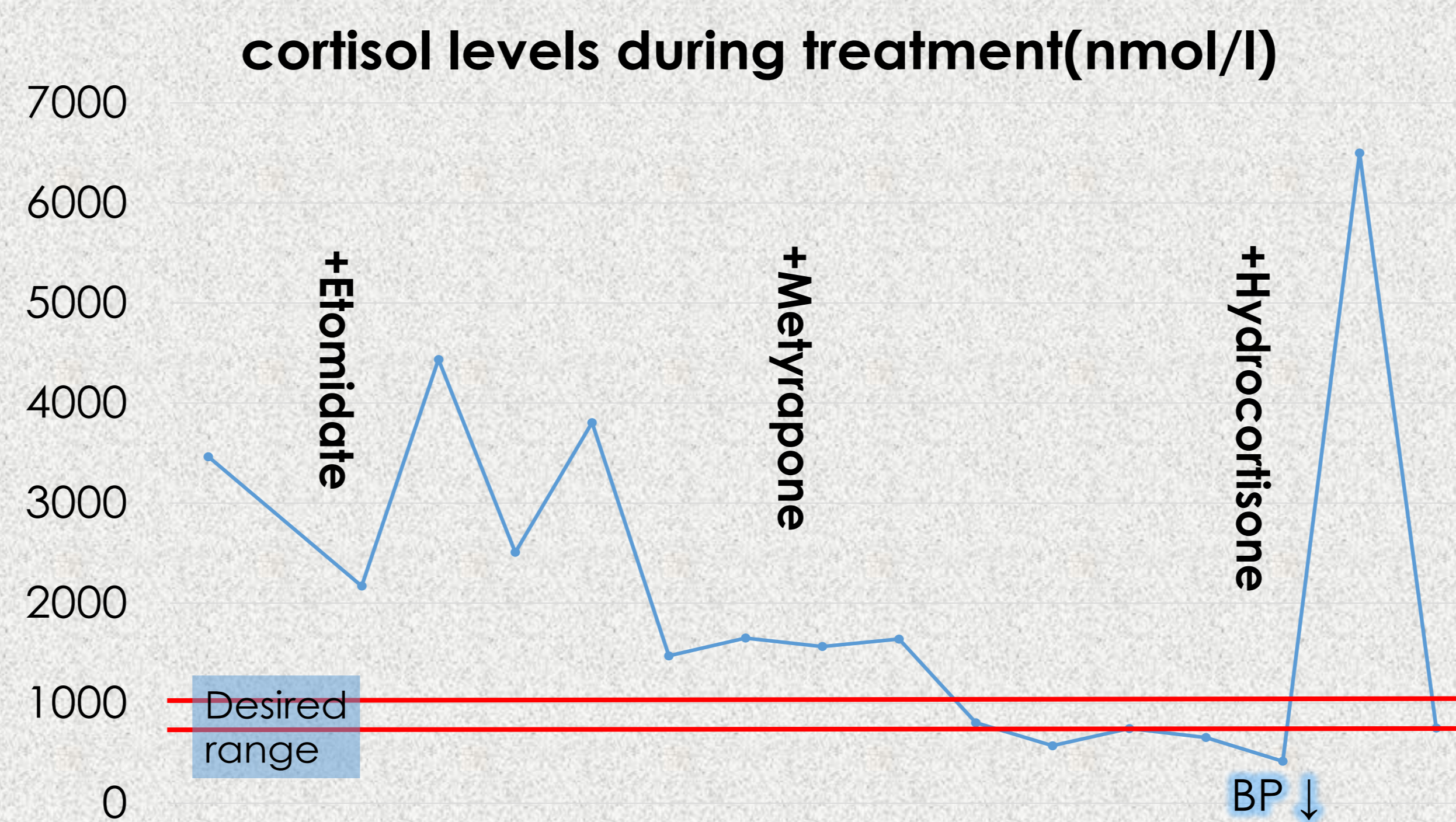


Figure 2: Cortisol levels during Cushing's treatment. Notice the large increase in cortisol after one stress dose of hydrocortisone.

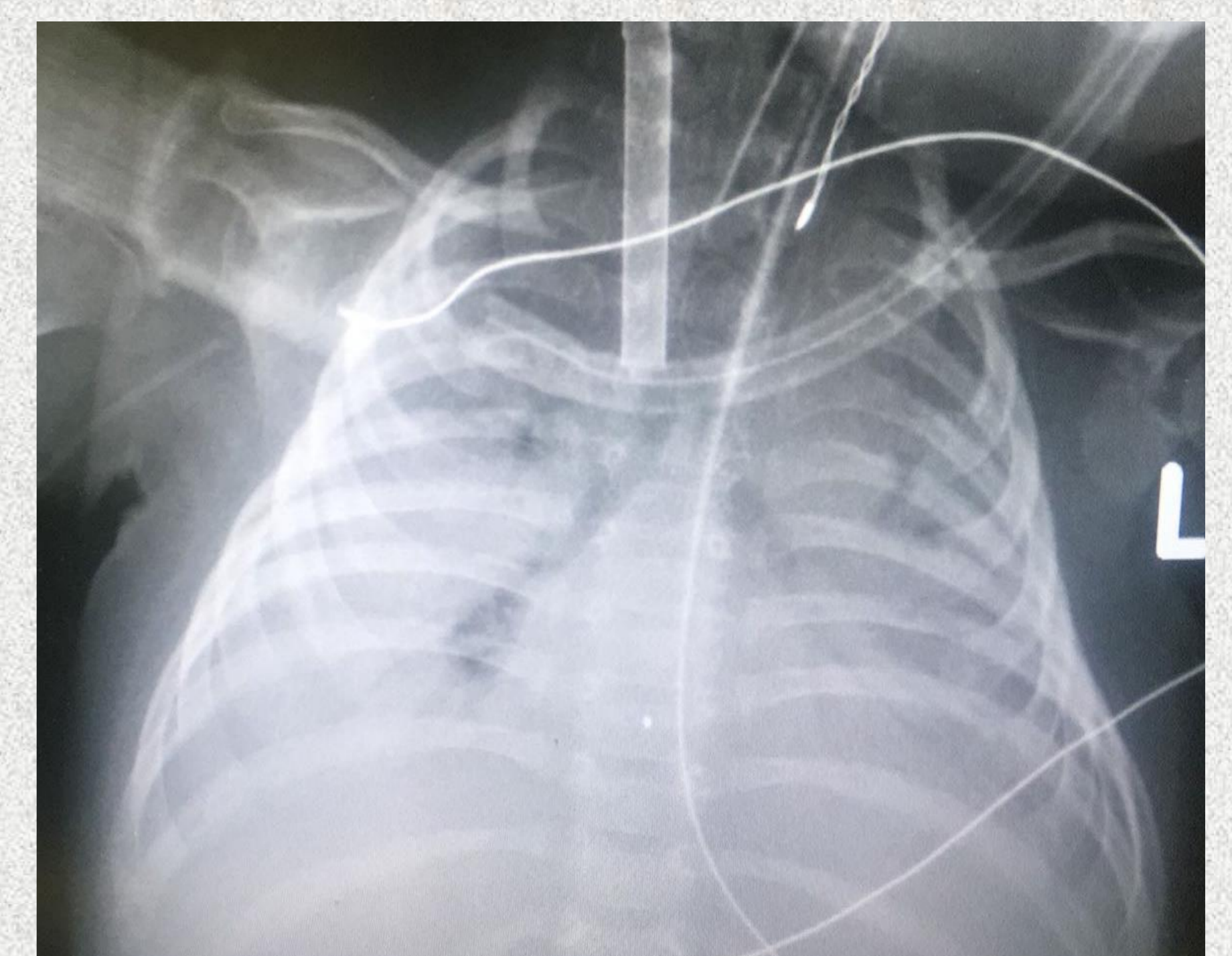


Figure 3: Severe pneumonitis resulting in irreversible pulmonary damage.

- In order to prevent further exacerbation of pneumonitis, treatment of the CS was postponed and antibiotic and corticosteroids were administered.
- Despite treatment and maximum mechanical ventilatory therapy, the baby's pulmonary status continued to deteriorate and Extracorporeal membranous oxygenation (ECMO) was commenced a week after the diagnosis of PJP pneumonitis.
- During PJP treatment the cortisol levels increased to above 3000 nmol/l (probably due to paradoxical response to external glucocorticoids) and hypokalemia and hypertension appeared.
- After eradication of PJP- combined therapy with Etomidate (0.15 mg/kg/h) and Metyrapone (50mg\*6/d) was initiated and cortisol levels were successfully titrated to expected stress levels of 700-1000 nmol/l.
- However, the pulmonary damage was irreversible and after 97 days on ECMO the infant died.
- Genetic analysis of genes related to micronodular adrenal disease such as PRKAR1A and whole-exome sequencing revealed no cause for the neonatal Cushing's syndrome.

## Conclusion:

PJP complicating endogenous CS is a severe life-threatening condition. It is not clear how best to take care of glucocorticoid levels during therapy. This case shows that despite early diagnosis of both CS and PJP, outcome can be fatal. We present this case with the hope that accumulation of experience of this condition may help develop a successful therapeutic strategy for future cases.

Acknowledgment- we would like to thank Dr Constantine A Stratakis and his team at the Program on Developmental Endocrinology & Genetics, NICHD, NIH, for the clinical input, the DNA analysis for PRKAR1A variants and for the generous support in performing whole-exome sequencing.