

# Growth hormone treatment of a patient with X-linked hypophosphatemic rickets caused by PHEX mutation: effects on linear growth

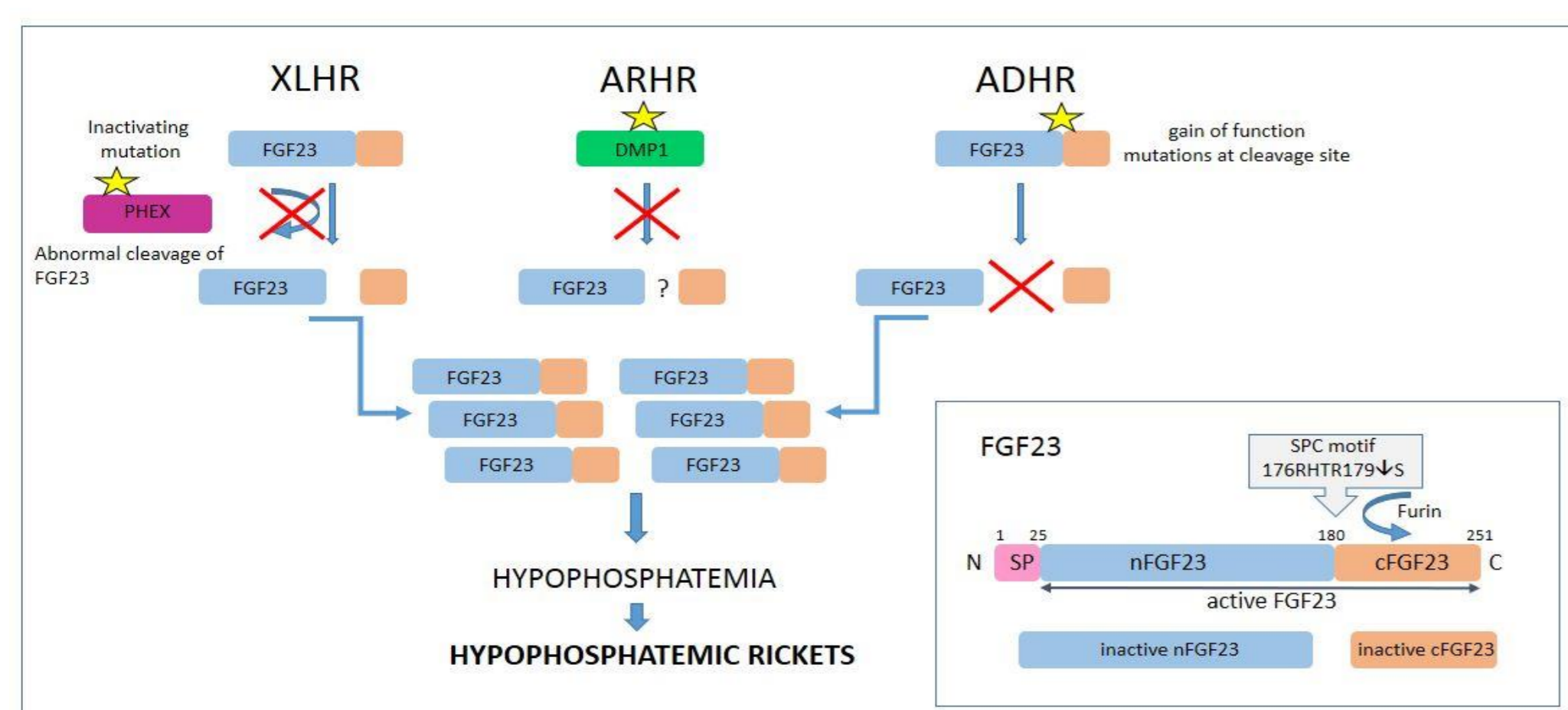


Aleksandra Rojek<sup>1</sup>, Monika Obara-Moszynska<sup>2</sup>, Marek Niedziela<sup>1,2</sup>

**1 Poznan University of Medical Sciences, Department of Pediatric Endocrinology and Rheumatology, Molecular Endocrinology Laboratory, Poznan, Poland, e-mail: [aleksandra.rojek@gmail.com](mailto:aleksandra.rojek@gmail.com)**  
**2 Poznan University of Medical Sciences, Department of Pediatric Endocrinology and Rheumatology, Poznan, Poland, e-mail: [mmoszynska@ump.edu.pl](mailto:mmoszynska@ump.edu.pl); [mniedzie@ump.edu.pl](mailto:mniedzie@ump.edu.pl)**

## OBJECTIVES

Hypophosphatemic rickets (HR) stands for a heterogeneous group of rare disorders in which excessive renal phosphate wasting is observed. The main characteristics of X-linked HR (XLHR) (OMIM #307800) caused by mutation in *PHEX* (phosphate-regulating endopeptidase) gene (OMIM \*300550) include bone deformities, disproportionately short stature, dental anomalies and hypophosphatemia with coexisting low renal phosphate reabsorption. The patient's growth may be improved by early treatment with vitamin D, phosphate, as well as recombinant human growth hormone (rhGH) which acts on growth cartilage directly, and increases renal phosphate reabsorption and serum phosphate levels. Recently, the new treatment option is burosumab, a monoclonal antibody which attaches to the FGF23 protein.



## AIM OF STUDY

The aim of the study was to investigate the clinical phenotype and molecular background of HR in a patient in which XLHR was suspected as well as to analyze the effects of rhGH treatment on growth.

## CASE PRESENTATION

A girl aged 13yrs and 2 months was diagnosed with HR at the age of 7 yrs and then treated with alfacalcidol (40 ng/kg/d) and phosphorus (33 mg/kg/d). Because of severe bowing of lower limbs the girl underwent several orthopedic operations. Mother of the girl is also affected. Due to the diagnosis of growth hormone deficiency (max GH after stimulation was 7.4 ng/ml; N>10) rhGH therapy was initiated at the age of 10.5 years (current dose of rhGH is 0,029 mg/kg/d)

Age [years/month]	13 4/12	Dental/peridental problems	no
Age at diagnosis [years/month]	7	Ear problems	no
Ht SDS at diagnosis/1st stay at department	-2.6	Other clinical features	no
Current /at last visit Ht SDS	-2.2	Max GH levels after stimulation Normal range > 10 ng/ml	7.4
Clinical symptoms/family interview	bowing of lower limbs, short stature, lumbar hyperlordosis AFFECTED MOTHER	Current /at last visit treatment	rhGH: 0.029 mg/kg/d Phosphorus: 33 mg/kg/d Alfacalcidol 40 ng/kg/d orthopaedic surgery of lower limbs

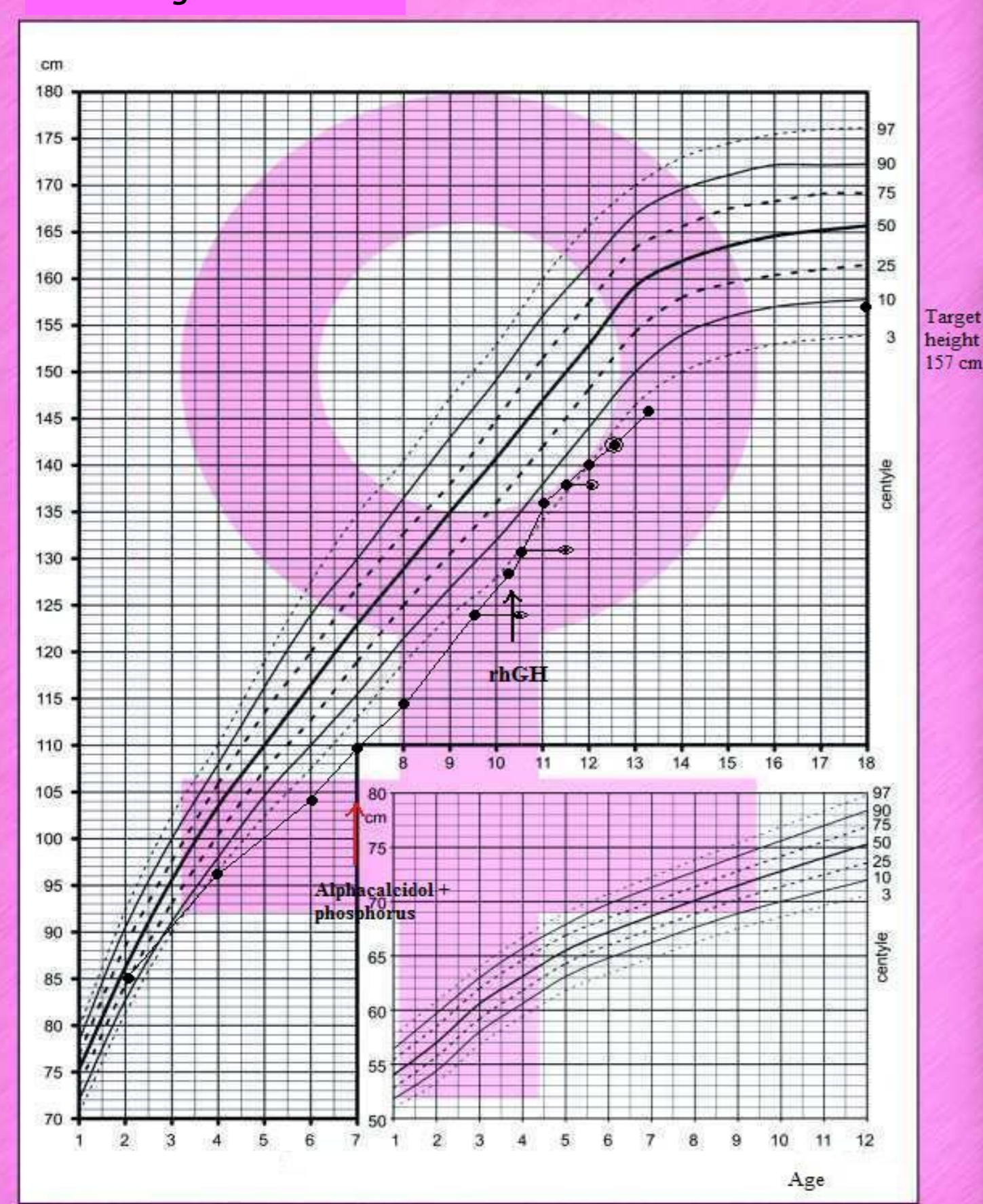
Clinical characteristics of the patient.

rhGH = human recombinant growth hormone

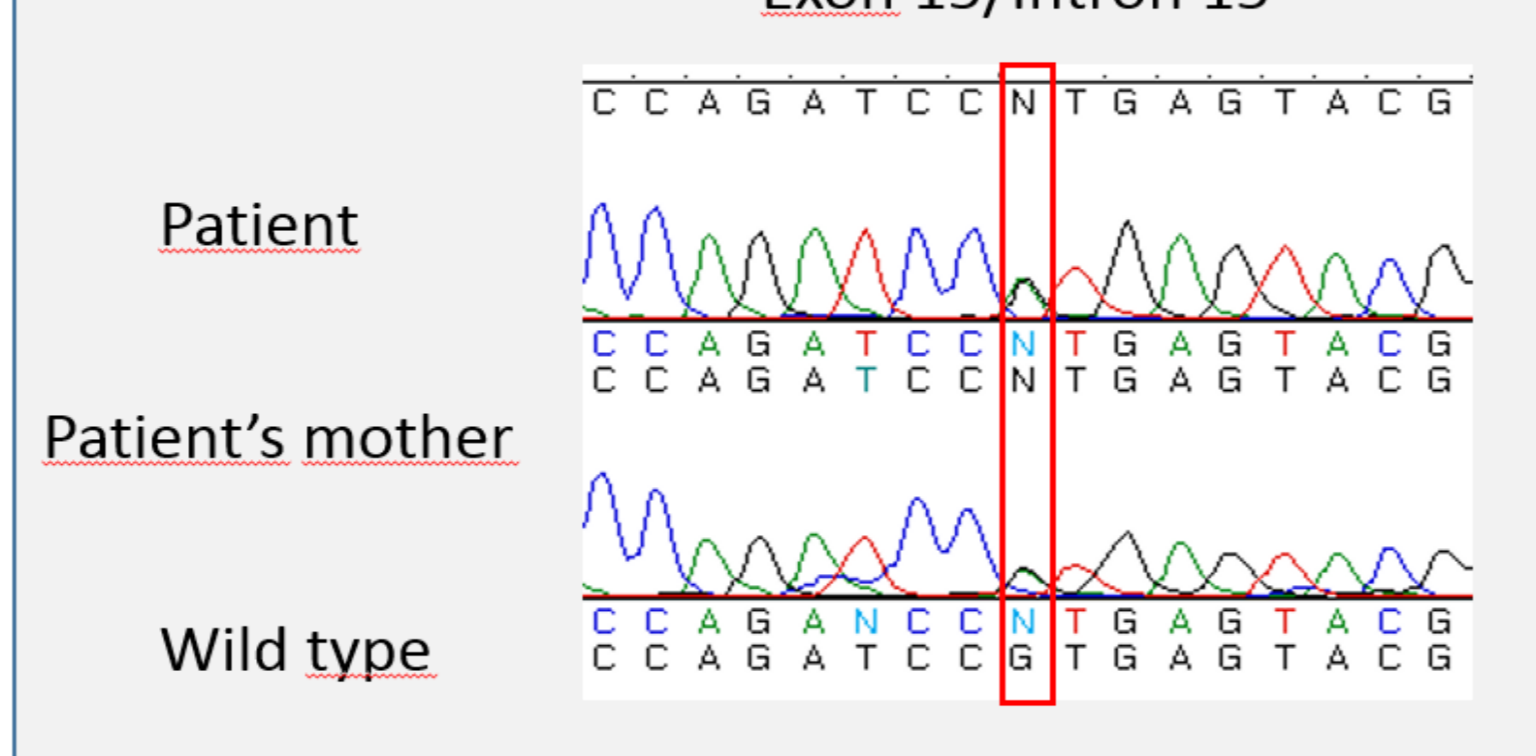
**Biochemical characteristics of the patient.** S – serum, U – urine, ALP – alkaline phosphatase, PTH – parathormone, TRP – Tubular reabsorption of phosphate. The presented laboratory results are at the time of the HR diagnosis or during the first stay at the Department of Pediatric Endocrinology and Rheumatology, Poznan University of Medical Sciences. Additionally, current concentration of ALP and TRP during pharmacologic therapy are given

S-Ca (N 2,2-2,7 mmol/l)	2,5	S-25(OH)D3 (N 9,4-59,1; opt. 30-50 ng/ml)	22,8
S-P (N 4-7 mg/dl)	↓2,89	U-Ca (N <4 mg/kg/d)	3,6
S-ALP (N 93-309 IU/L)	↑407	U-P (N16-20 mg/kg/d)	↓14.08
S-ALP Current (N 93-309 IU/L)	↑260	TRP1 % (N>80%)	96
S-PTH (N 15-68,3 pg/ml)	11,5	TRP2 % (N>80%)	↓71
		During therapy	

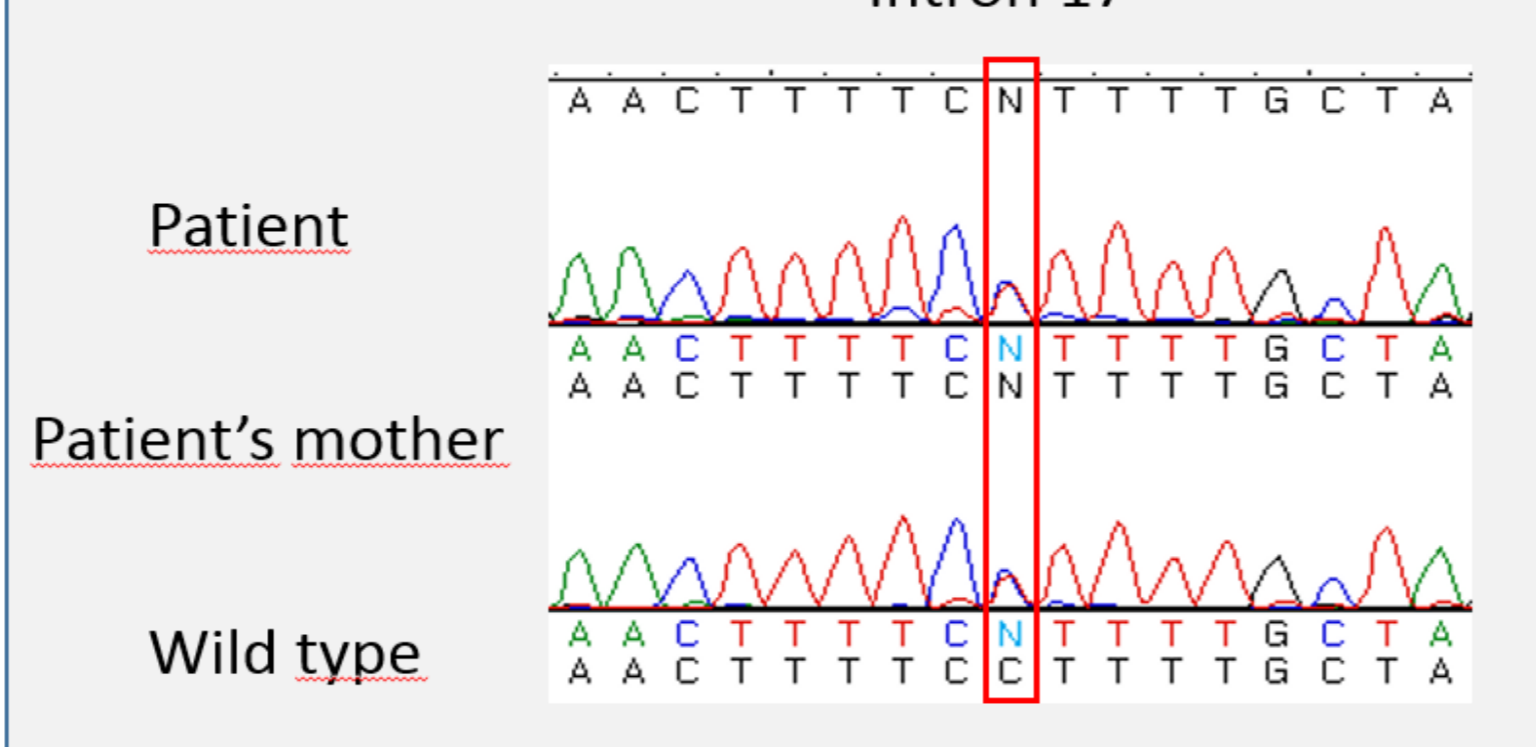
Patient's growth chart



Exon 15/Intron 15



Intron 17



## METHODS AND RESULTS

- Molecular analysis was performed using total genomic DNA isolated from whole blood. *PHEX* and *FGF23* genes were analyzed using standard PCR and direct sequencing method.
- The dominant clinical signs in a patient were bowing of legs, short stature and lumbar hyperlordosis. HtSDS at the time of diagnosis was -2.6. Current htSDS is -2.2 and the height gain during rhGH therapy was 0.4 +SD.
- Molecular analysis of *PHEX* gene revealed the presence of a known heterozygous mutation c.1645+1G>A in 5' splicing site of intron 15 (HGMD ID: CS992468) as well as a known polymorphism c.1769-10C>T (rs3752433) in intron 17.
- Both DNA changes, which may cause aberrant splicing of the *PHEX* transcript, were also found in the girl's affected mother.

## CONCLUSIONS

- Early clinical and molecular diagnosis of HR, and early implementation of vitamin D and phosphorus is crucial to prevent severe bone deformities and to improve final height.
- rhGH therapy in patients with XHLR may be very effective in those with coexisting growth hormone deficiency.
- Genetic counseling in families with HR patients should be proposed.

## References

- M. Sloman, K. Thomas, C. Tysoe, S. Ellard. Department of Molecular Genetics. A Diagnostic Testing Service for Hypophosphatemic Rickets
- Angham Al-Mutair, Rajaa A., 2017, Types of rickets. Annals of Orthopedics & Rheumatology 5(2): 1085
- Patel L., Clayton PE, Brain C., et al. 1996. Acute biochemical effects of growth hormone treatment compared with conventional treatment in familial hypophosphatemic rickets. Clin Endocrinol 44: 687-696

There is no conflict of interest.

This work was supported by funds of Department of Pediatric Endocrinology and Rheumatology of Poznan University of Medical Sciences (Nr 502-01-01104118-06037 to Marek Niedziela) and by a Research Grant of the Department of Pediatric Endocrinology and Rheumatology of Poznan University of Medical Sciences (Nr 502-1401104118-09627 to Aleksandra Rojek)

