

# Pure gonadal dysgenesis with partial testicular development associated with Turner syndrome with SRY gene

Kyung Hee Yi, MD<sup>1</sup>, EUN Young Kim, MD<sup>2</sup>, Heon-Seok Han, MD.<sup>3</sup>

1. Department of Pediatrics, Wonkwang University Sanbon Medical Center, Gunpo Korea

2. Department of Pediatrics, Chosun University School of Medicine, Gwangju, Korea

3. Department of Pediatrics, Chungbuk National University Hospital, Chungbuk National University College of Medicine, Cheongju, Korea

## Abstract

Turner syndrome is the most common chromosomal disorder in girls. They present classically short stature and delayed puberty. Turner girl with 45,X karyotype show normal female external genitalia. But Turner patients containing 45,X/46,XY mosaicism, or Sex-determining Region Y(SRY) gene may have mixed gonadal dysgenesis with various external sexual differentiation or pure gonadal dysgenesis. Existence of Y Chromosome particles in Turner syndrome implies that they have risk of gonadoblastoma. We experienced a short statured 45,X Turner girl with Normal external genitalia. Because SRY gene was positive, laparoscopic gonadectomy was performed. The dysgenetic gonads revealed bilateral Gonadectomy tissues. The authors report a pure gonadal dysgenesis with partial testicular development associated with Turner syndrome with SRY gene. Screening for SRY gene should be done even though Turner patient have the 45, X monosomy and no evidence of virilization.

## Case report

10 year and 3 months-old girl was brought to endocrine clinic for short stature. She was delivered uneventfully at 40 weeks of gestation with 3.2 kg. On exam, her height was 116 cm (<3percentile), body weight was 19.3 kg, Breast development was prepubertal. She had neither cubitus valgus deformity nor webbed neck. Knuckle sign was negative. Multiple freckles were found at back area. Audiometry, echocardiography, kidney ultrasonography were all normal. Her karyotyping revealed 45,X. After diagnosis of Turner syndrome, growth hormone had been given for the treatment of short stature, and estradiol replacement was started at 12.7 years of age. Because SRY gene was positive, she was scheduled to perform laparoscopic gonadectomy at 14 years of age. On pelvic laparoscopy, the uterus and both fallopian tubes looked normal, but both gonads looked streak in appearance (Fig. 1). Both adnexa were removed. On pathologic exam, salpinx was observed with dysgenetic gonad (Fig. 2). The dysgenetic gonad had stroma of whirling pattern with primordial follicles resembling ovarian stroma (Fig. 2A) and clusters of Leydig cells with ill-defined boundary (Fig. 2B). Vas deferences were as tubular structures surrounded by fibromuscular stroma in certain part of stroma (Fig. 3), and seminiferous tubules were found with surrounding tunica albugina (Fig. 4A). Sertoli cells and spermatogonia were seen in the seminiferous tubules without spermatogenesis (Fig. 4B). On the other side of adnexa, dysgenetic ovarian stroma with whirling pattern, vas deference, and Leydig cell cluster were also observed. Pathologic findings were compatible to pure gonadal dysgenesis with partial testicular development.

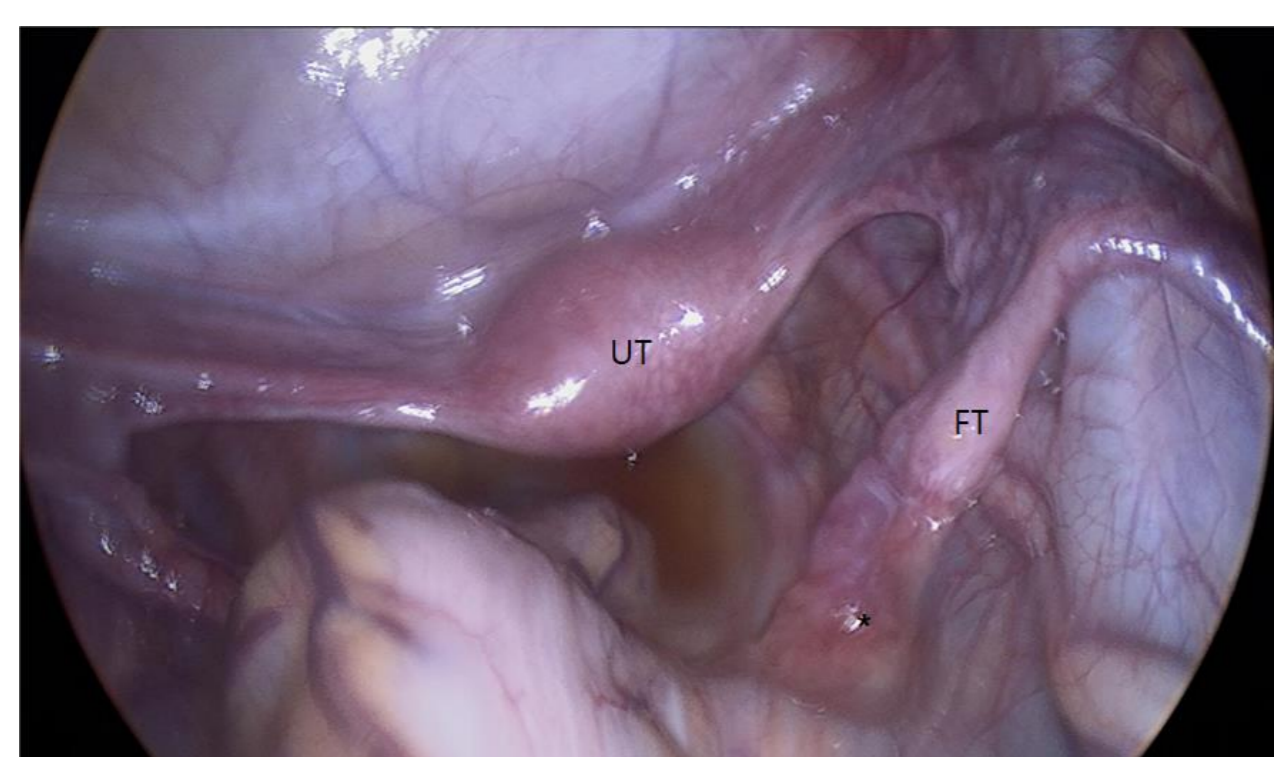


Fig. 1. Laparoscopic view of normal uterus (UT), both fallopian tubes (FT), and streak gonad (\*).

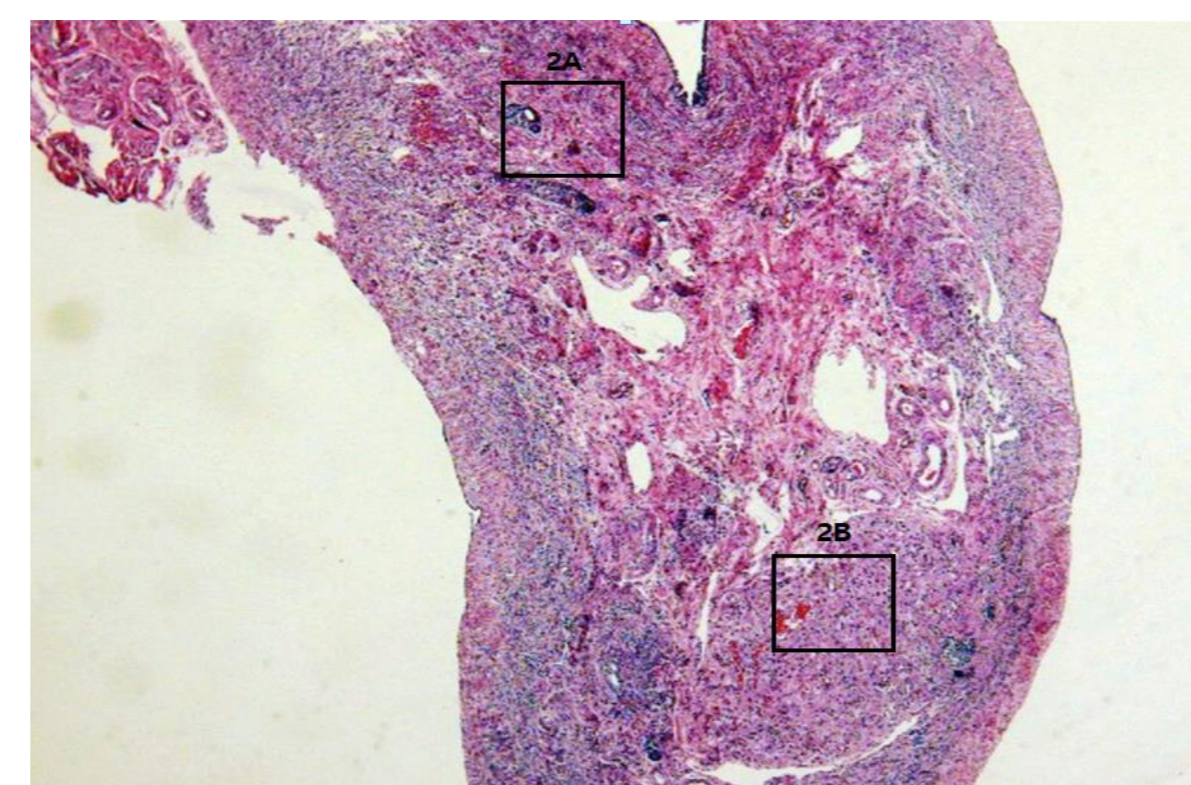


Fig. 2. Low power microscopic view of right sided solid gonad with primordial follicle with whirling pattern of stroma (A), and Leydig cell cluster of acidophilic cytoplasm with ill-defined border (B).

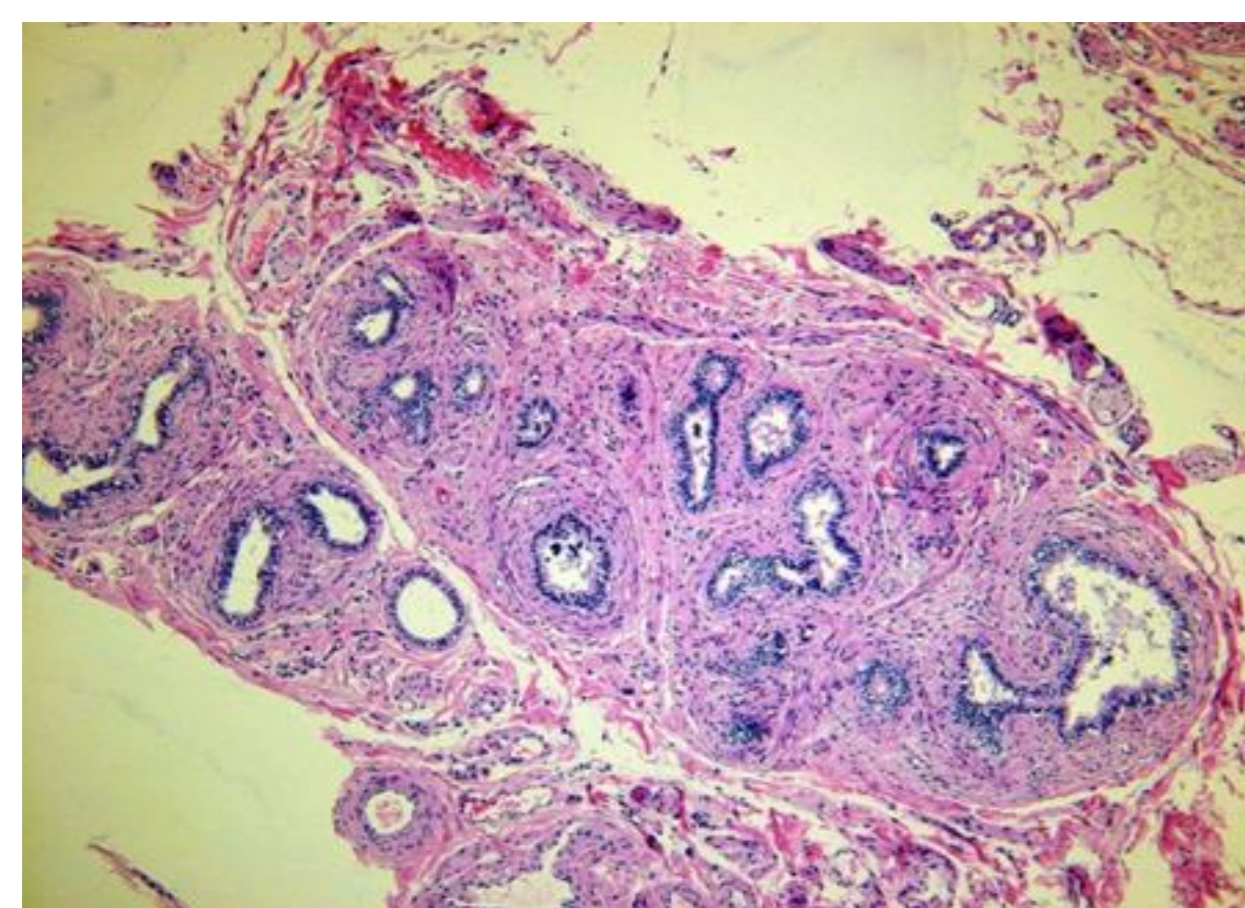


Fig. 3(left). One part of dysgenetic gonad, tubular structure surrounded by thick fibromuscular stroma was confirmed to be vas deference consisting of simple cuboidal cells

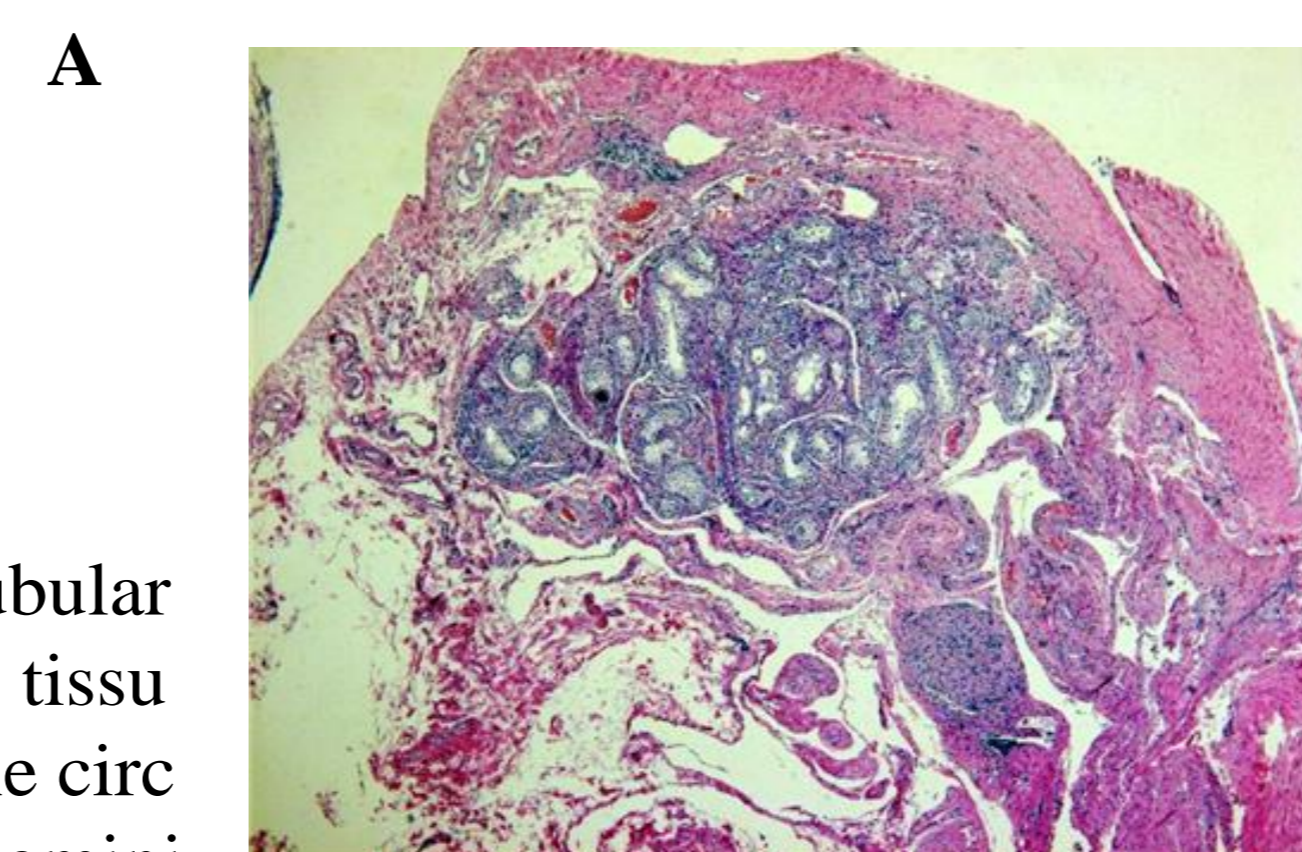
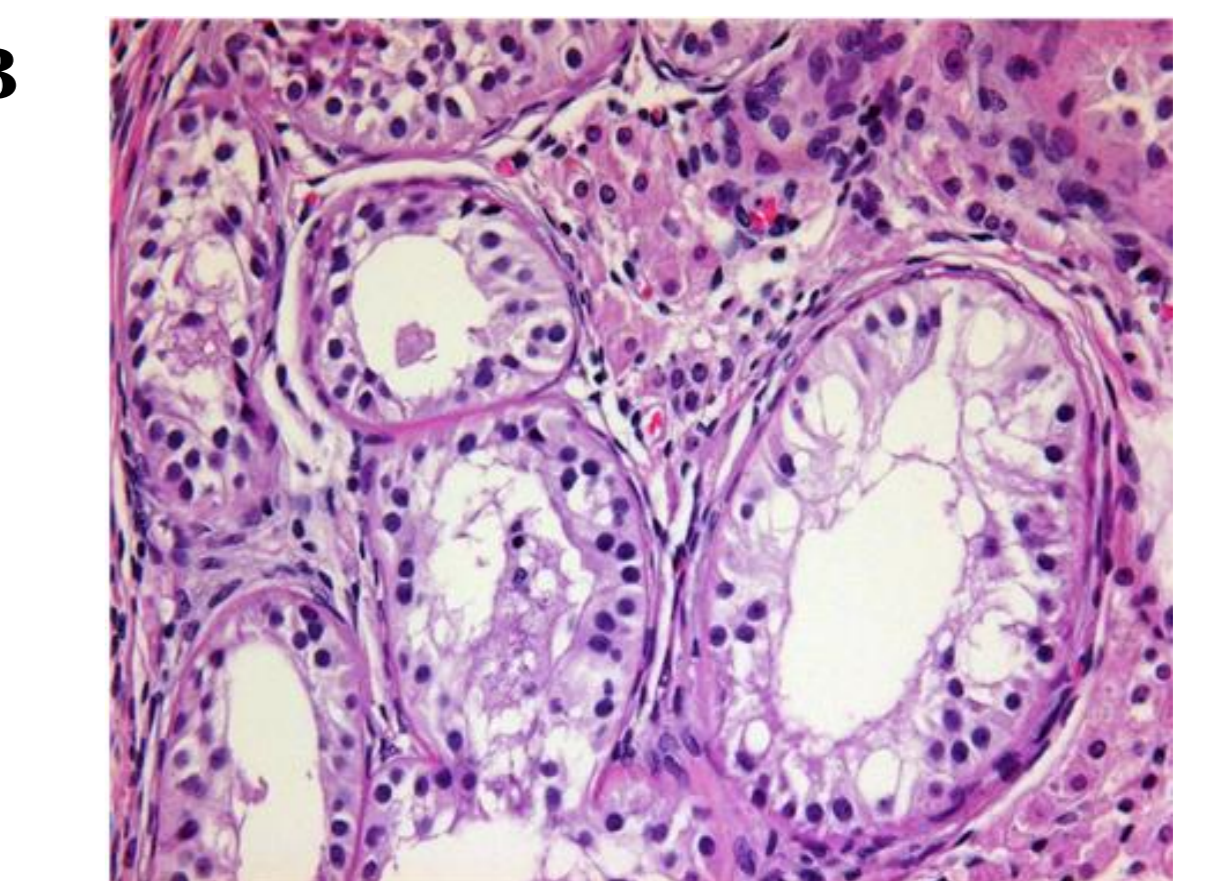


Fig. 4(right). The other part of dysgenetic gonad, tubular structures were seen with surrounding thick fibrous tissue (\*), tunica albugina (A). In high power view of the circle, tubular structures were confirmed to be typical seminiferous tubules with intermingling Leydig cells (B).



## Conclusion

This case is genetically Turner syndrome with karyotype of 45,X, but pathologically pure gonadal dysgenesis with partial testicular development. The positive SRY gene is an evidence of unrecognized Y material which was not found in karyotyping. Usually, 45,X Turner syndrome had streaky gonad or immature ovary. But our patient showed combination of ovarian tissue including primordial follicles and testicular tissue with spermatogonia and seminiferous tubules. This form of gonadal dysgenesis is typically observed in a mosaic 45,X/46,XY karyotype a form of mixed gonadal dysgenesis. Although our patient did not have Y chromosome, but we could find SRY gene. On pathologic exam, both gonadal dysgenesis were observed with incomplete testicular development unlike mixed gonadal dysgenesis. Generally, 45,X Turner syndrome with no genital ambiguity are, not believed to be at risk for gonadoblastoma. Because ovaries of these patients rapidly degenerate into fibrous streaks with loss of oogonial germ cells. All the clinical experience with gonadoblastoma/dysgerminoma in girls with Turner Syndrome derives from cases where the karyotype included visible Y chromosome material or the patient had clinical evidence of virilization, hence the recommendation for gonadectomy was applied only to individuals with visible Y chromosome material or virilization. But several studies reported that gonadoblastoma occurred in patients with 45,X karyotype. In conclusion, the detection of SRY gene in Turner syndrome is necessary to prevent the development of tumoral or nontumoral gonadal lesion, even if karyotyping using peripheral blood lymphocyte do not detect Y chromosome material.