

McCune Albright Syndrome: Two cases with different clinical courses.

Agim Gjikopulli¹, Marjeta Tanka², Laurant Kollcaku¹, Aferdita Tako³, Sonila Tomori³, Paskal Cullufi³

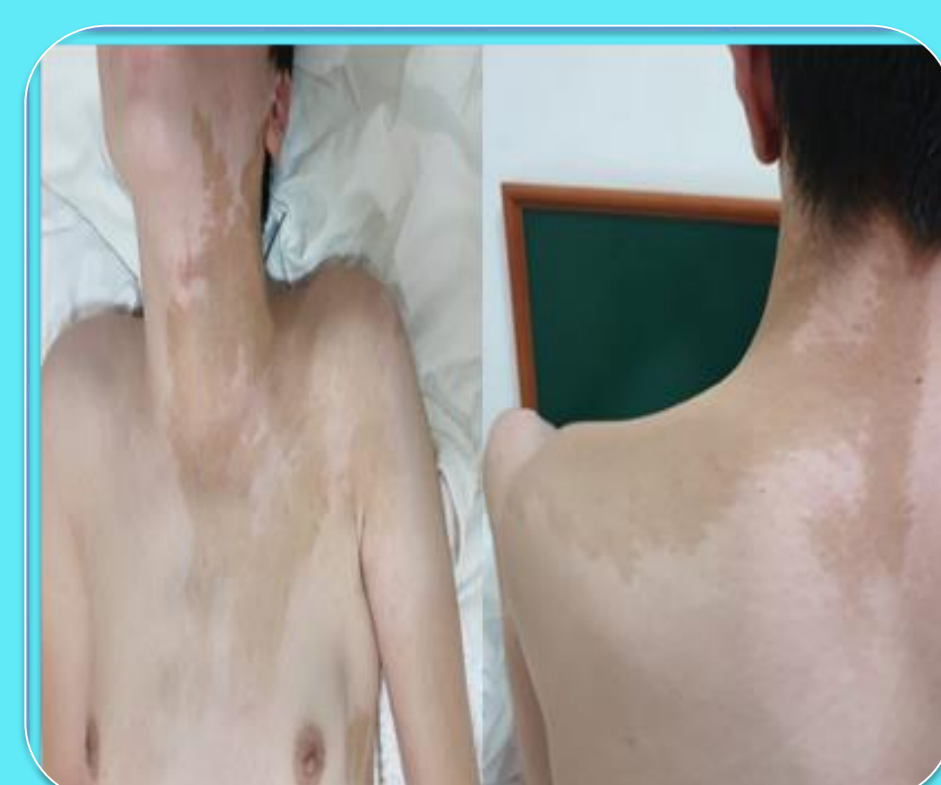1. Pediatric Endocrinology Unit, Department of Pediatric, University Hospital Center "Mother Teresa", Albania

2. Radiology and Imaging Department, University Hospital Centre "Mother Teresa", Albania

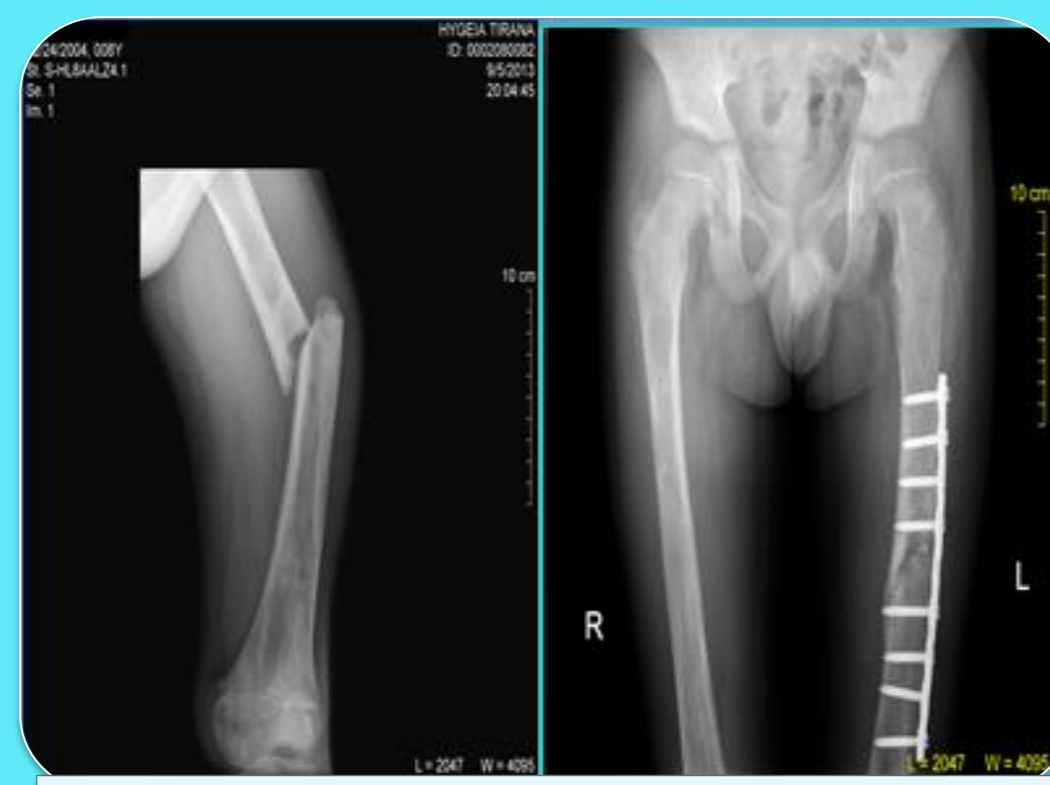3. Pediatric Specialty Service Nr.2, Department of Pediatric, University Hospital Centre "Mother Teresa", Albania

Introduction

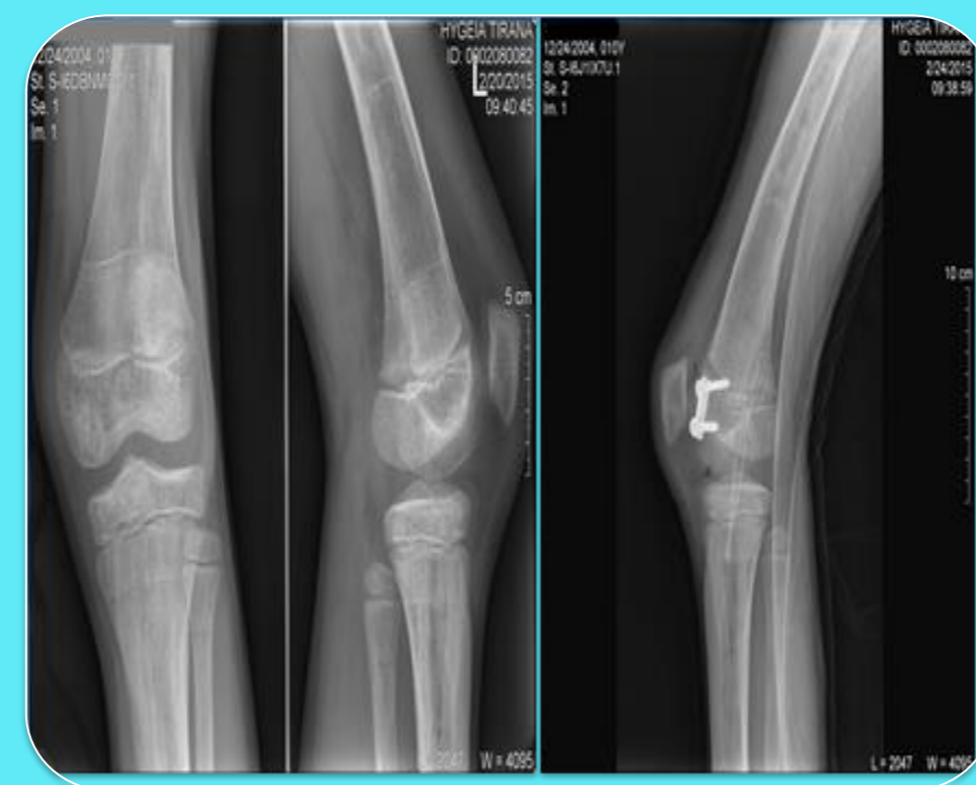McCune-Albright syndrome consists of pigmented skin patches, polyostotic fibrous dysplasia, and a variety of endocrine disorders. Café au lait spots are characteristic skin lesions that reflect the onset of the somatic mutations in melanocytes during embryonic development. Polyostotic fibrous dysplasia is caused by activation of the parathyroid hormone receptor pathway in bone. Hormonal hypersecretion is the result of constitutive cyclic AMP production caused by inactivation of the GTP-ase activity of $G_{s\alpha}$. The $G_{s\alpha}$ mutations occur postzygotically, leading to a mosaic pattern of mutant expression. McCune-Albright syndrome affects males and females equally. The disorder is estimated to affect 1 in 100,000 to 1 in 1,000,000 individuals in the general population. Because the disorder is difficult to diagnose, affected individuals may go undiagnosed or misdiagnosed, making it difficult to determine the true frequency of MAS in the general population. MAS was previously determined as a condition that had three clinical features, such as café au lait spots, fibrous dysplasia, and hyperfunction of an endocrine gland. This syndrome recently consists of at least two of the signs and symptoms mentioned above.



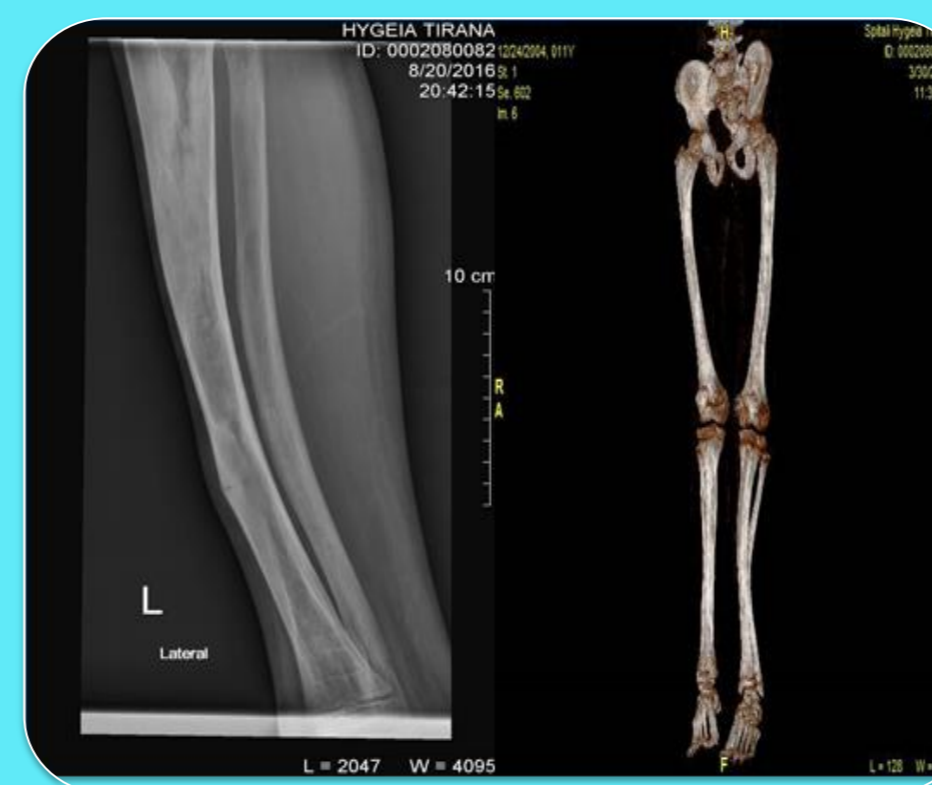Café au lait spots



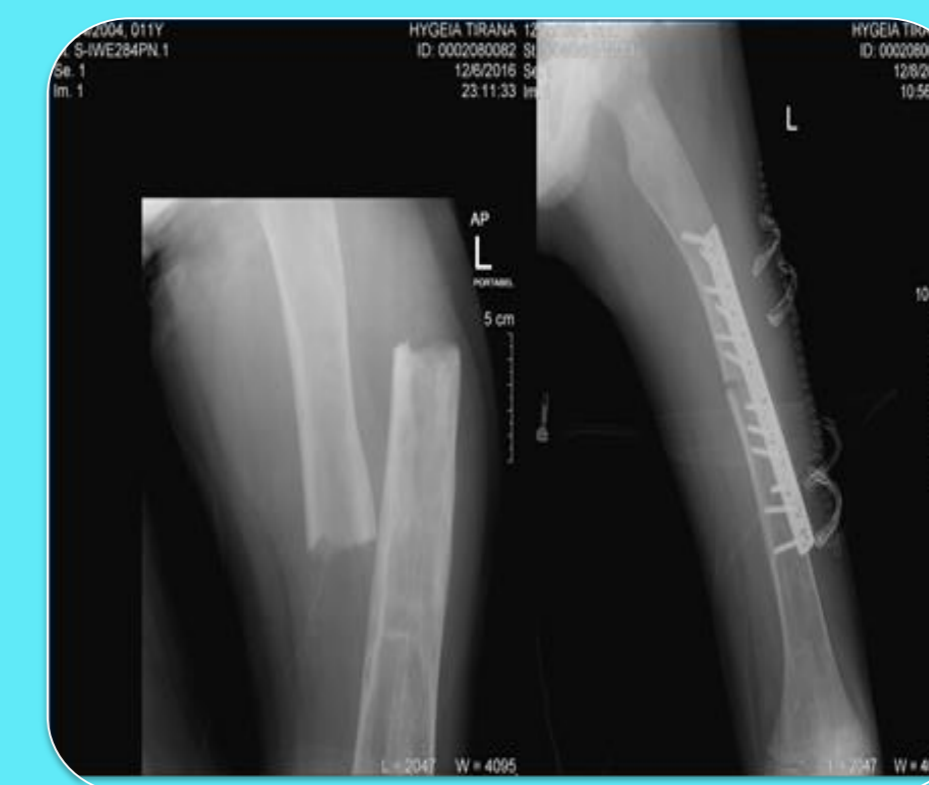Fracture of left hip on 05-Sep-2013 (before and after surgery).



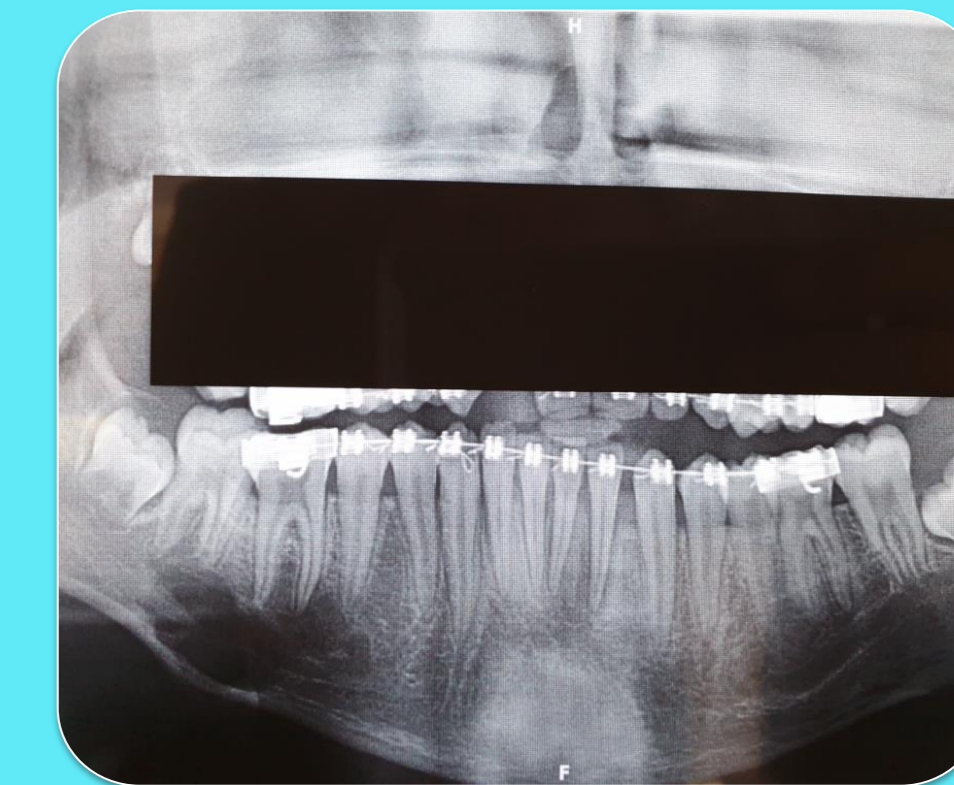
Fracture of left hip on 02-Feb-2015 (before and after surgery).



Bowing of left ulna and fibula (30-Mar-2016).

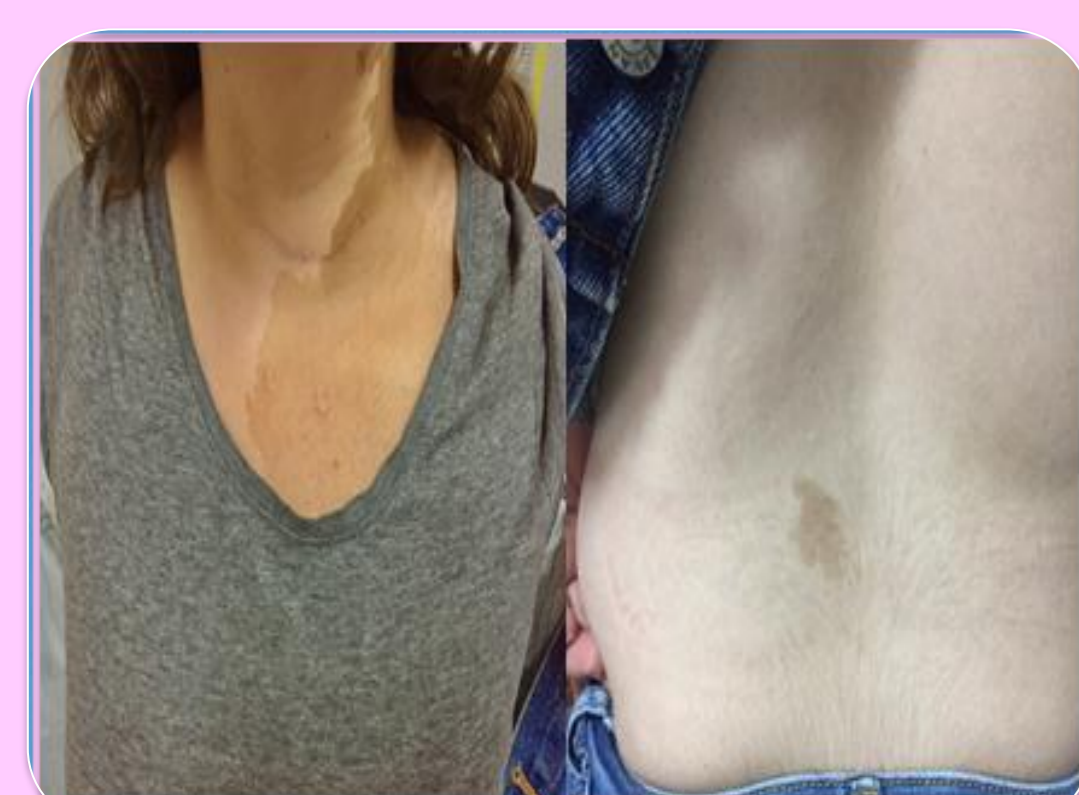

Fracture of left hip on 07-Dec-2016 (before and after surgery).

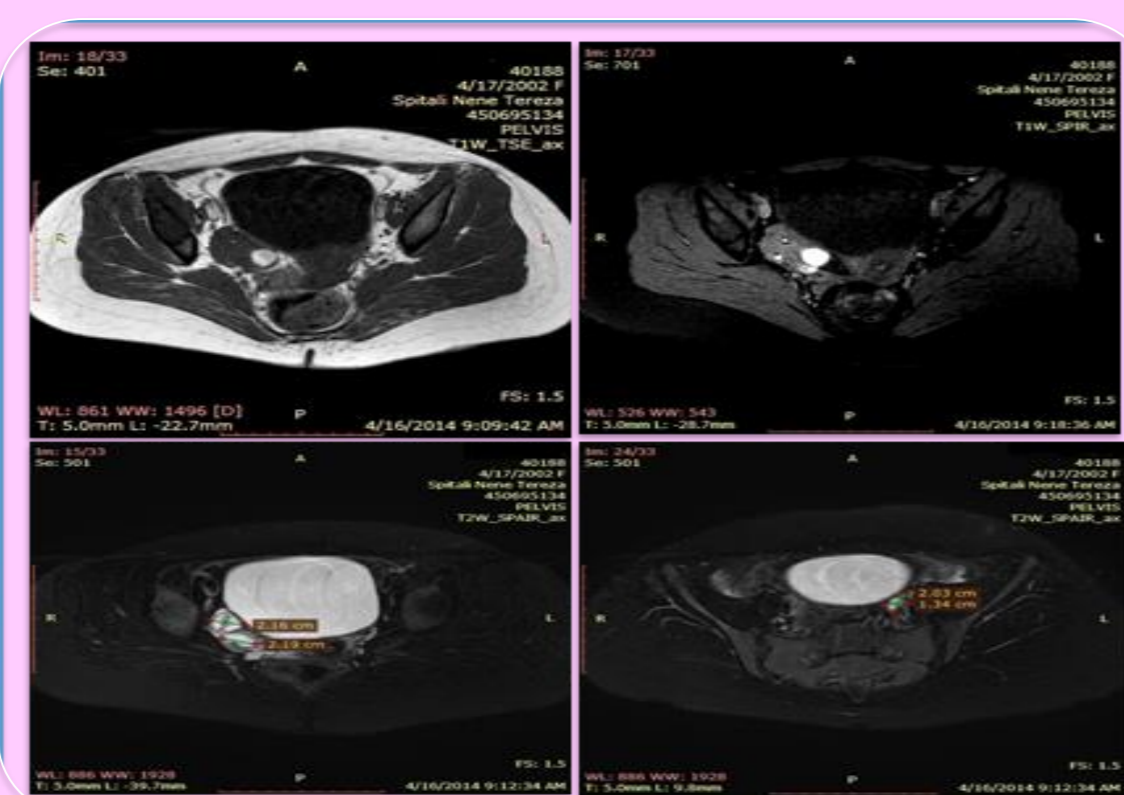

Forming mandibular osseal cyst. (20-Dec-2018).

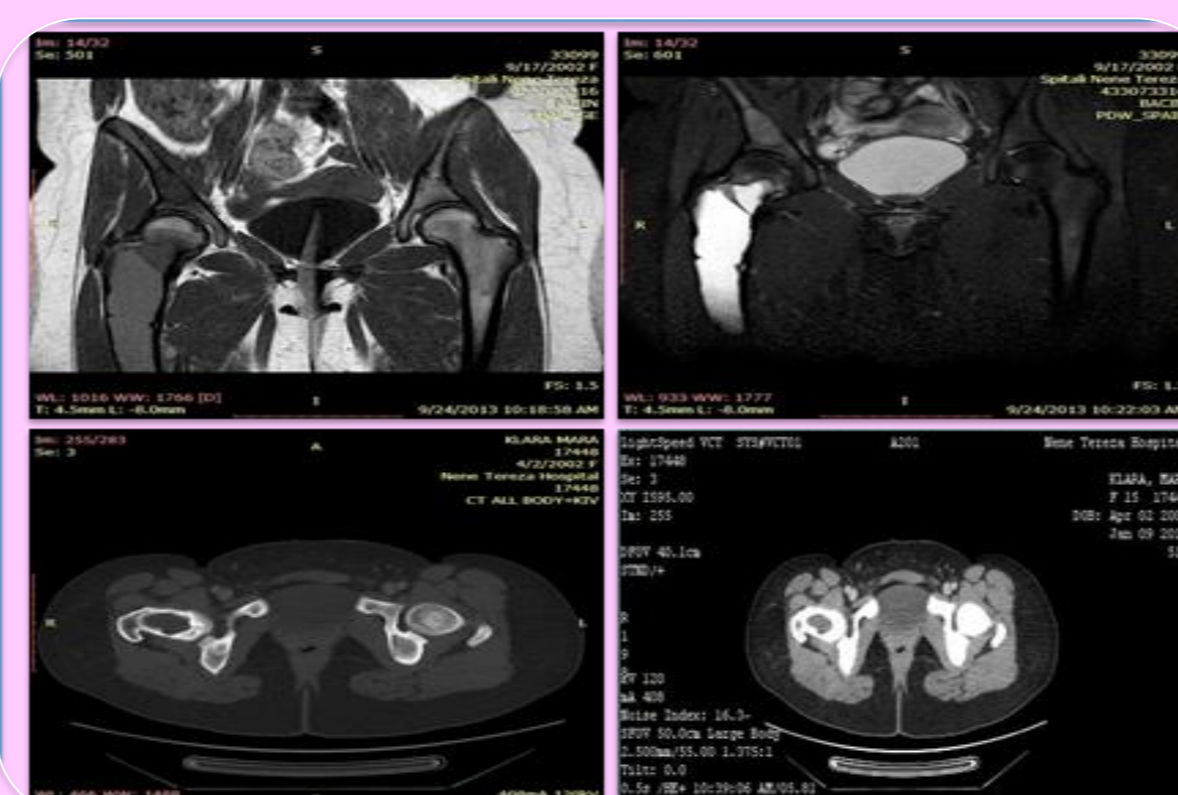Case 1. Male, was born on 2004. 11 years without diagnosis. 12 years old was diagnosed with MAS (2016). 12 years old started treatment with Pamidronate 6mg/kg/year every 3 months. Actually continuing treatment with Pamidronate and physiotherapy.. No other fractures.



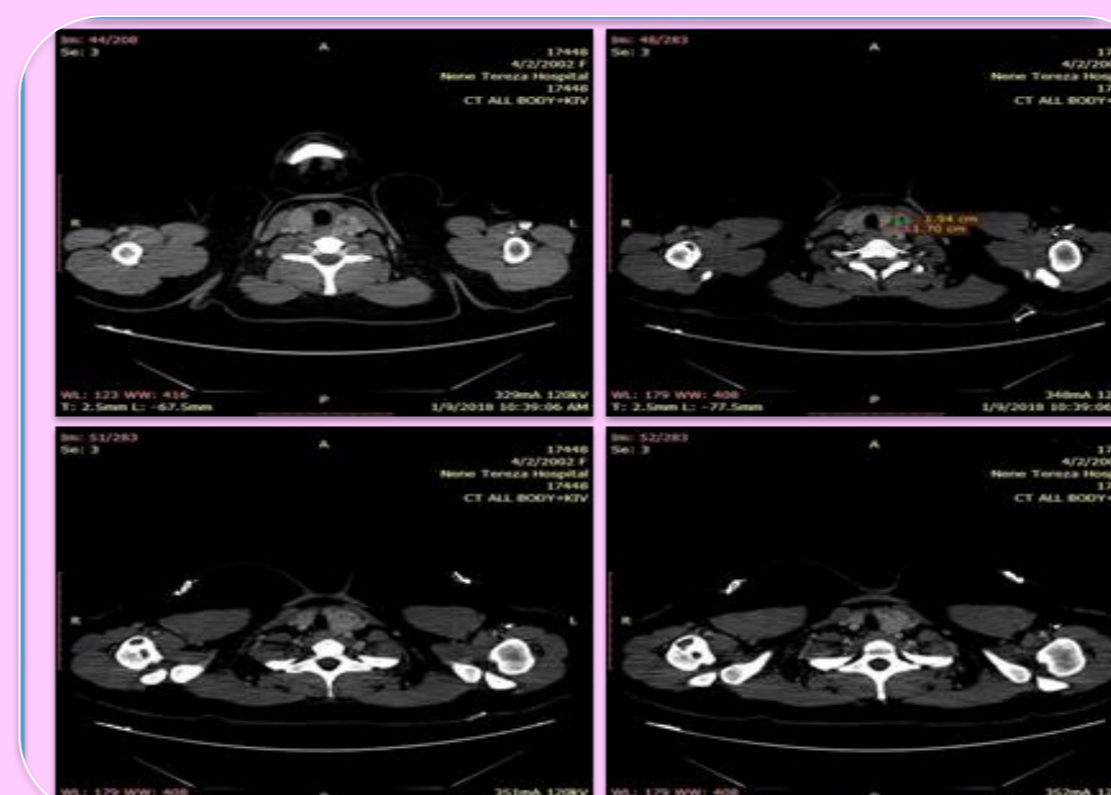
Café au lait spots



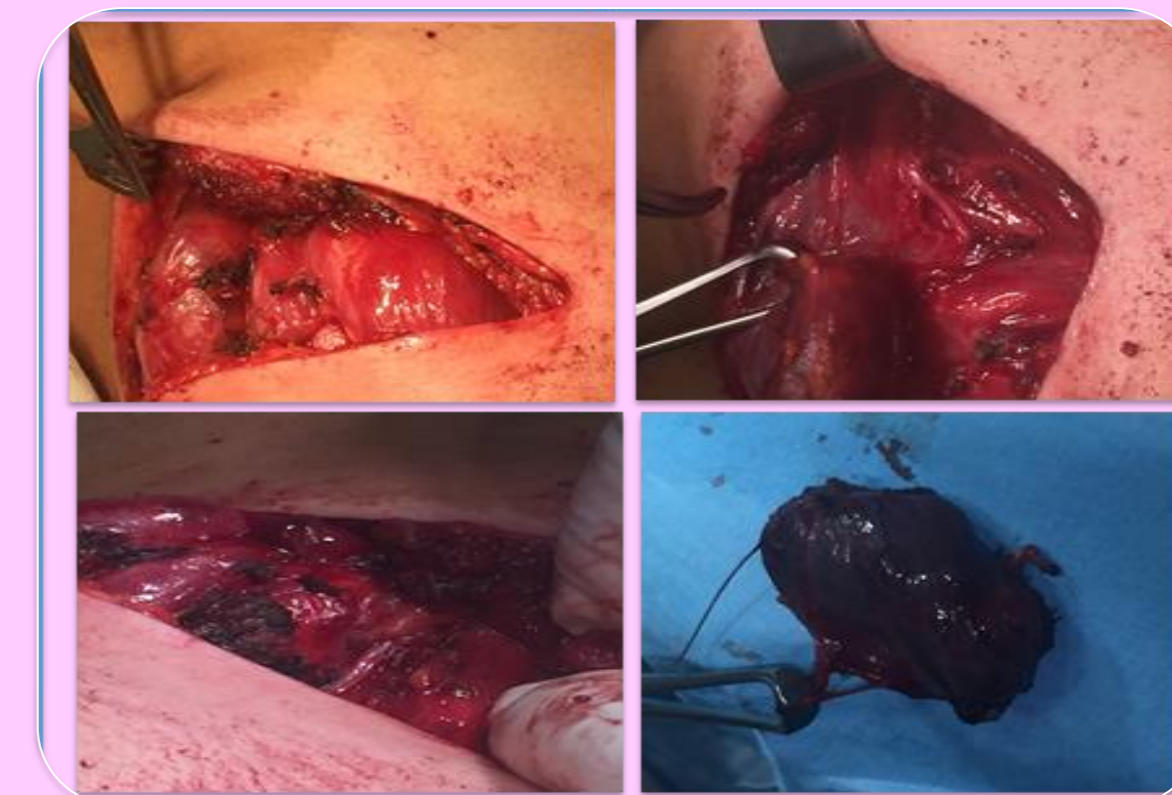
Ovarian cysts. Some of them were hemorrhagic.



Fibrous dysplasia of the head of left femoris and diaphysis of left femoris.



Multinodular Goiter, especially the left lobe. Hyperthyroidism.



High suspicion for papillary carcinomas. Total thyroidectomy.

Case 2. Female, was born on 2002. 4 months she experienced metrorrhagia for the first time, which was repeated at age 8 months (age of diagnosis with MAS). Puberty was independent of gonadotropin. 8 months old she started treatment with Decapeptyl 3.75mg every 28 days until 12 years old. 8.5 years old she started treatment with Pamidronate until 11 years old. 11 years old was diagnosed with thyroid's hyperfunction and started treatment with Methimazole.. 15 years old she went under surgery, for total thyroidectomy.

Discussion

The skin, bone and endocrine system are the most commonly body's parts affected by MAS. We are presenting two different clinical cases with MAS. It is important to note that affected individuals may not have the same symptoms and that every individual case is unique. Both our cases have café au lait spots in the skin since they born. The case_1 (boy), develops Fibrous dysplasia (FD), but not the other characteristic symptoms of MAS. FD may affect multiple bones throughout the body (polyostotic disease) as in the case_1 or may affect only one solitary bone (monostotic disease) as in the case_2. A few years later, the long bones may become bowed, as in the case_1. He was treated with Pamidronate every 3 months for 3 years and he had not had any other fracture till now. Precocious puberty is more common in females than in males (more than 50% of females experience precocious puberty, as in the case_2). She experienced an early onset of puberty (gonadotropin independent precocious puberty) which was associated with the development of ovarian cysts (unilateral in case_2). The case_2 expresses clinical symptoms of enlargement of the thyroid gland (multinodular goiter) and overproduction of thyroid hormone (hyperthyroidism). Although rarely (less than 1% of patients are reported in the literature), these lesions in the thyroid gland may become malignant. She was treated with Methimazole for about 3 years until remission was achieved. Due to high suspicion of thyroid malignancy, she underwent surgery for total thyroidectomy and now she's under treatment with Levothyroxine.

Conclusions

We reported two cases with MAS to emphasize that all patients with pigmented skin patches should be evaluated for other manifestations in order to exclude MAS. Our cases supports the statement that only two of clinical characteristics mentioned above (pigmented skin patches, fibrous dysplasia, and varieties of endocrine disorders), are sufficient to be present to consider MAS.

Bibliography

1. Paul SM, Gabor LR, Rudzinski S, et al. Disease severity and functional factors associated with walking performance in polyostotic fibrous dysplasia. *Bone*. 2014;60:41-47. <http://www.ncbi.nlm.nih.gov/pubmed/24316419>
2. Collins MT, Singer FR, Eugster E. McCune-Albright syndrome and the extraskeletal manifestations of fibrous dysplasia. *Orphanet J Rare Dis*. 2012;7 Suppl 1:S4. <http://www.ncbi.nlm.nih.gov/pubmed/22640971>
3. Zacharin M. The spectrum of McCune-Albright syndrome. *Pediatr Endocrinol Rev*. 2007;4 Suppl 4:412-418. <http://www.ncbi.nlm.nih.gov/pubmed/17982388>
4. McCune-Albright Syndrome: <https://emedicine.medscape.com>. McCune-Albright Syndrome Updated: Jan 17, 2019 Author: Gabriel I Uwaifo, MD; Chief Editor: George T Griffing, MD
5. Dumitrescu CE, Collins MT. McCune-Albright Syndrome. *Orphanet J Rare Dis*. 2008;3:12. <http://www.ajrd.com/content/3/1/12>