



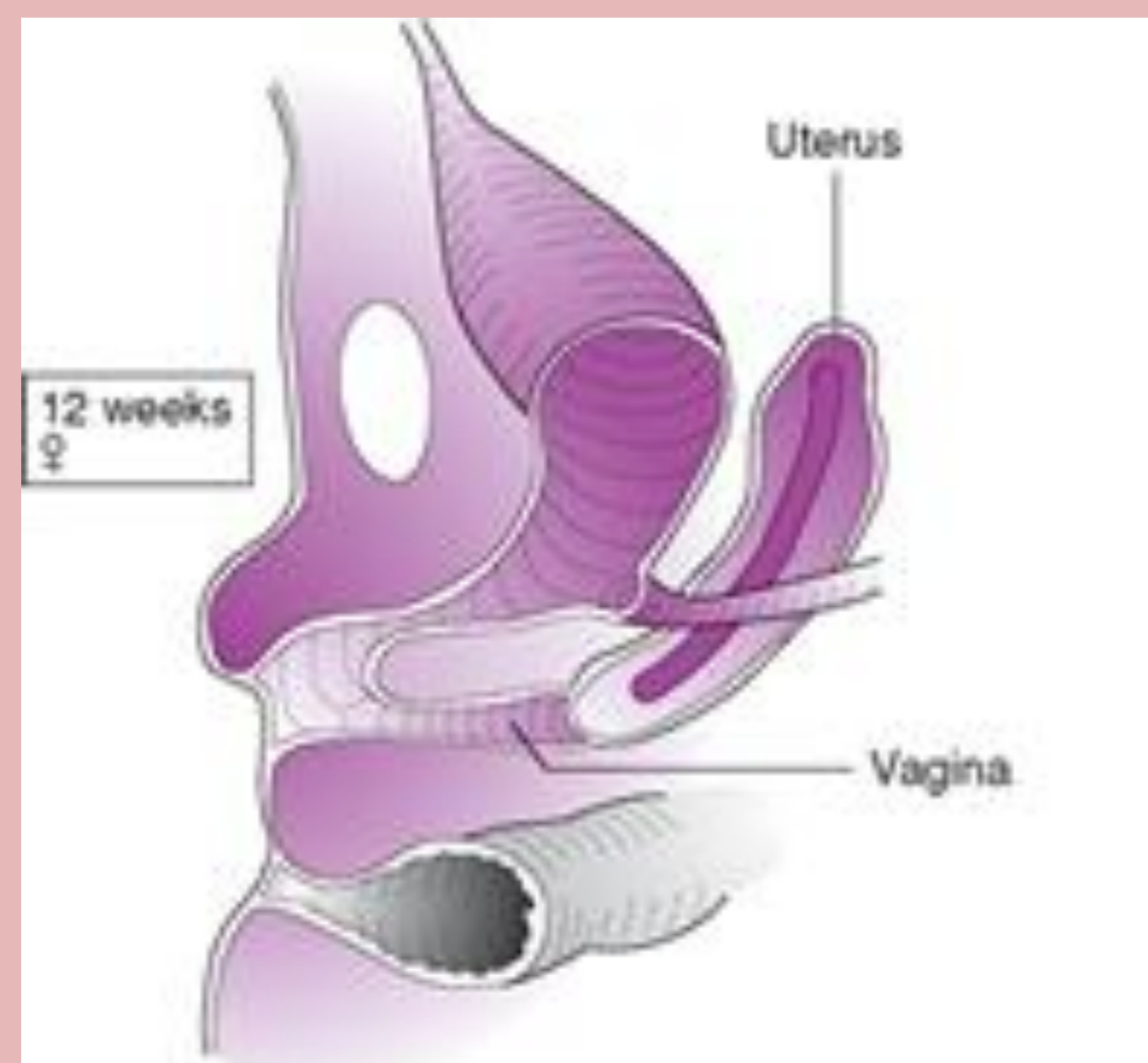
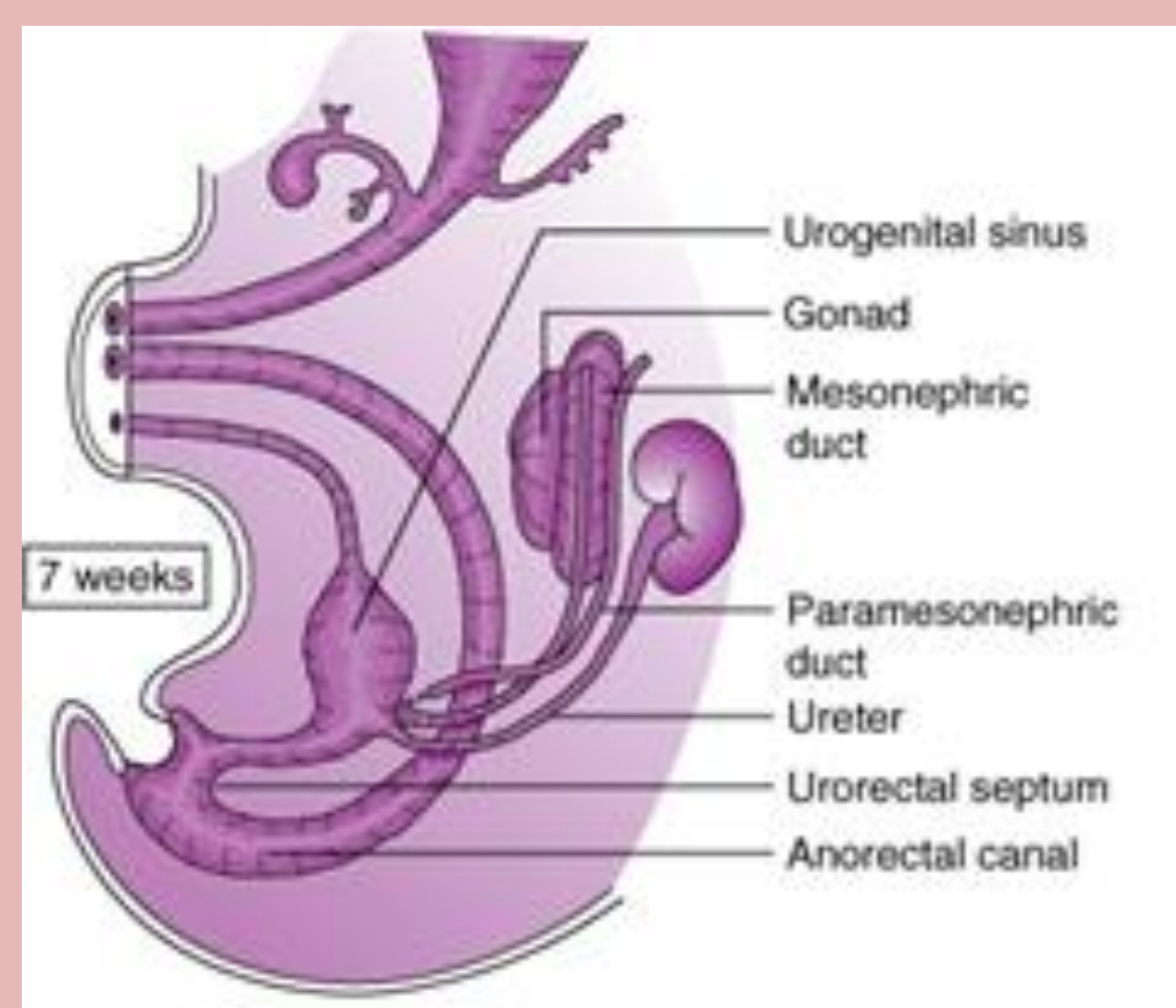
Hydrometrocolpos due to congenital adrenal hyperplasia (CAH)—A rare cause of bladder outflow tract obstruction in a female child

Suntharesan J1, Atapattu N1, Prematilake GLDC1, Hashim FR1, Gunasekara BP1, De silva UAMD1
1Endocrine and Diabetes Unit, Lady Ridgeway Hospital for Children, Colombo, Sri Lanka.



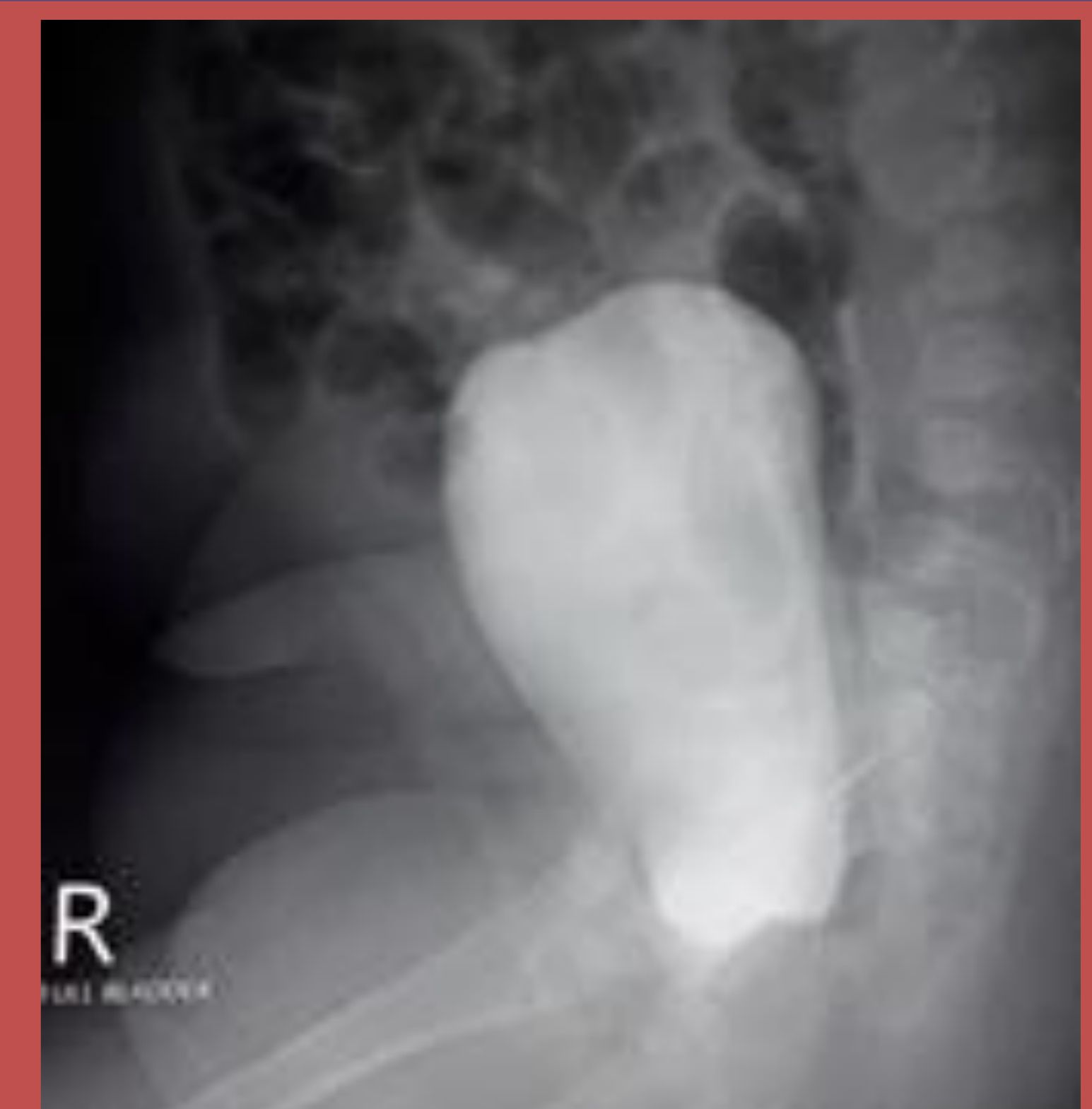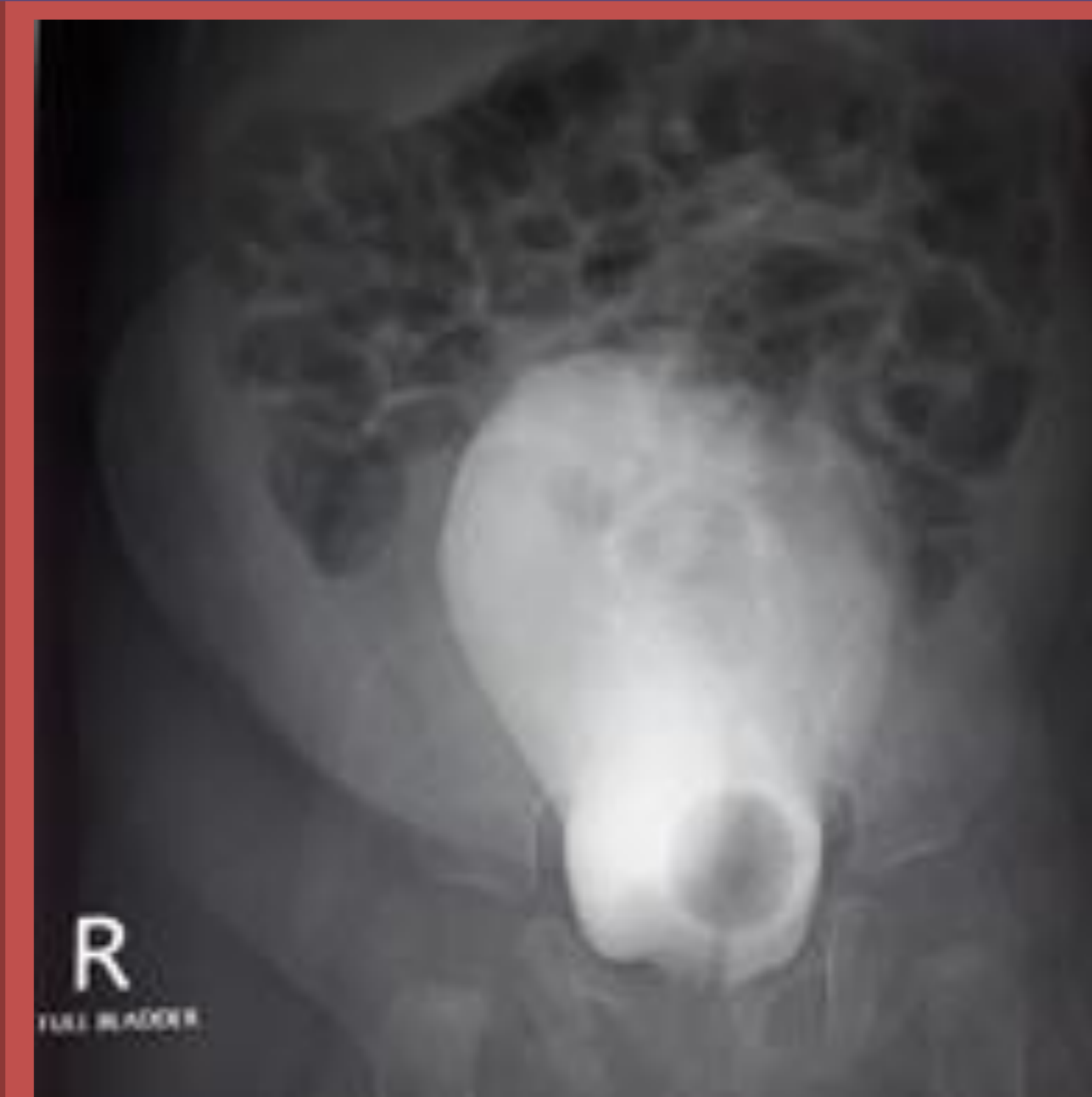Introduction

- Hydrometrocolpos (HMC) develops in a female child as a result of a vaginal outflow tract obstruction and accumulation of secretions
- Incidence of classic CAH is 1:14,000 to 1:18,000 births.
- 21 hydroxylase deficiency accounts for 95% of CAH
- Androgen exposure before 12 weeks of gestation leads to, labial fusion and persistent urogenital sinus (PUGS).
- Accumulation of bladder and vaginal contents in the common channel leads to pressure effect which can lead to bladder outflow obstruction (BOO) and varying degree of hydronephrosis



Imaging

- Ultra sound (US)
- Distended bladder and bilateral severe hydronephrosis
- Well define cystic area, posterior to the bladder suggestive of hydrometrocolpos possibly due to PUGS.
- Normal internal Female genitalia.
- MCUG
- Contrast filling was noted into a cavity
- No evidence of fistulous tract extending from the cavity



Case Report

- A term infant presented with abdominal distension and clitoromegaly.
- Examination, no palpable gonads and had single perineal opening with bilateral ballotable masses.

Management

- BOO and bilateral sever hydronephrosis lead to hypertension, which needed vesicostomy .
- Later vesicostomy was reversed and had normal urinary flow from the urethra.
- Treatment with hydrocortisone and fludrocrtisone was commenced.
- Awaiting for correction of PUGS and genitoplasty.

Investigation

Karyotyping - 46,XX
17 hydroxy progesteron > 60nmol/l

Conclusion

- This case highlights the varying degree of urogenital abnormality caused in CAH.
- Multidisciplinary care is needed for patient with androgenital syndrome in CAH.

Diagnosis

Virilized female due to congenital adrenal hyperplasi with PUGS