

Precocious puberty and primary hypothyroidism in a 6 years and 10 months girl with pituitary macro adenoma and dextral ovarian cyst

Ratna Dewi Artati, Merry Faridah Sabir

Department of Paediatrics, Medical Faculty University of Hasanuddin/ Dr Wahidin Sudirohusodo Hospital, Makassar, Indonesia

Background

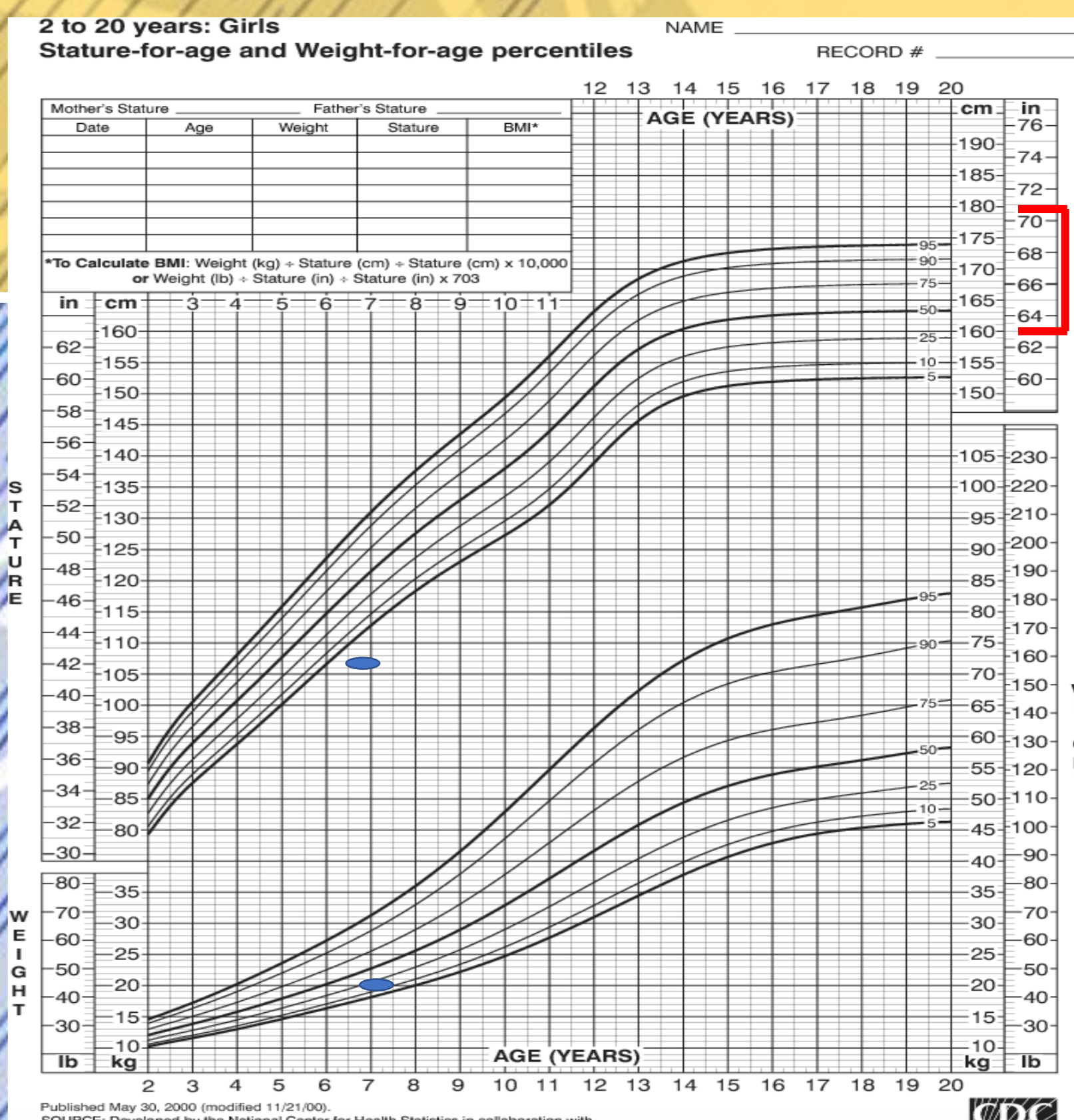
Precocious puberty associated with profound hypothyroidism is a rare condition. It is usually characterized by breast development, vaginal bleeding, and lack of pubic hair. Multi cystic ovaries in profound hypothyroidism patients with precocious puberty have been rarely described.

Objective

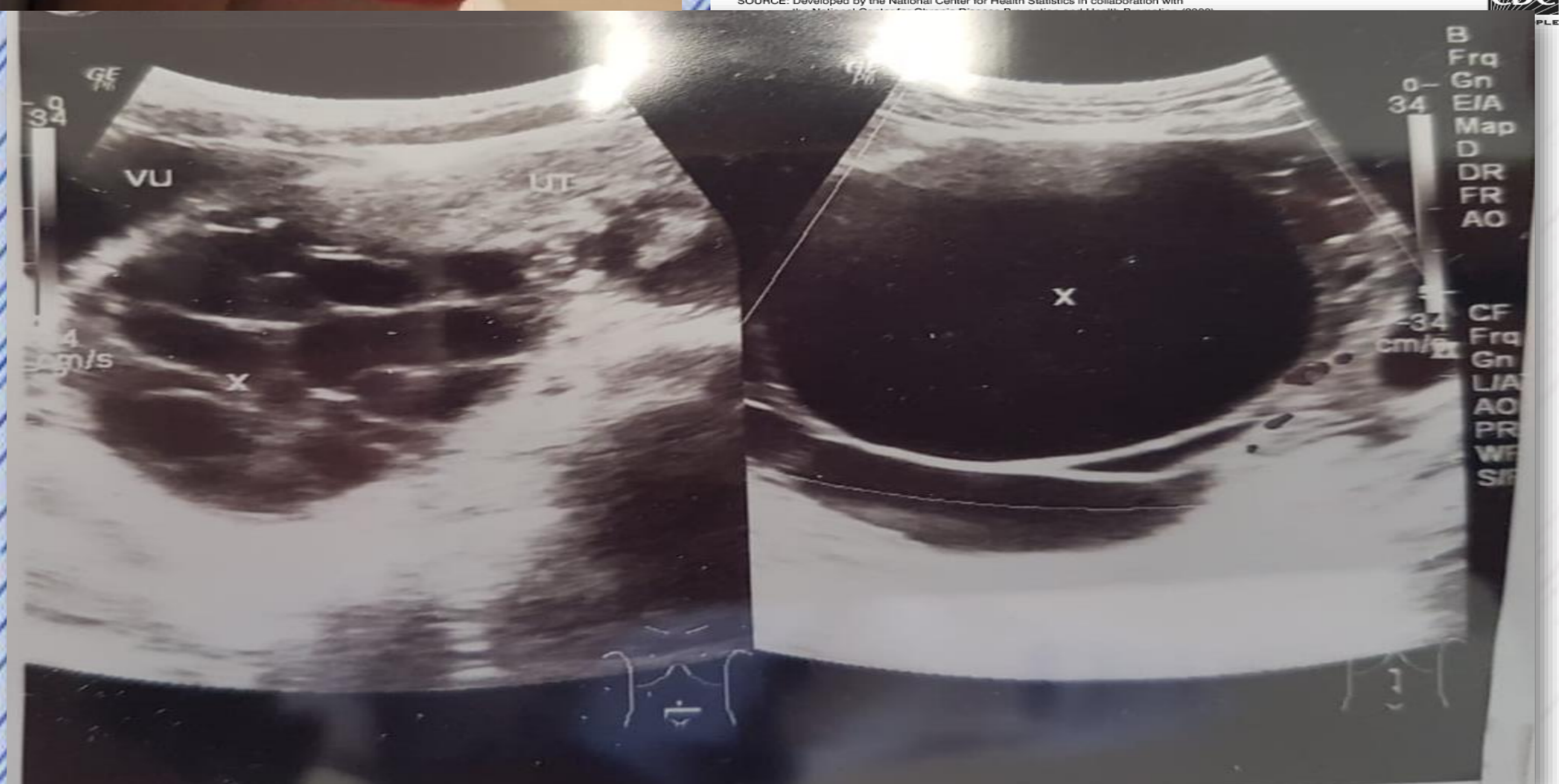To report a case of Precocious puberty and primary hypothyroidism in a 6 years and 10 months girl with pituitary macro adenoma and dextral ovarian cyst.

Case Presentation Summary

A 6 year and 10 month old girl was referred to Wahidin Hospital with precocious puberty. The girl was admitted with vaginal bleeding as the main complaint. Vaginal bleeding occurred since 6 months before with 3-4 days cycle. Breast enlargement and hairy axillary since a year before. Her mother had menarche at 14 years old. There was consanguinity of her both parents. On physical examination: pigmented hairy axillary, breast budding, no pubic hair. Body weight 20 kg, height 108 cm. Genetic height potential 142,5 cm - 159,5 cm (CDC NCHS 2000). Laboratory: hemoglobin 8,4 g/dl, perifer blood smear disomorphyc anemia from Fe deficiency with differential diagnosis chronic illness. Low LH but FSH and estradiol elevated. Low FT4 (0.22 ng/dL), T3 (total)(<0.4 ng/mL) and T4 (total) (1.24 μ g/dL) with high TSHS (2,738uIU/mL) and prolactin (255,3 bg.mL). Tumor marker : AFP, CEA and Beta HCG normal with light elevation in Ca-125. MSCT abdominal scan ovarial cystic. Bone age for left hand appropriate with 6 years and 10 months girl. Head CT scan suggestive pituitary macro adenoma, bilateral fronto temporal hypoplasia. This patient treated with levothyroxine 100 mcg/24 hour/oral, which result in tumor reduction.



No	Test	Result		
		Before treatment	Normal value	After treatment
1	Estradiol	1,036	6.00-27.00 pg/mL	26.5
2	Prolactin	255.3	0.3-12.9 ng/mL	14.7
3	FT4	0.22	0,85-1,75 ng/dL	1.24
4	TSHS	2,738	0.540-4.5 uIU/mL	0.49



Discussion

Precocious puberty associated with profound hypothyroidism is a rare condition and can be treated with levothyroxine which can give tumor reduction and stop bleeding.

References

- Durbin KL, Diaz-Montes T and Loveless MB. Van Wyk and Grumbach syndrome: an unusual case and review of the literature. J Pediatr Adolesc Gynecol. 2011; 24:e93-96.
- Billah NM, El Kouarty H and Dafiri R. A rare cause of precocious puberty and massive ovarian cysts associated with hypothyroidism. Open Journal of Clinical Diagnostics. 2016; 6:1-5.
- Wormbecker A & Clarkson C. Acquired primary hypothyroidism: vaginal bleeding in a quiet child. Canadian Medical Association Journal. 2010; 182:588-590.

Keywords: Precocious puberty, hypothyroidism, pituitary macro adenoma, levothyroxine

