

## CASE PRESENTATION

A previously healthy phenotypic female presented with primary amenorrhea at 17-years-of age. She had thelarche onset at age 10 and she progressed to Tanner Stage V breast development. She had no symptoms to suggest virilization or adrenal insufficiency. She had symptoms of pelvic fullness. Family history was negative for amenorrhea or fertility concerns.

Physical examination revealed a tall (height 187.3cm, 100<sup>th</sup> percentile) and lean body habitus. She has broad hands and long fingers. Pubertal assessment showed Tanner Stage V breast development and Tanner Stage V pubic hair, Prader score 0. An examination under anesthesia demonstrated a normal appearance of the vagina, cervix, uterus and fallopian tubes.

## INVESTIGATIONS

**Karyotype:** 46, XY (1-22), (X,Y) x1

Test	Reference Range	Result
Estradiol	pmol/L	145
Testosterone	0.5-2.0 nmol/L	<b>3.9 (High)</b>
FSH	U/L	<b>43.3 (High)</b>
LH	U/L	14.8
AMH	pmol/L	269.5
DHEAS	<11.0 umol/l	7.9
Androstenedione	<12.9 nmol/L	4.9
HCG	<5 U/L	<b>81 (High)</b>

**Table 1.** Initial biochemical investigations. FSH: follicle stimulating hormone, LH: luteinizing hormone, AMH: anti-Mullerian hormone, DHEAS: dehydroepiandrosterone, HCG: human chorionic gonadotropin

**Imaging:** Pelvic MRI showed large bilateral adnexal masses (left 9.4 cm, right 8.3 cm, see Figure 2), a normal appearing uterus and a slightly thickened endometrium.

**Pathology:** Pathology identified bilateral dysgerminomas arising from gonadoblastomas, with no metastases.

## CLINICAL COURSE

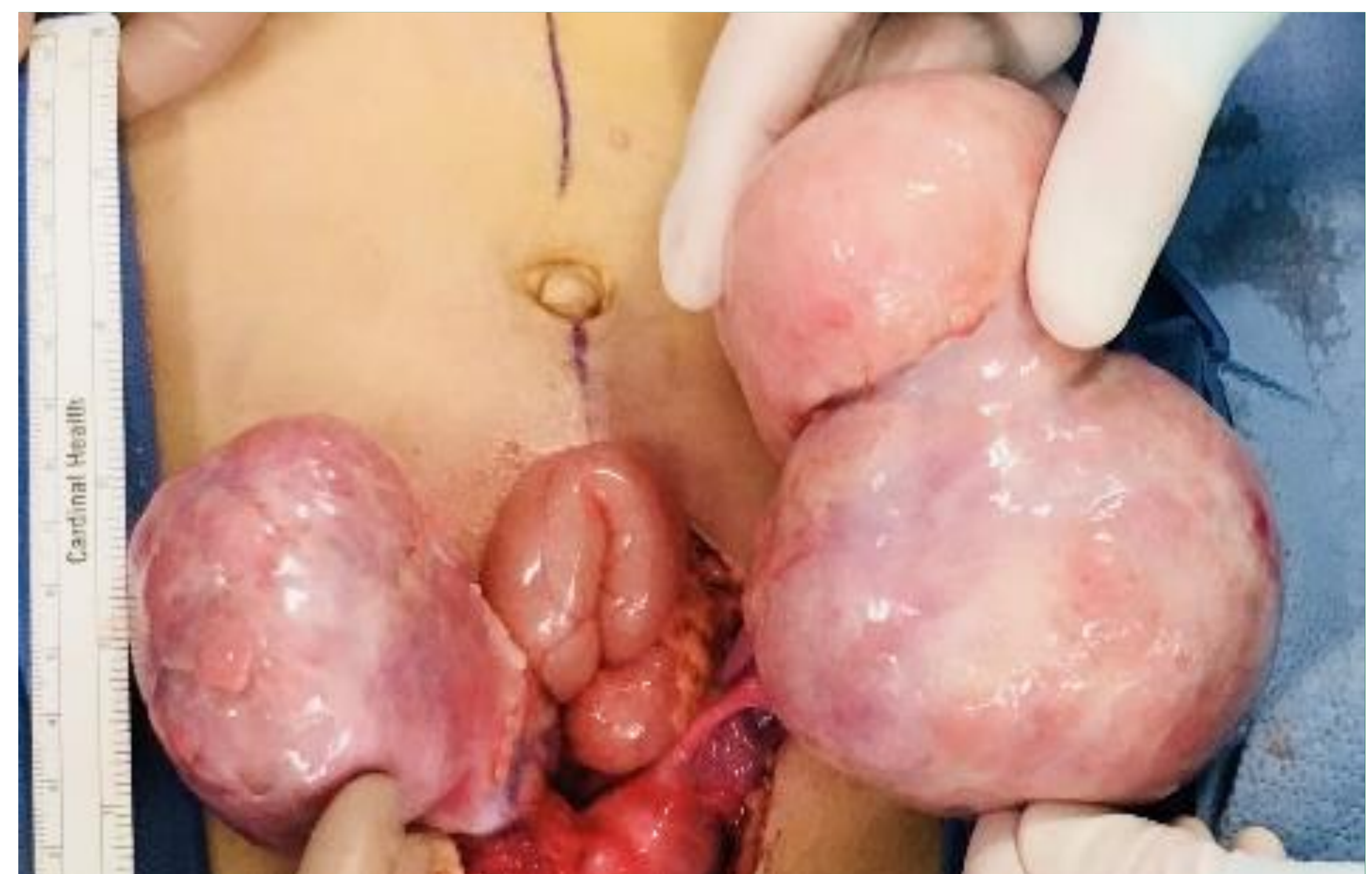Adjuvant chemotherapy was not required and tumor markers normalized post-operatively. After resection, she developed symptoms of hypoestrogenism and required estrogen replacement.

Genetic testing identified a **heterozygous** pathogenic variant in the POR gene, a rare cause of congenital adrenal hyperplasia. The phenotypic presentation of homozygous PORD is variable and manifestations include DSD, glucocorticoid deficiency and skeletal dysplasia. Biochemical evaluation showed no evidence of adrenal insufficiency.

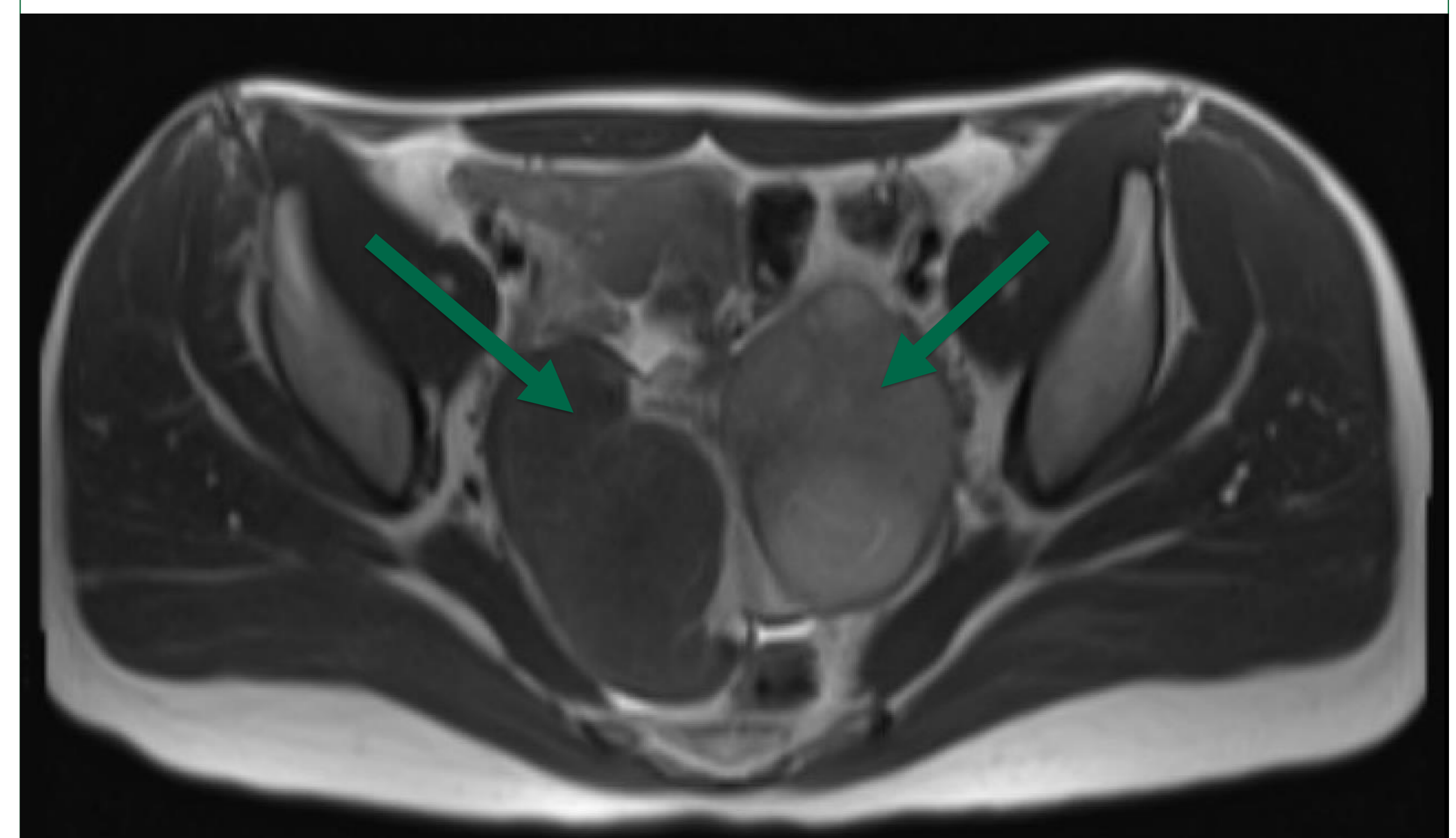
## DIFFERENTIAL DIAGNOSIS

The most frequent identifiable causes of 46-XY females are Androgen Insensitivity Syndrome (AIS) and Gonadal Dysgenesis. There were aspects of our patients clinic presentation that were consistent with each.

Features of Gonadal dysgenesis	Features of Androgen Insensitivity Syndrome
<ul style="list-style-type: none"> <li>Average age of presentation ~17.0 years</li> <li>20% of females with 46 XY DSD</li> <li>Presence of Mullerian Structures</li> <li>Streak gonads - No breast development</li> <li>High risk of Gonadal Malignancy</li> </ul>	<ul style="list-style-type: none"> <li>Average age of presentation ~7.5 years</li> <li>63% of females with 46 XY DSD</li> <li>Tall, lean, masculine body habitus</li> <li>Breast development due to aromatization</li> <li>Minimal/absent body hair</li> <li>Inguinal hernias</li> </ul>



**Figure 1.** Intraoperative findings of bilateral dysgerminomas



**Figure 2.** Pelvic MRI of bilateral adnexal masses

## DISCUSSION

Despite progressive understanding of DSD and the increasing role of genetic testing, challenges in diagnosis persist. We suspect partial gonadal dysgenesis and we hypothesize that there was adequate function of dysgenetic gonads for full thelarche, before malignant transformation. The dysgerminomas then produced testosterone, accounting for elevated levels but minimal virilization.

The identified heterozygous mutation for PORD is insufficient to explain her phenotype, however; we question if she has a secondary, unidentified compounding mutation. She has no clinical or biochemical features to suggest PORD.

This case highlights the challenges in diagnosing patients with 46 XY DSD and reinforces the value of a multi-disciplinary approach including genetic and endocrine expertise in diagnostic evaluation.

## References and Acknowledgements

- Baxter and Vilain. Translational Genetics for Diagnosis of Human Disorders of Sexual Development. *Annu. Rev. Genomics Hum. Genet.* 2013
- Krone et al. Genotype-Phenotype Analysis in Congenital Adrenal Hyperplasia due to PORD. *JCEM.* 2012
- Scott and Miller. Genetic and Clinical Features of p450 Oxidoreductase deficiency. *Hormone Research.* 2008
- Berglund et al. Incidence, Prevalence, Diagnostic Delay, and Clinical Presentation of Female 46,XY Disorders of Sexual Development. *JCEM.* 2016

**We extend our sincere gratitude to our patient and her family for giving us permission to share her story and photographs.**