

An unusual presentation of Hypothyroidism: Van Wyk-Grumbach syndrome

Imen Gargouri¹, Faten Hadjkacem¹, Wajdi Safi¹, Wafa Ben Othman¹, Nadia Charfi¹, Nabila Rekik¹, Mouna Mnif¹, Mohamed Abid¹

¹Department Of Endocrinology, Hedi Chaker Hospital, Sfax, Tunisia

Introduction :

The association of juvenile hypothyroidism, precocious puberty and ovarian enlargement is known as Van Wyk and Grumbach syndrome (VWGS). The pathophysiology of VWGS is not yet clear. This diagnosis is considered on the basis of imaging findings and thyroid function analysis. Thyroid hormone replacement therapy results in a resolution of all signs and symptoms.

Case report :

Herein we report a case of 9 years old girl was referred to the endocrinology department with a suspicion of precocious puberty after having progressive breast enlargement and premature menarche. Upon physical examination, her height was 91.5 cm (< -4SDS), with weight of 24 kg (-1 SDS). She had a puffy face with yellowish discoloration and very dry skin, and her thyroid gland was normal on palpation. On pubertal assessment, her breasts were Tanner stage 3 and pubic hair was Tanner stage 1. Hormonal investigations revealed elevated thyroid-stimulating-hormone (TSH) >150 mIU/ml (normal: 0.35– 5.5 mIU/ml), low Free-thyroxine FT4 at 0.5 ng/ml (normal: 4.5–12.6 ng/ml), (>150 μ UI/ml) and low Free-thyroxine. Follicle-stimulating-hormone level was 7.5 mIU/ml, Luteinising-hormone (LH) level was < 0.07 mIU/ml (0.1–6.0) and prolactin circulating level were normal. Tg Ab 1335 IU/ml (normal range <150 IU/ml) and TPO Ab 1000 IU/ml (normal range <75 IU/ml). Abdominal ultrasound was normal with normal appearance of the uterus, ovaries and no visible endometrial line. X-ray of the wrist revealed a delayed bone age estimated at 2 years using Greulich and Pyle's atlas. Ultra sonography of the thyroid showed a heterogeneous highly suggestive for thyroiditis. Brain magnetic resonance imaging (MRI) showed an enlarged pituitary gland, with homogeneous enhancement measuring 19x15 mm (fig1). The diagnosis of ovarian hyper stimulation secondary to severe hypothyroidism was made and thyroid hormonal replacement was started on levothyroxine, increased gradually to 175 μ g (7 μ g/Kg/day). Upon follow-up, 2months after starting on treatment, she reported significant improvement of clinical features of hypothyroidism and there was a significant involution of her breast tissue. Repeat laboratory tests 6 months later showed normalisation of TSH and pituitary MRI 10 months after thyroid replacement therapy, showed a reduction in the size of the gland (fig2).

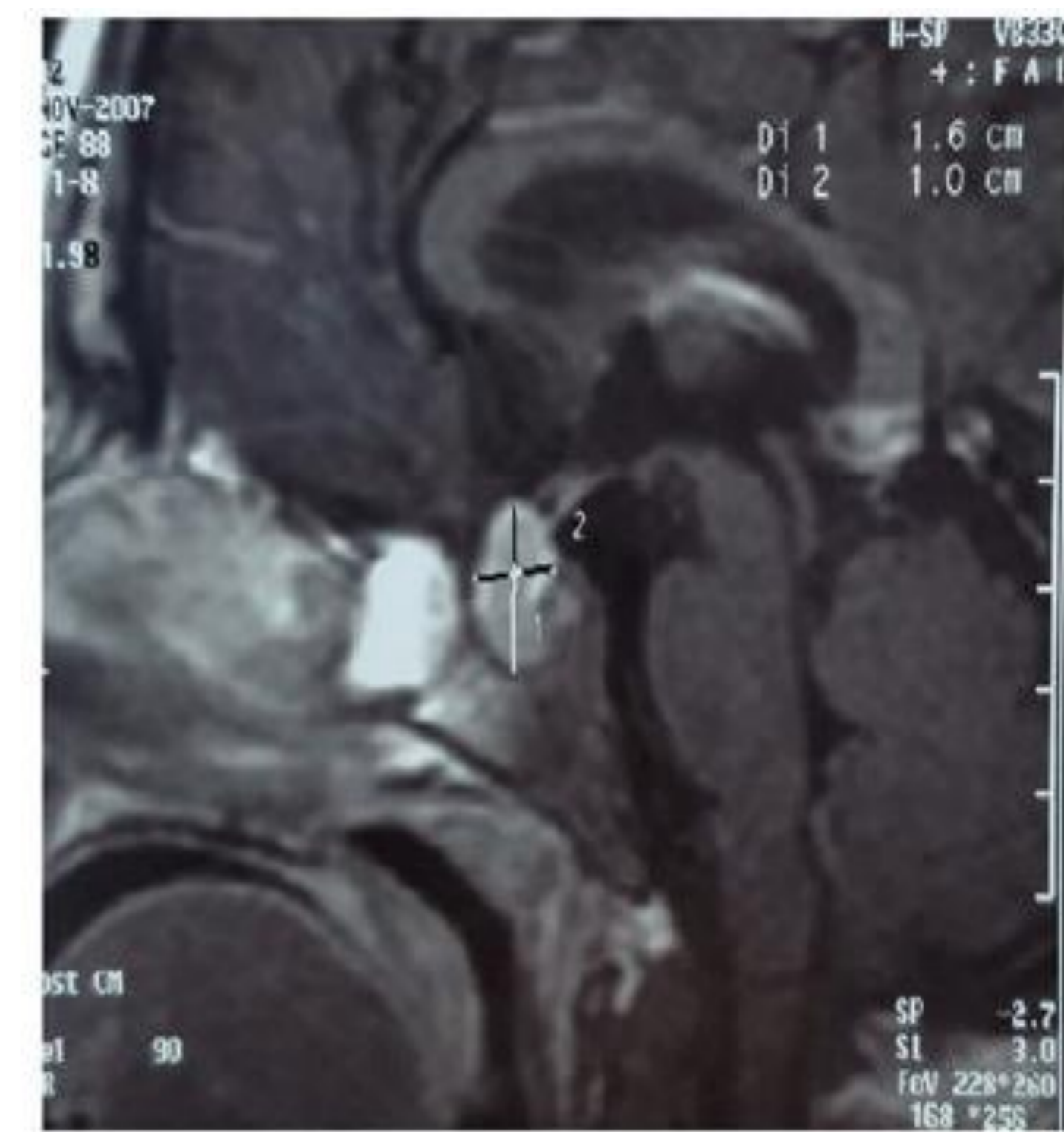

Fig 1: Initial MRI of the pituitary gland. Post enhanced T1 weighted sagittal MRI shows marked enlargement of the pituitary gland that extends slightly into the suprasellar region, with homogeneous enhancement

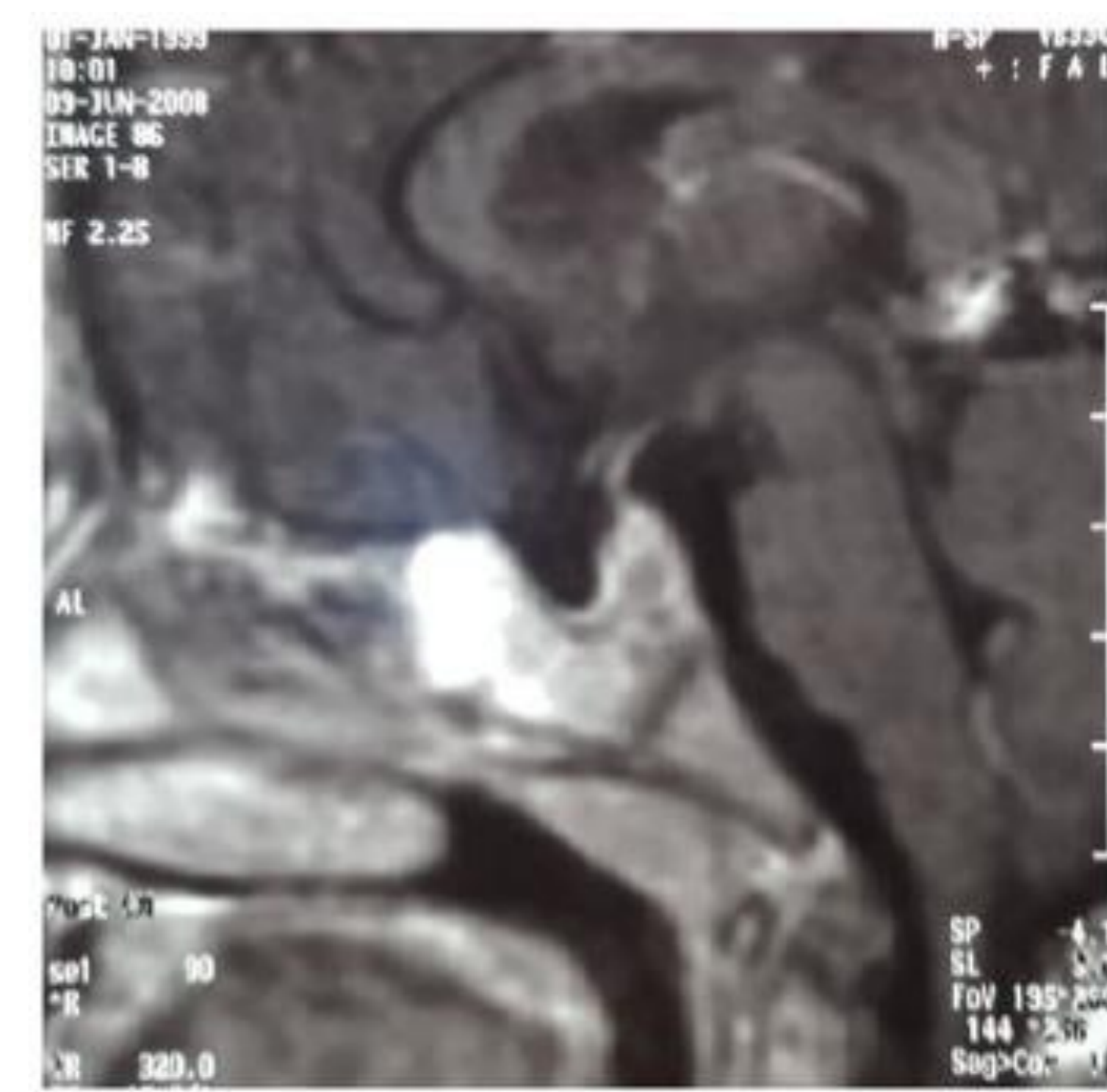


Fig 2: Follow up MRI of the sella 10 months after treatment. The pituitary gland is normal in size and configuration, remains confined to the sella, and shows homogeneous enhancement.

Discussion et conclusion:

Van Wyk and Grumbach described a syndrome of precocious menstruation in juvenile hypothyroidism, with reversion to a pre-pubertal state after thyroid replacement therapy. A clue to the diagnosis is the delayed bone age(1). The most common cause of hypothyroidism in these patients is autoimmune thyroiditis(2). This case demonstrates that VWGS should be kept in mind even in patients without cystic ovarian enlargement. The mechanism of VWGS is not yet clear, multicystic ovaries and hyperfunction may result from elevated levels of circulating FSH. It is also possible that increased sensitivity of the ovaries to the circulating gonadotropins could result from the hypothyroid state directly in the lack of the negative feedback of thyroid hormones (1). Another hypothesis has suggested that overproduction of prolactin resulting in either an increased level of gonadotropin-releasing hormone or an increased level of estrogen by upregulation of follicle-stimulating hormone receptors (3). The current and most widely accepted theory is that high levels of TSH act on FSH receptors because the molecular similarities between the glycoprotein receptors of the two hormones, which share a common α subunit (3). In patients with isosexual pseudo-pubertal precocity, early recognition of this diagnosis and initiation of thyroid hormone replacement can avoid further diagnostic procedure and unnecessary surgery. It helps to resolve symptoms and improve final height.

References

- (1) Van Wyk JJ and Grumbach MM. Syndrome of precocious menstruation and galactorrhoea in juvenile hypothyroidism: an example of hormonal overlap in pituitary feedback. *Journal of Pediatrics*. 1960;57(3):416–435.
- (2) Gordon CM, Austin DJ, Radovick S and Lufers MR. Primary hypothyroidism presenting as severe vaginal bleeding in a prepubertal girl. *J Pediatr Adolesc Gynecol*. 1997;10(1):35–38.
- (3) Kaci L., Durbin K., Diaz-Montes T., Loveless M., Van Wyk Grumbach: an unusual case and review of the literature *J Pediatr Adolesc Gynecol* 2011; 24:e93-e96

