Ultrasound features of multinodular goiter in DICER1 syndrome

Marek Niedziela[1], Karl Muchantef[2], William D Foulkes[3-5]

[1]Department of Pediatric Endocrinology and Rheumatology, Karol Jonscher's Clinical Hospital, Poznan University of Medical Sciences, Poland; marek.niedziela@ump.edu.pl; [2]Department of Radiology, Montreal Children's Hospital, McGill University Health Centre, Montreal, QC, Canada; karl.muchantef@mcgill.ca ; [3]Department of Human Genetics, McGill University; william.foulkes@mcgill.ca; Department of Medical Genetics, McGill University Health Centre, Montreal, QC, Canada; Lady Davis Institute, Jewish General Hospital, Montreal, QC, Canada

Background

DICER1 syndrome is caused by germline mutations in the *DICER1* gene *(de Kock L, Wu MK, Foulkes WD. Ten years of DICER1 mutations: Provenance, distribution, and associated phenotypes. Hum Mutat. 2019 Jul 24. doi: 10.1002/humu.23877. [Epub ahead of print].* **It is associated with a wide spectrum of benign and malignant neoplasms** *(Choong CS, Priest JR, Foulkes WD. Exploring the endocrine manifestations of DICER1 mutations. Trends Mol Med 2012)*, **which are accompanied by specific somatic mutations in *DICER1*. Multinodular goiter (MNG) is a common clinical feature of DICER1 syndrome in children and adults; the thyroid ultrasound features of MNG in the setting of DICER1 syndrome have not been widely reported.**

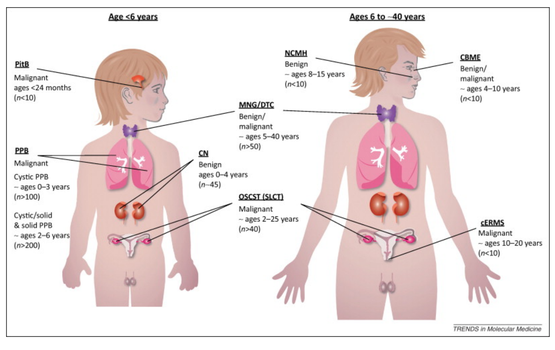

Objective

The aim of this study is to determine the US characteristics of MNG in patients with DICER1 syndrome.

Materials and Methods

This retrospective study evaluated thyroid ultrasound studies performed between 2011 and 2018 at a single centre. Patients ≤18 years with *DICER1* germline mutations and an intact thyroid gland were identified and included. Mutation-positive parents without previous thyroidectomy were also included. All studies were performed by the same pediatric endocrinologist and were subsequently re-examined by an independent radiologist from another academic center. The architecture of lesions was characterized as: simple cyst, septated cyst, mixed cystic and solid, or solid *(Bueno et al Pediatr Radiol 2017).* **Ultrasound phenotypes of MNG in the setting of *DICER1* mutations were compared with known US features of thyroid malignancy. All mutations in *DICER1* were identified in a single research laboratory and confirmed via orthogonal techniques.**

Results

Thirteen *DICER1* mutation-positive persons were identified (10 children, 3 adults). Three children had a normal thyroid ultrasound; therefore, thyroid abnormalities were assessed in 7 children and 3 adults.

In both children and adults, mixed cystic and solid nodules predominated (Fig. 1).

We did, however, observe also single cystic, single cystic septated and single solid nodules. Solid lesions were present in 9 of 10 patients but all were isoechogenic and without detectable intranodular blood flow except in one patient with multiple solid nodules (Fig. 2).

Other findings that are characteristic for MNG in DICER1 syndrome were as follows: multiple lesions (≥3) in all examined patients ocasionally with a "spoke-like" presentation, absent vascular flow on Power/Color Doppler (except 1 patient), and macrocalcifications were present in all three adults (Fig. 3).

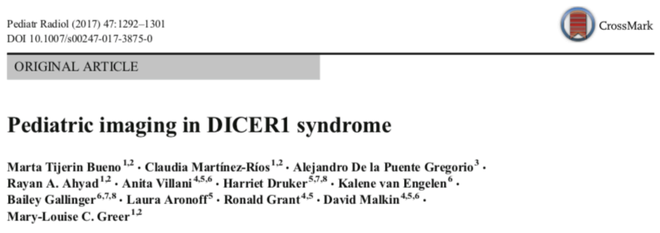
Pediatr Radiol (2017) 47:1292–1301
DOI 10.1007/s00247-017-3875-0
CrossMark
ORIGINAL ARTICLE
Pediatric imaging in DICER1 syndrome
Marta Tijerin Bueno[1,2] · Claudia Martínez-Ríos[1,2] · Alejandro De la Puente Gregorio[3] · Rayan A. Ahyad[1,2] · Anita Villani[4,5,6] · Harriet Druker[5,7,8] · Kalene van Engelen[6] · Bailey Gallinger[6,7,8] · Laura Aronoff[5] · Ronald Grant[4,5] · David Malkin[4,5,6] · Mary-Louise C. Greer[1,2]

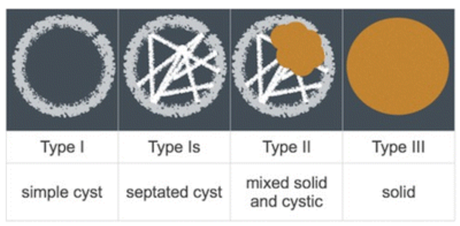

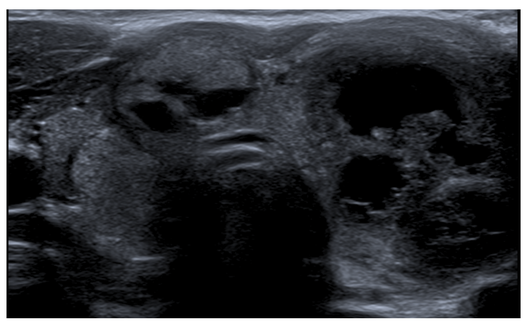

Figure 1

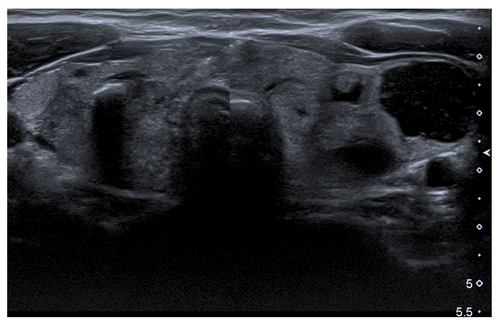

Figure 3

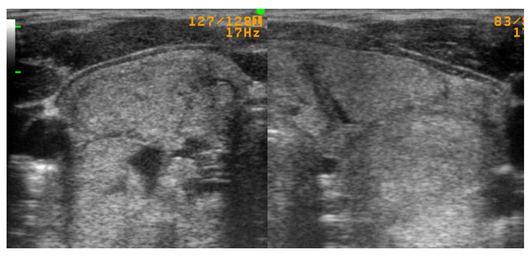

Figure 2

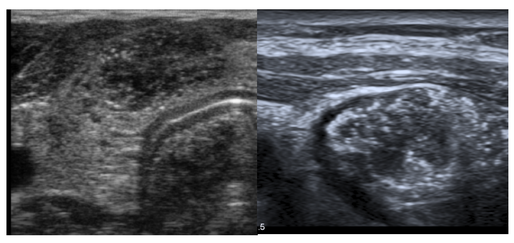

Figure 4a-b

Conclusions

1. **The spectrum of US findings of MNG in DICER1 mutation-positive patients is characteristic and is largely distinct from typical features of thyroid malignancy (Fig. 4a-b).**
2. **Observed patterns include: multiple lesions (≥3), mixed cystic and solid elements, absence of detectible vascular flow, and a "spoke-like" appearance.**
3. **Macrocalcification was observed only in adults.**
4. **These features should sensitize physicians performing thyroid ultrasound to the possible presence of underlying DICER1 syndrome.**

ePoster 518

Session Name:
Rapid Free Communication 5: RFC5.2
Session Date: Thursday 19 September 2019
Session Time: 17:00 - 18:30 (Exact presentation time 17:05-17:10)