



P2-36

The authors have nothing to disclose

A 10-year-old girl with primary hypoparathyroidism and systemic lupus erythematosus (SLE)



Hanna Borysewicz-Sańczyk¹, Beata Sawicka¹, Justyna Michalak¹, Jerzy Wójtowicz¹, Elżbieta Dobreńko², Jerzy Konstantynowicz², Elizabeth H. Kemp³, Rajesh V. Thakker⁴, Jeremy Allgrove⁵, Sarah Black⁶, Shu Chen⁶, Jadwiga Furmaniak⁶, Bernard Rees Smith⁶, Artur Bossowski¹

¹Department of Pediatrics, Endocrinology, Diabetology with a Cardiology Division, Medical University of Białystok, Poland, ²Department of Pediatrics, Rheumatology, Immunology and Metabolic Bone Diseases, Medical University of Białystok, Poland, ³Department of Oncology and Metabolism, University of Sheffield, Sheffield, UK ⁴Academic Endocrine Unit, Radcliffe Department of Medicine, Oxford Centre for Diabetes, Endocrinology and Metabolism, University of Oxford, Oxford, UK, ⁵Department of Pediatric Endocrinology, Great Ormond Street Hospital for Children, London, UK. ⁶FIRS Laboratories, RSR Ltd, Cardiff, United Kingdom.

Introduction:

Parathyroid Hormone (PTH) is one of the principal regulatory hormones for calcium and phosphate homeostasis. Reduced PTH concentration in hypoparathyroidism is characterised by persistent hypocalcaemia and hyperphosphataemia. Hypoparathyroidism in children can occur either as component of a genetic syndrome e.g. 22q Deletion (DiGeorge) Syndrome, autoimmune disorder or be acquired secondarily to thyroidectomy or some destructive processes of the glands.

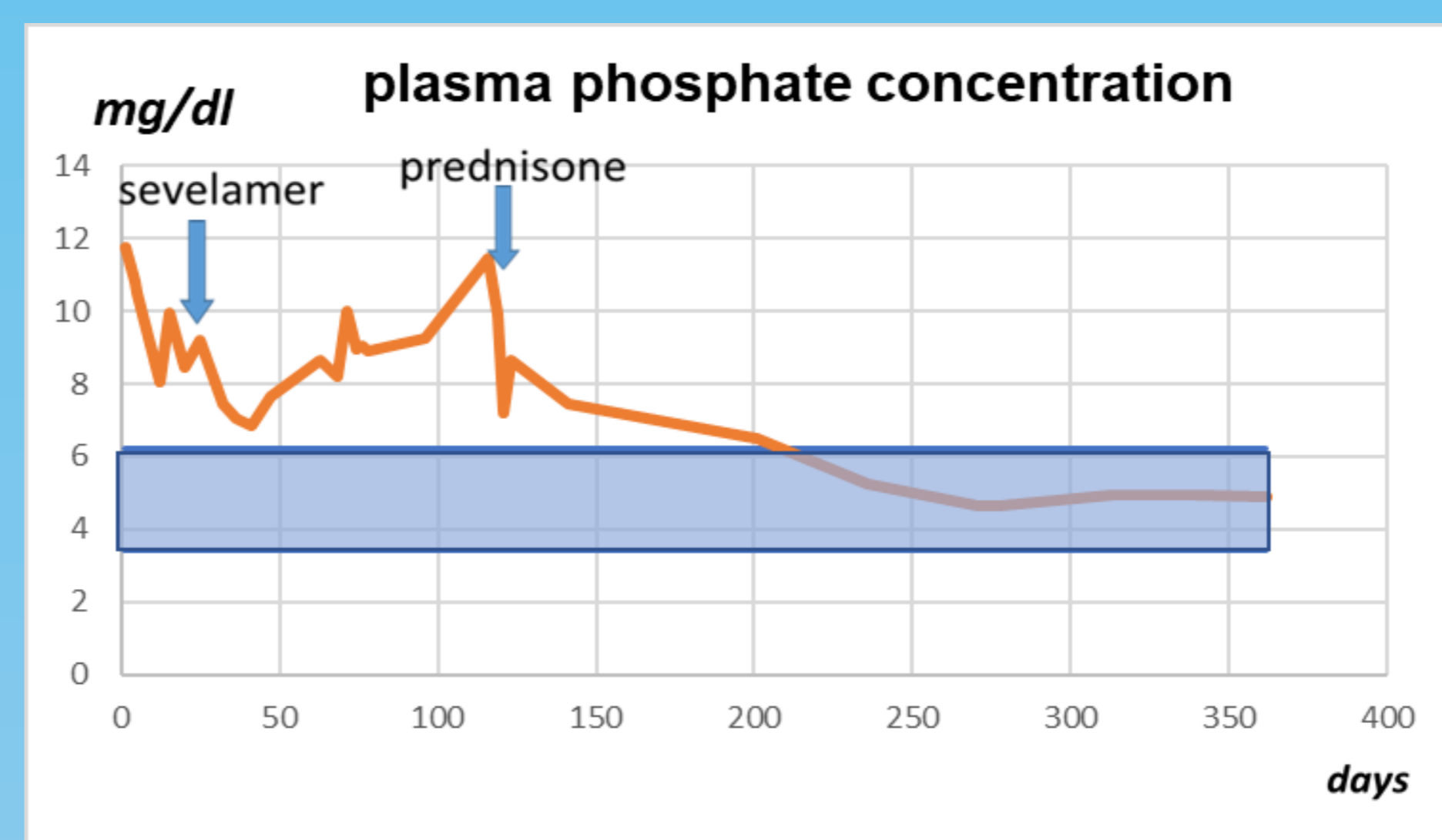
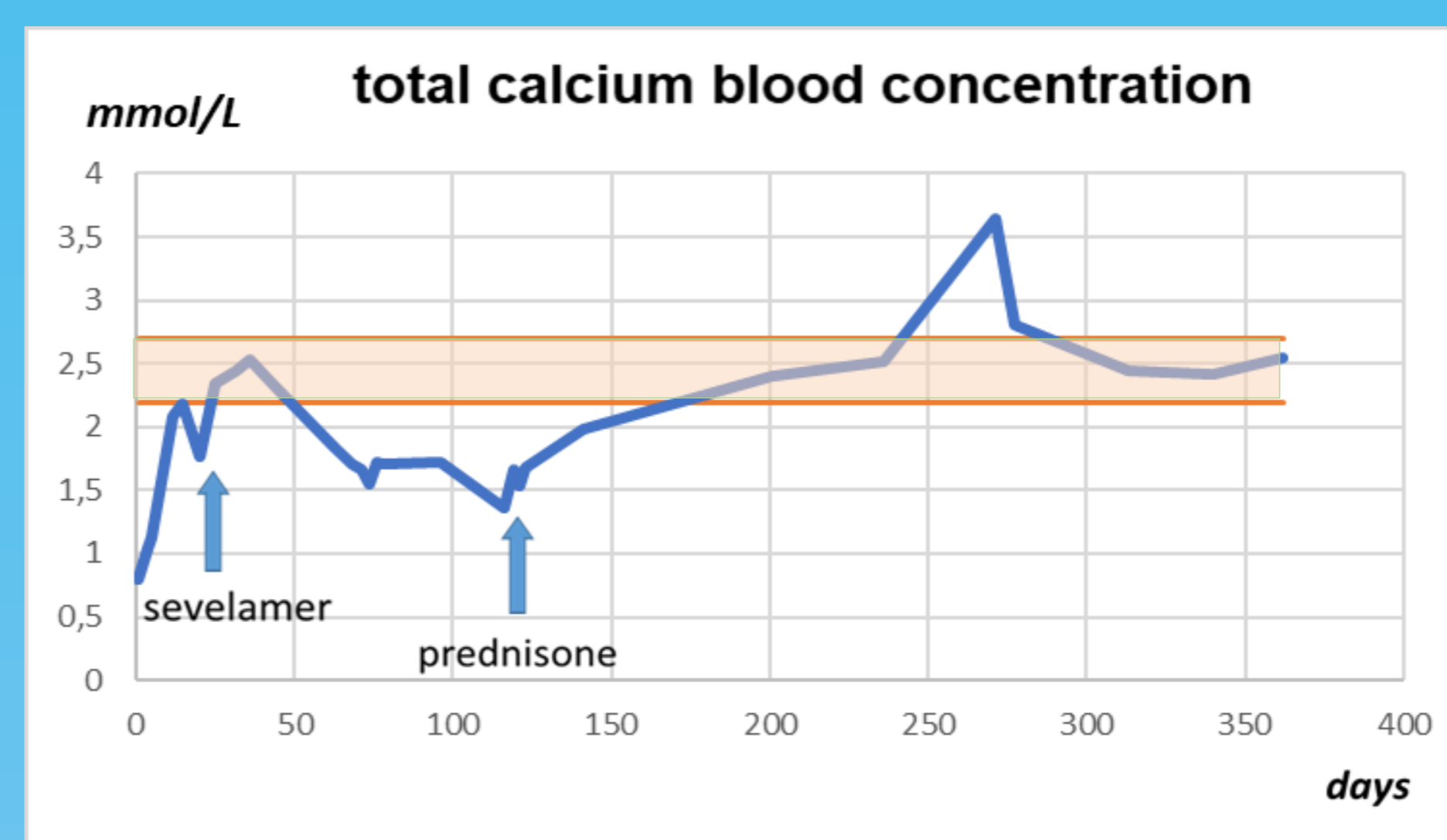
Case presentation:

We report a ten-year-old girl who initially presented to the Department of Pediatric Neurology and Rehabilitation, Medical University of Białystok due to repeated seizures, but then, after hypocalcaemia had been confirmed, was admitted to the Department of Paediatrics, Endocrinology, Diabetology with Cardiology with suspected hypoparathyroidism. Her postnatal medical history was unrevealing, and there was no history of candidiasis. Regarding family history, patient's mother reported epilepsy and arrhythmias.

The girl was admitted severely unwell with drowsiness and confusion. Physical examination revealed a non-specific rash on the whole body surface (probably an allergic reaction to oxcarbazepine), and mild insignificant dysmorphic features - hypertelorism. Because of the low PTH concentration (<3pg/ml; NR 10-60) and typical biochemistry (total serum calcium concentration 0.8 mmol/l, plasma phosphate 4.1 mmol/L), primary hypoparathyroidism was confirmed. Other hormonal analyses showed no thyroid or adrenal disorders (TSH, fT4, cortisol and ACTH level were normal). Liver and kidney function were normal. Ultrasonography of the thyroid and parathyroids showed a hyperechoic area in the thyroid left lobe (II according to Bethesda), but no parathyroid pathology. Long QTc (over 0.5 seconds) was present in the ECG. Hypocalcaemia was initially treated with intravenous and oral calcium, vitamin D3 and vitamin D analogue i.e., synthetic precursor of the active form of vitamin D3, alfacalcidol. Sevelamer, a phosphate-binding drug was used for the management of hyperphosphataemia. The patient was also treated with valproic acid for the concomitant epilepsy and beta-blocker for LQTc syndrome. Calcium in the serum remained below the normal reference range, and phosphate level increased initially despite the treatment.

During hospitalization the girl twice developed intermittent fever, accompanied by an elevated CRP and radiological features of pneumonia and pericardial effusion. Despite negative blood cultures and no serological evidence of viral infections, including HIV, B19 parvovirus, influenza virus, a number of zoonoses and tuberculosis she was treated empirically with antibiotics.

The CT scan, MRI and PET MRI did not reveal any abnormalities. Bone mineral density measured with DXA was within the normal range. Based on the presence of standard clinical criteria, systemic lupus erythematosus (SLE) was diagnosed and the treatment with glucocorticoids was initiated, which improved parameters of calcium-phosphate balance.



Further immunological examinations revealed INF-omega antibodies before implementation of steroid therapy, with negative IL-22, IL-17A, IL-17F, IFN-lambda, IFN-omega, IFN-alpha2A, and CaSR antibodies after this treatment. Genetic diagnosis excluded AIRE and CaSR mutations.

Antibodies	Positive/negative	Result	Reference range
diabetes screening (GAD, IA2, ZnT8)	Negative	6.7 (index)	≤30 (index)
IFN-ω Ab (07.03.2018)	Negative	<5 (index)	<5 (index)
IFN-ω Ab (27.06.2018)	Positive	21.4 (index)	<5 (index)
21OH Ab	Negative	<0.4 u/mL	≤0.4 u/mL
CaSR Ab	Negative	0.52 (index)	<1.37 (index)
AChR Ab	Negative	<0.45 nmol/L	<0.45 nmol/L
17α-OH Ab	Negative	<1 u/mL	<1 u/mL
t-TGA Ab	Negative	0.4 U/mL	<4 U/mL
TPO Ab	Negative	5.9 IU/mL	<34 IU/mL
TG Ab	Negative	13.6 IU/mL	<115 IU/mL
TSH-R Ab	Negative	0.35 IU/L	<1.75 IU/L

Autoimmune antibodies screened for in the patient

Conclusions:

Coexistence of hypoparathyroidism with SLE, the presence of INF-omega autoantibodies and normalization of calcium and phosphate serum concentration following glucocorticoid treatment may suggest an autoimmune background of the disease in the patient. However, further investigation is needed to detect specific underlying mechanism responsible for insufficient PTH secretion.