

A NOVEL MUTATION OF PHEX GENE INDUCING X-LINKED HYPOPHOSPHATEMIC RICKETS, A CASE REPORT

Renata M. Pinto, MD, MSc^{1,2,3,4}; Lucas S. Steinmetz⁴; Julio M. G. Barbosa⁴; Arthur F. C. S. Mendes⁴; Damiana Mirian Da Cruz Cunha, MSc^{1,2,5}; Aparecido D. da Cruz, MSc, PhD^{1,2,5,6}

¹ Department of Biology, Replicon Research Center, Catholic University of Goiás, Goiânia, GO, Brazil; ² Postgraduate Program in Genetics, Catholic University of Goiás, Goiânia, GO, Brazil; ³ Health Sciences PhD Program, Federal University of Goiás, Goiânia, GO, Brazil; ⁴ Department of Pediatrics, Federal University of Goiás, Goiânia, GO, Brazil; ⁵ Laboratory of Human Cytogenetics and Molecular Genetics, Secretary of State for Health of Goiás (LACEN/SESGO), Goiânia, GO, Brazil; ⁶ Biotechnology and Biodiversity Graduate Program, University of Brasília, Brasília, DF, Brazil

INTRODUCTION

X-linked hypophosphatemic rickets (XHR) is the most common form of hereditary rickets, with an estimated incidence of 1: 20.000 individuals. The main characteristic of the disease is excessive renal phosphate loss, which leads to hypophosphatemia with high phosphaturia and defective bone mineralization.

XHR results from mutations in the in the PHEX gene (Phosphate Regulatory Gene with Homology for Endopeptidases located on the X chromosome) located at Xp22.1. PHEX gene has 22 exons and is expressed mainly in the cell membrane of bones and teeth. Currently, at least 364 mutations have been identified, and are registered in the Human Gene Mutation Database.

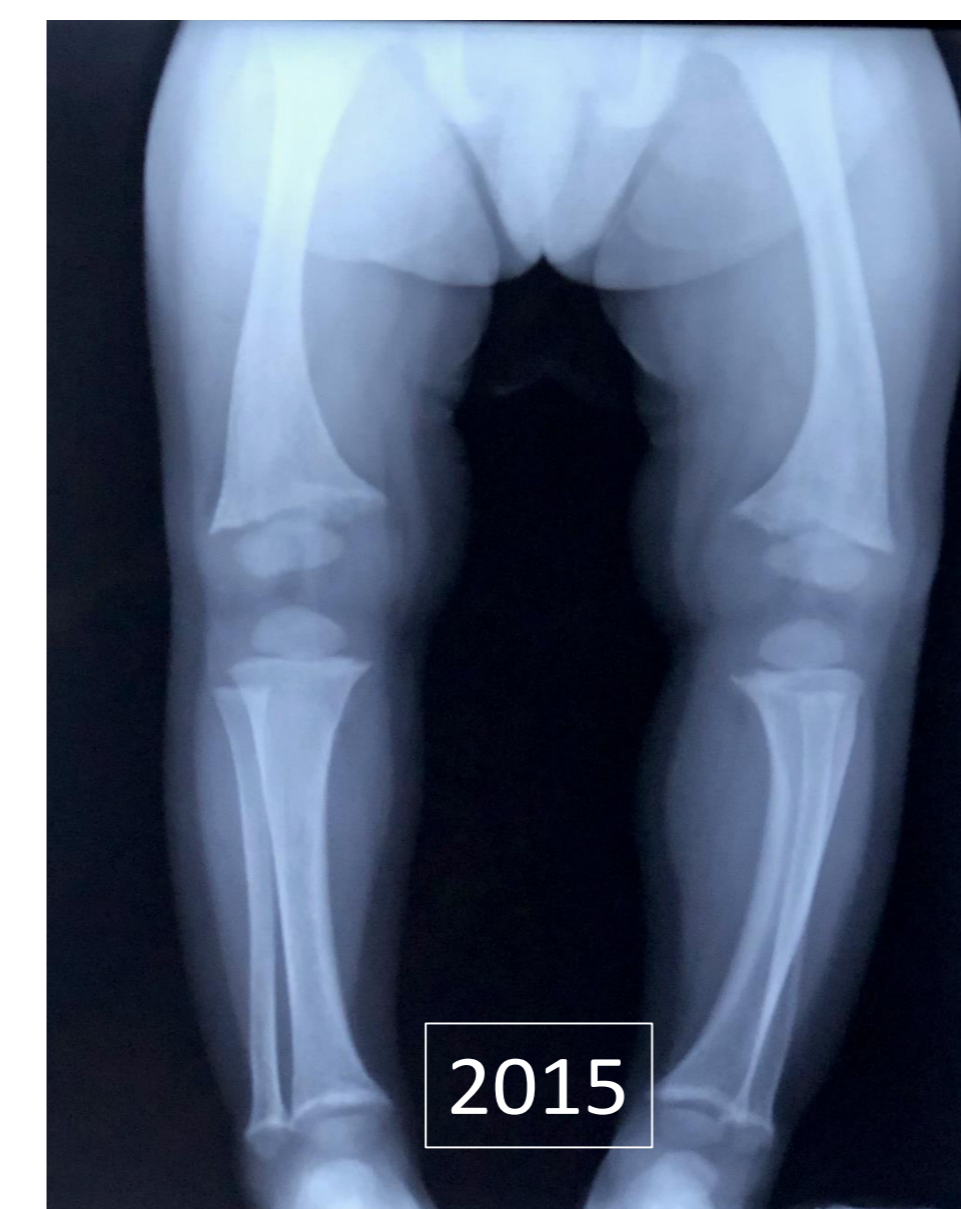

Figure 2 – Lower Limbs XR 3y age

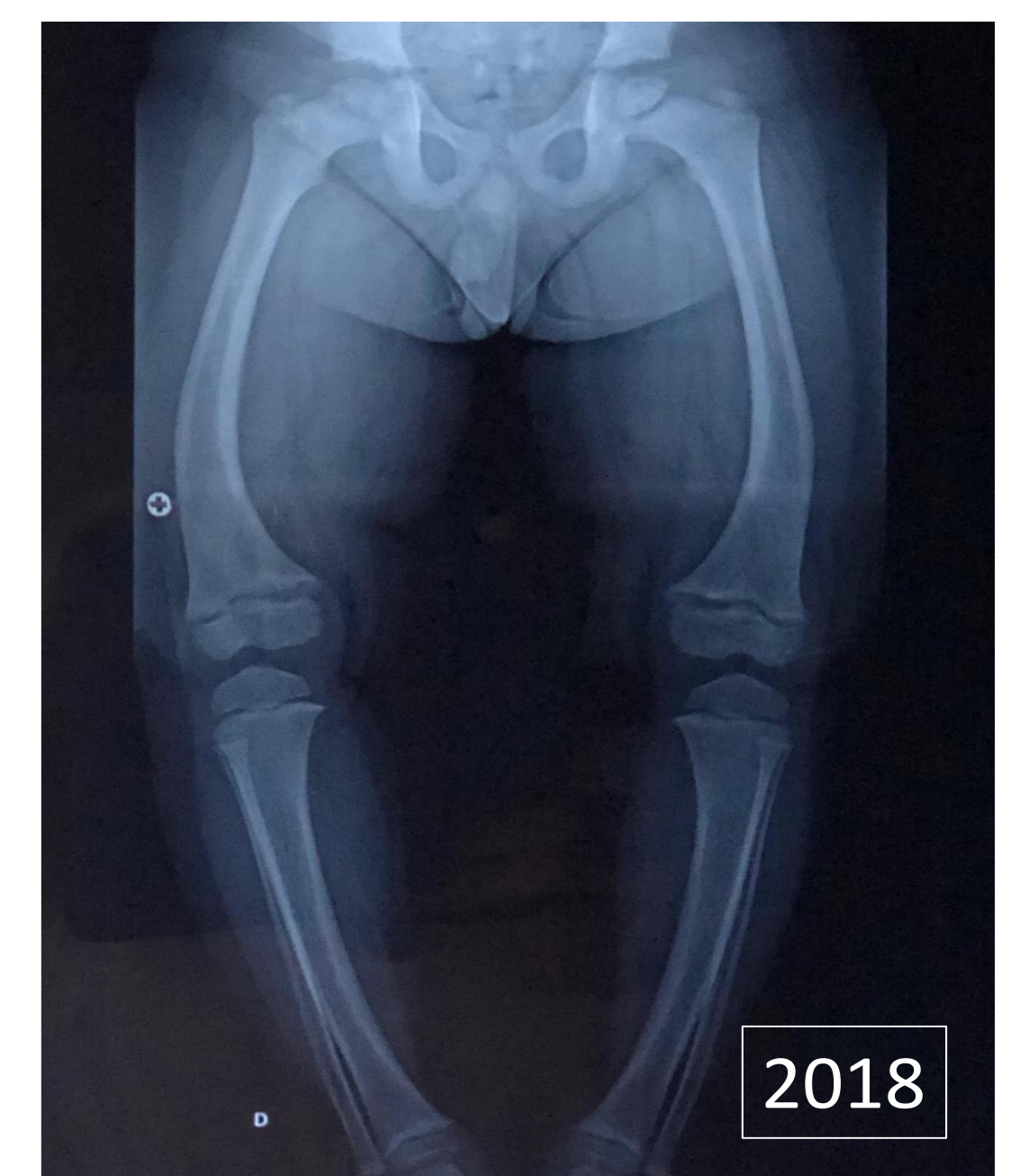

Figure 3 – lower Limbs XR 5y age

MOLECULAR ANALYSIS

New generation sequencing of the PHEX gene (OMIN 300550) was performed. We found the variant ChrX: 22.239.768 T>TG (c.1809dupG) which promotes the substitution of the amino acid Serine at position 604 by a Valine and generates a premature stop codon.

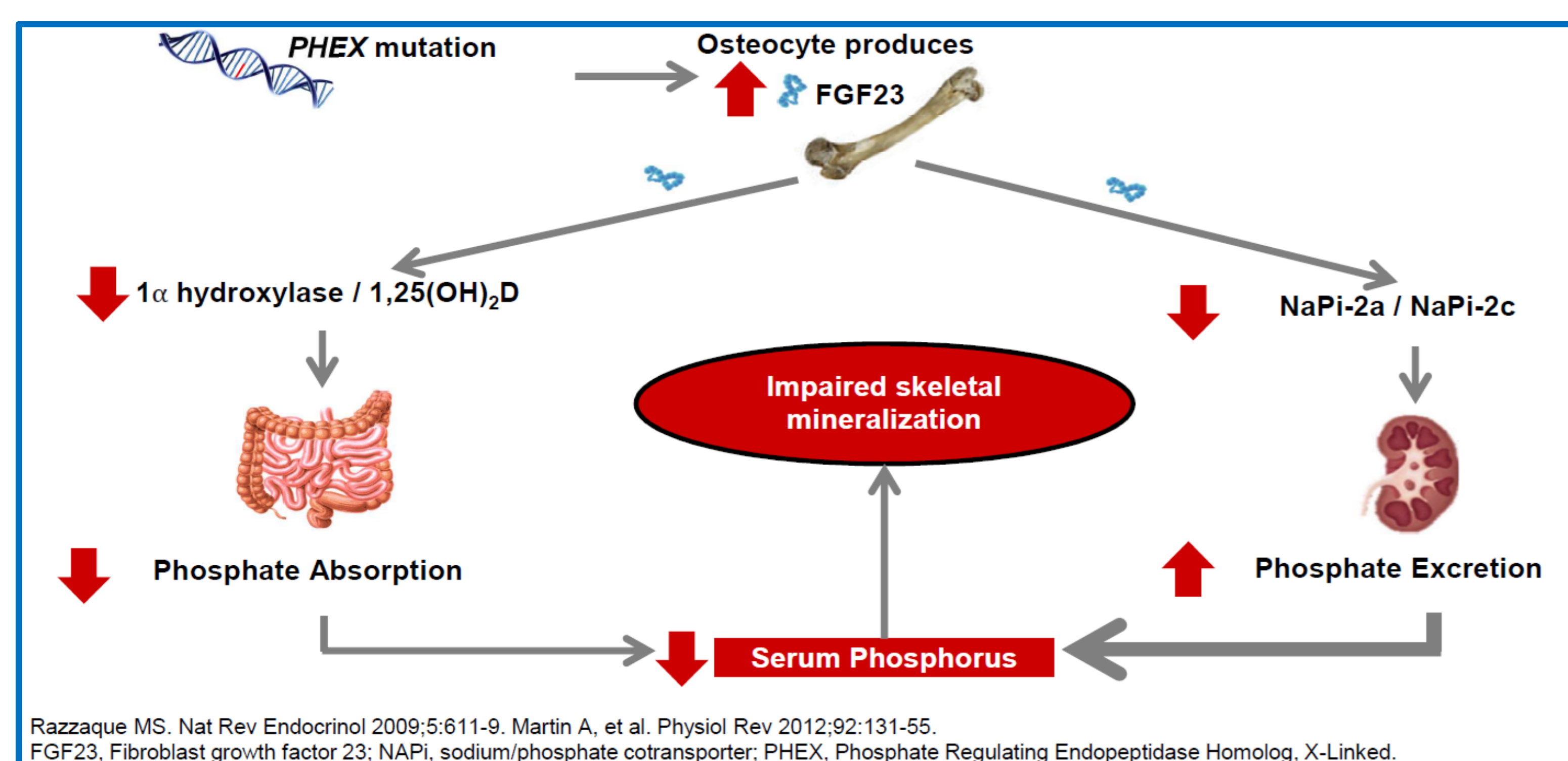


Figure 1 – Pathophysiology of X-linked hypophosphatemic rickets

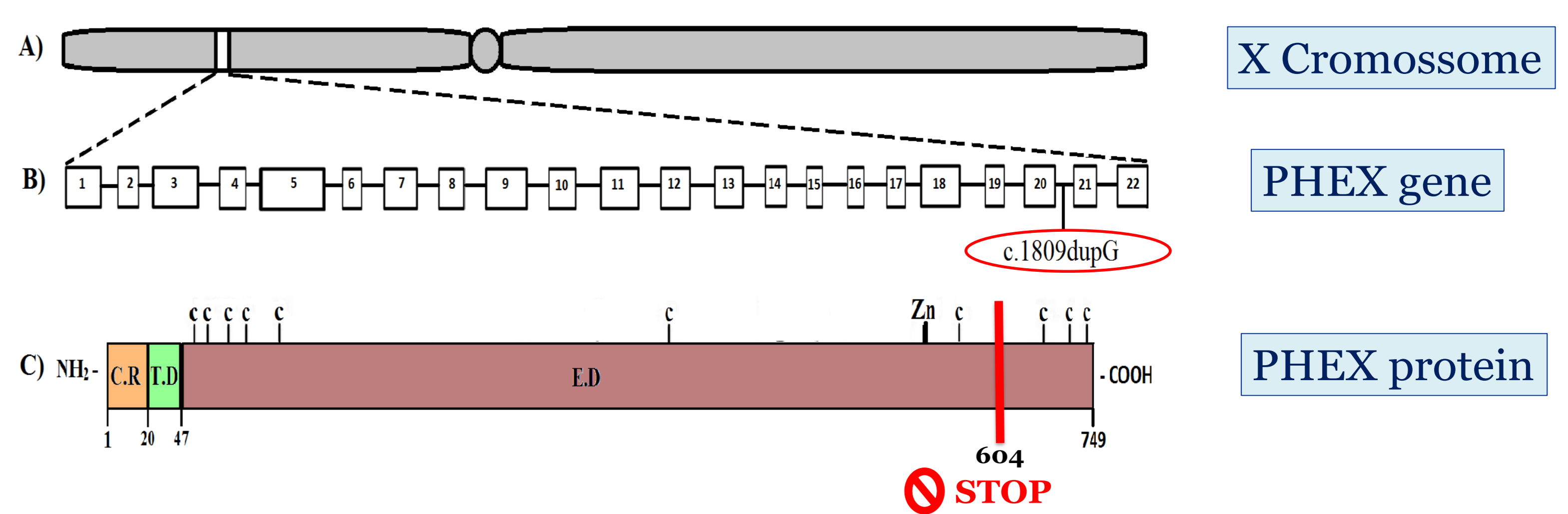


Figure 4 – Normal and abnormal PHEX gene and protein

CASE REPORT

RRMJ, 2 years, was referred to the pediatric endocrinology service due to reduction of growth rate, irritability, limb pain, skeletal malformations and bowing of legs (Fig. 2 and 3). The biochemical parameters showed hypophosphatemia, elevated alkaline phosphatase, elevated PTH, normal calcium, increased urinary phosphorus.

Currently he is 6 years of age, and receives treatment with high doses of phosphate and 1,25OH-dihydroxyvitamin D3, since he had 2 years and 2 months of age. The patient has difficulty following the prescription correctly due to frequent diarrhea and abdominal pain, and continues to grow at a percentile below the family target.

CONCLUSION

A novel pathogenic PHEX mutation was found: c.1809dupG, which caused early termination of translation and produced truncated protein that lead to exuberant clinical expression. Due to poor response to traditional treatment, it is scheduled to start treatment with Burosumabe as soon as the drug is released in our country.

REFERENCES

- Acar S et al. Clinical and genetic characteristics of 15 families with hereditary hypophosphatemia: Novel Mutations in PHEX and SLC34A3. *PLoS one*, v. 13, n. 3, p. e0193388, 2018.
- Durmaz E et al. Novel and de novo PHEX mutations in patients with hypophosphatemic rickets. *Bone*, v. 52, n. 1, p. 286-291, 2013.
- Nunes AB, Lazaretti-Castro M. Raquitismo hipofosfatêmico: da clínica à genética molecular. *Arquivos Brasileiros de Endocrinologia & Metabologia*, v. 44, n. 2, p. 125-132, 2000.
- Pavone V et al. Hypophosphatemic rickets: etiology, clinical features and treatment. *European Journal of Orthopaedic Surgery & Traumatology*, v. 25, n. 2, p. 221-226, 2015.
- Razzaque MS. Nat Rev Endocrinol 2009;5:611-9. Martin A, et al. Physiol Rev 2012;92:131-55.
- Rothenbuhler A et al. Diagnosis, treatment-monitoring and follow-up of children and adolescents with X-linked hypophosphatemia (XLH). *Metabolism-Clinical and Experimental*, 2019.
- Sako S et al. A novel PHEX mutation associated with vitamin D-resistant rickets. *Human genome variation*, v. 6, n. 1, p. 9, 2019.
- Pavone Vito et al. Hypophosphatemic rickets: etiology, clinical features and treatment. *European Journal of Orthopaedic Surgery & Traumatology*, v. 25, n. 2, p. 221-226, 2015.