

# In case of osteogenesis imperfecta transmission in pregnancy: check vitamin D and calcium status of the mother.



V. PORQUET-BORDES <sup>1</sup>, M. GROUSSOLES <sup>2</sup>, J. VIAL <sup>3</sup>, S. BOETTO <sup>4</sup>, J. SALES DE GAUZY <sup>5</sup>, T. EDOUARD <sup>1,6</sup>, J.P. SALLES <sup>1,6</sup>

<sup>1</sup> Unit of Bone Diseases and Endocrinology, Children's Hospital, CHU Toulouse, France, <sup>2</sup> Department of Obstetrics, CHU Toulouse France, <sup>3</sup> Department of Radiology, CHU Toulouse France, <sup>4</sup> Department of Neurosurgery, CHU Toulouse France, <sup>5</sup> Department of Orthopedic Surgery CHU Toulouse France, <sup>6</sup> INSERM 1043 Toulouse, France

Nothing to disclose

## BACKGROUND

A one-month-old girl was referred to our unit for osteogenesis imperfecta (OI) suspected on antenatal ultrasound: short and bowed long bones. She was the first child of non consanguineous parents. Pregnancy was obtained after 3 miscarriages. The father had no history of fracture. The mother, 28 year-old, presented with a severe de novo OI, with first fractures beginning at 1 month of age, short adult height (140 cm), moderate scoliosis without arthrodesis, normal skull base. She had more than 20 limb fractures, no vertebral fracture and bowing limbs without need of surgery. She received intravenous bisphosphonates during 3 years until 12 years of age. Then she stopped any treatment and medical following in spite of a fracture occurring every year. During pregnancy, she received 100,000 units of 25-hydroxyvitamin D (25OHD), as any pregnant women [1] and had a low uncorrected calcium consumption (600 mg/day). At 33 weeks of gestational age, a femoral diaphyseal fracture occurred after a fall. She had an orthopedic management and a laboratory investigation. A vitamin D deficiency was noted. 25OHD level was 4 ng/ml (<30 ng/ml), with high serum alkaline phosphatase levels (114 UI/L). Vitamin D and calcium supplementation (1g/day) were started with efficiency on laboratory results,

## NEONATAL MANAGEMENT AND EVOLUTION

The girl was born at home, at 37 weeks of gestational age. It was a fast unplanned vaginal delivery, inducing cranial trauma at birth in the baby. She was SGA with 1.7 kg weight, 37 cm height. Clinical examination and radiographs confirmed OI with bowing deformities of long bones, blue sclera. She presented plagiocephaly and an important defect of ossification of the skull in occipital, fronto-parietal and temporal regions. Brain computed tomography performed for cranial injury at birth, confirmed that (Table 1). 25OH vitamin D, low at birth (16 ng/ml) was supplemented and feeding was optimized. The first fracture occurred at 1 month, without any trauma. We started treatment with zoledronate injections every 3 months. She is now 20 month-old, with the occurrence of 6 lower-limb fractures, 4 upper limb fractures and 2 vertebral fractures. She presents hypotonia, motor delay, mild head circumference and severe growth retardation (64 cm, -4 SDS) (Fig1). Cranial ossification has clinically improved. It was confirmed on CT scan (Table 1): ossification defect is limited to the median part of the skull and numerous wormian bones have appeared. DEXA scan values are still low: 0,249 g/cm<sup>2</sup> lumbar spine density.

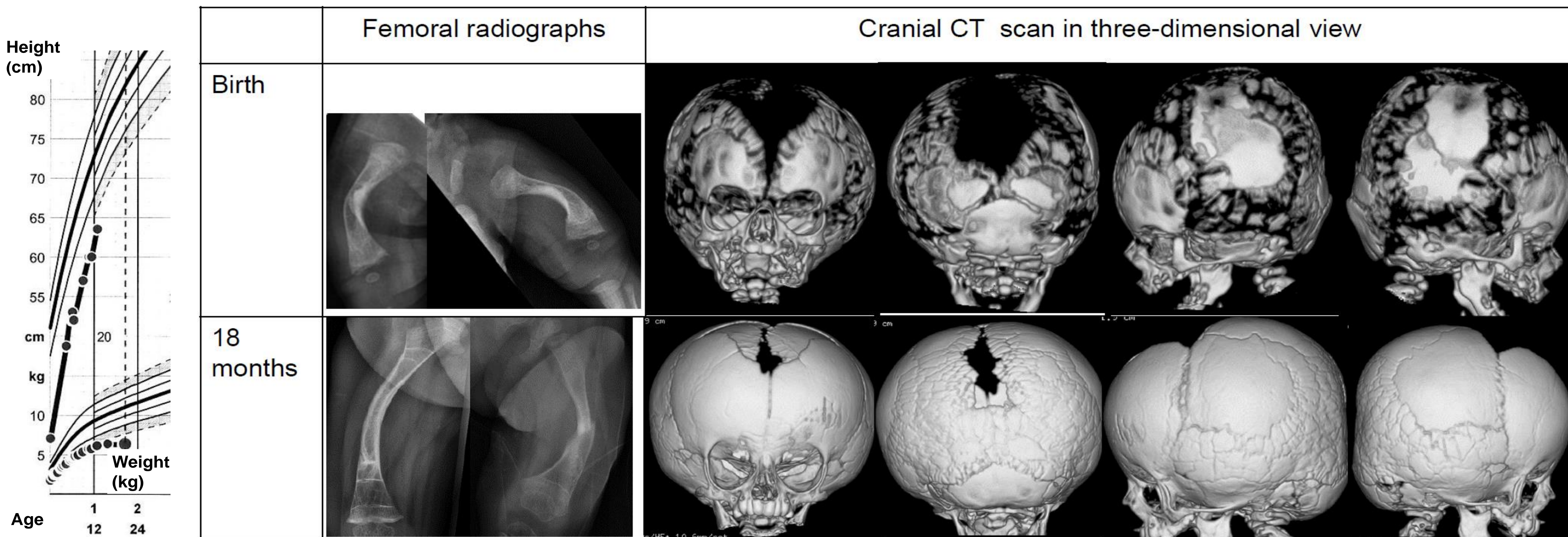


Fig1-Growth curves

Table1- Femoral radiographs and cranial CT scan evolution

## CONCLUSION

During pregnancy, the mother had vitamin D deficiency and lack of calcium intake. In our case, it can have delayed cranial membranous ossification and have impaired bone skeletal mineralization with a higher fracture rate in the neonate than in her mother. The low vitamin D and calcium status of the mother may have turned the familial phenotype into a more severe one for the neonate on cranial ossification and on the rate of fracture despite early bisphosphonate treatment. In OI pregnant women, early following up of bone mineralization and of vitamin D and calcium status, is mandatory with a multidisciplinary approach [2]. OI women should be informed of the risk of mineralization defect of fetal skeleton and its consequences in case of vitamin D or calcium deficiency. During transition to adult, it is necessary to explain to OI patients the issues of medical following and treatment in adulthood.

## BIBLIOGRAPHY

- 1 - Collectif (Collège National Des Gynécologues et Obstétriciens Français). Supplémentation au cours de la grossesse - Recommandations pour la pratique clinique, 5 décembre 1997 Ed. CNGOF Paris, 1997. <http://www.cngof.asso.fr>.
- 2-Management of osteogenesis imperfecta type I in pregnancy, a review of clinical practice applied to medical practice. Cozzolino M, Perelli F, Maggio L et al. Arch Gynecol Obstet. 2016 Apr Jun;293(6):1153-9