

# THE PREVALENCE OF HYPERTENSION AND ITS RELATIONSHIP TO GLYCEMIC CONTROL IN CHILDREN WITH TYPE 1DIABETES MELLITUS

Doaa Khater<sup>1,2</sup>, Magdy Omar<sup>2</sup>

<sup>1</sup>Sultan Qaboos University Hospital, Muscat, Oman, <sup>2</sup>Alexandria University, Faculty of Medicine, pediatric edocrine and diabetes unit.



## INTRODUCTION

Type 1 diabetes (T1DM) is a chronic disease with many chronic complications as nephropathy, retinopathy and neuropathy or macrovascular complications as coronary artery disease and peripheral vascular disease due to the effects of hyperglycemia and dyslipidemia on vascular endothelial function. Moreover, in patients with T1DM, hypertension (HTN) is a significant contributor to the development of both micro- and macrovascular complications

## OBJECTIVES

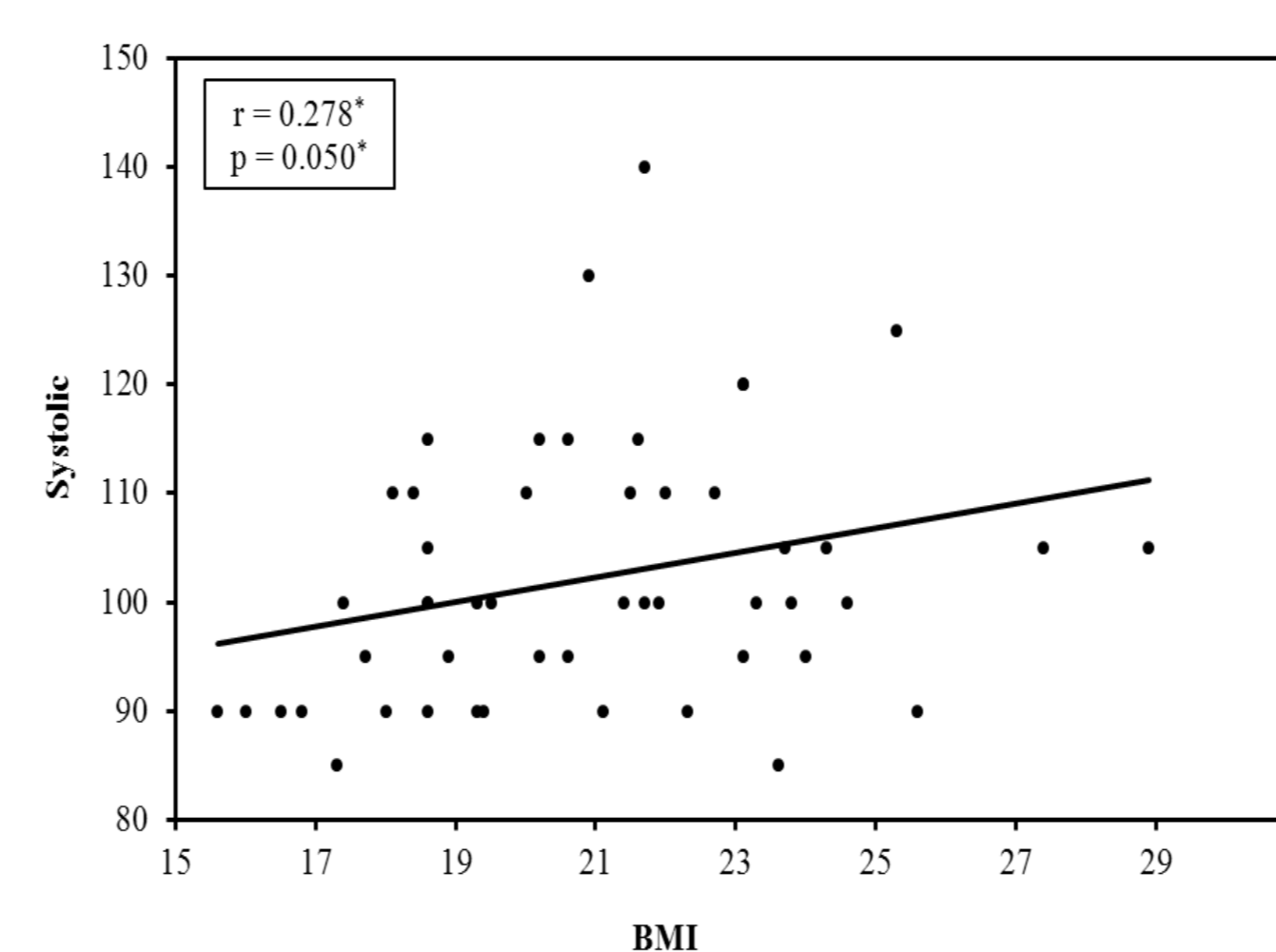
To determine the prevalence of HTN in children with T1DM attending pediatric diabetes clinic and to study the relation between HTN, glycemic control and presence of other chronic complications such as nephropathy and retinopathy in these children with T1DM.

## METHODS

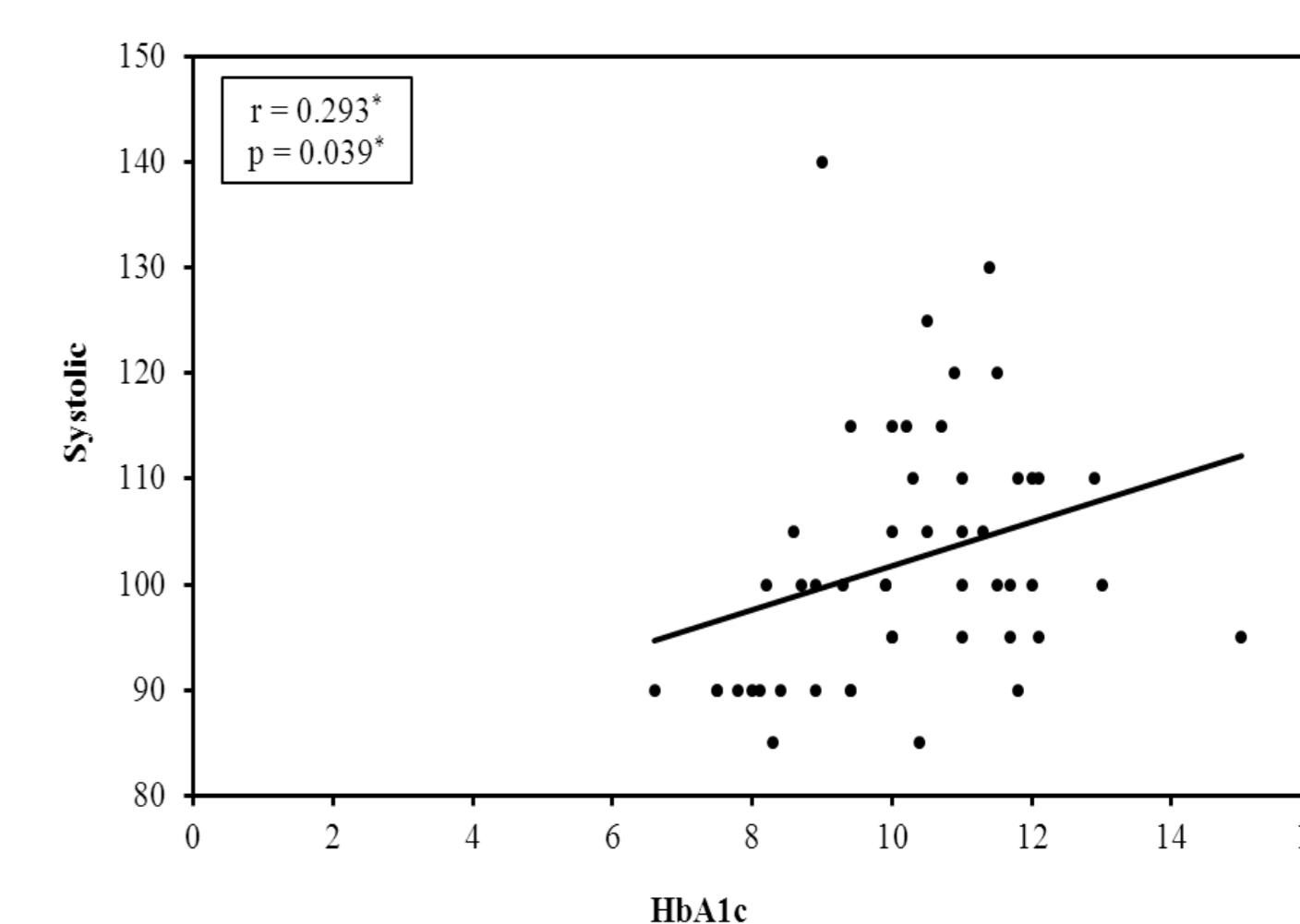
Fifty children and adolescents with T1DM attending our diabetes clinic were subjected to history and full examination including blood pressure (BP) measuring and classification according to the National High Blood Pressure Education Program Working Group on High Blood Pressure in Children and Adolescents to: Pre-hypertensive, Stage 1 HTN and Stage 2 HTN. HbA1c, microalbuminuria, lipid profile and ophthalmoscopy were done

## RESULTS

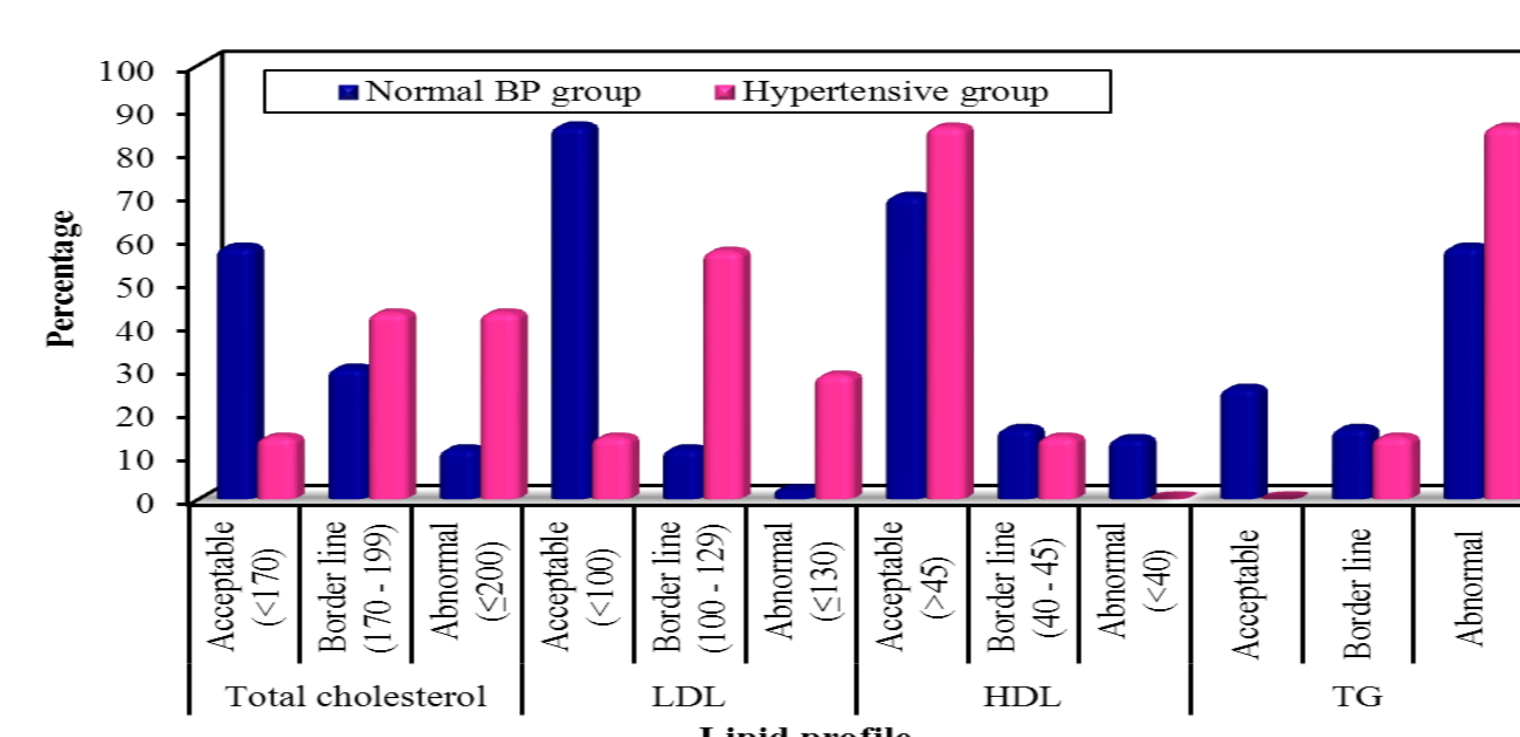
Seven out of the 50 cases with T1DM (14%) had HTN. Most of the hypertensive cases were post pubertal (6 cases: 3 cases in Pre HTN stage, 2 in Stage 1 HTN and 1 in Stage 2 HTN). Significant positive correlation between BMI and systolic BP was found ( $p < 0.05$ ). HbA1c was significantly higher among the post-pubertal hypertensive group compared to pre-pubertal group ( $p \leq 0.05$ ) with significant positive correlation between HbA1C and systolic BP in the whole group ( $p = 0.039$ ). Early nephropathy was detected in 85.7% of the hypertensive group ( $p \leq 0.001$ ). The hypertensive diabetic children had a higher mean of lipid profile parameters ( $p \leq 0.05$ ) with significant positive correlation between cholesterol level and systolic BP in the whole group as ( $p = 0.002$ ). Only one case had diabetic retinopathy.



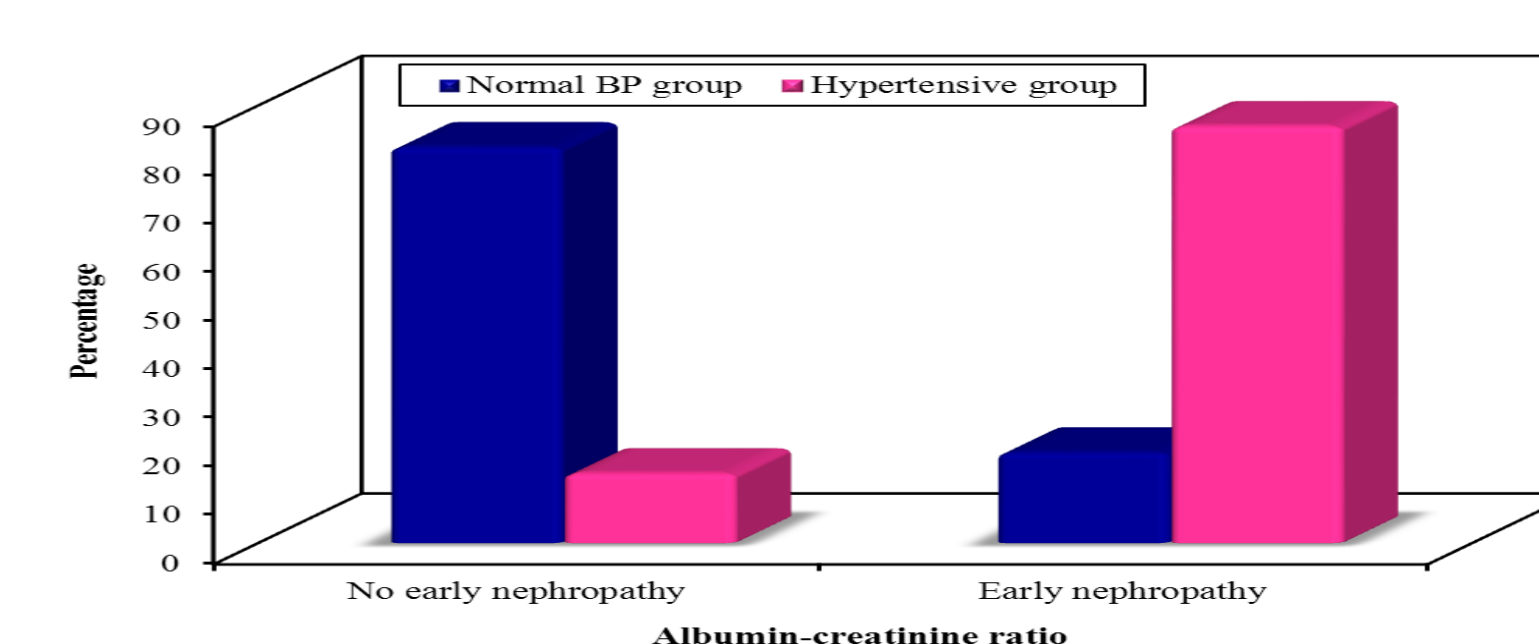
Correlation between BMI and systolic BP



Correlation between HbA1c and systolic BP



Comparison between the normotensive and hypertensive groups regarding lipid profile



Comparison between the normotensive and hypertensive groups regarding early nephropathy

## CONCLUSION

HTN is common among T1DM children and their blood pressure should be screened annually to guard against the development and progression of chronic complications

## REFERENCES

- 1-Sowers JR, Epstein M, Frohlich ED. Diabetes, hypertension, and cardiovascular disease: An update. Hypertension 2001; 37:1053-9.
2. Romero P, Salvat M, Fernandez J, Baget M, Martinez I. Renal and retinal microangiopathy after 15 years of follow-up study in sample of Type 1 diabetes mellitus patients. J Diabetes Complications 2007; 21:93-100.
3. Raile K, Galler A, Hofer S. Diabetic nephropathy in 27,805 children, adolescents, and adults with type 1 diabetes: Effects of diabetes duration, A1C, hypertension, dyslipidemia, diabetes onset, and sex. Diabetes Care 2007; 30:2523-8.13.
4. Ceriello A: New insights on oxidative stress and diabetic complications may lead to a "causal" antioxidant therapy. Diabetes Care 2003; 26:1589-96.
5. Chatterjee M, Speiser PW, Pellizzari M, Carey DE, Fort P, Kreitzer PM, Frank GR. Poor glycemic control is associated with abnormal changes in 24-hour ambulatory blood pressure in children and adolescents with type 1 diabetes mellitus. J. Pediatr. Endocrinol Metab 2009; 22(11):1061-7.
6. De Boer IH, Kestenbaum B, Rue TC. Insulin therapy, hyperglycemia and hypertension in type 1 diabetes mellitus. Arch Intern Med 2008; 168:1867-73.
7. Dongahue KC, Wadwa PR, Dimeglio LA, Wong TY, Chiarelli F. Microvascular and Macrovascular complications in children and adolescents. Pediatric Diabetes 2014; 15(20):257-69.

