

# Tumor induced osteomalacia, a rare and complex condition with more treatment options, exemplified in two patients

NH Birkebæk

Department of Pediatrics & Steno Diabetes Center Aarhus  
Aarhus University Hospital, Denmark

## INTRODUCTION

Tumor induced osteomalacia (TIO) is clinically characterized by bowed, short and painful legs in children and bone pain if onset in adolescent or adult life. Paraclinical, TIO is characterized by hypophosphatemia, low levels of 1.25-OH<sub>2</sub>-vitamin D (1.25 OH<sub>2</sub>D), and elevated levels of fibroblast growth factor 23 (FGF23). TIO is due to tumor secretion of FGF23, which inhibits phosphate re-absorption in the proximal renal tubules and the hydroxylation of 25 OH vitamin D to 1.25 OH<sub>2</sub>D. The FGF23 tumors are of bone or mesenchymal origin.

## AIM

To present the diverse phenotype and treatment options of TIO, we describe the diagnostics and treatment in two children with TIO.

## METHODS

Patient one, a girl, was referred for severe rickets aged 2½ years old. She had a large diffuse hemangioma on the left side of the neck. Patient two, a girl, had been followed for mental retardation and epilepsy of unknown origin, and was referred for leg pain and hypophosphatemia aged fourteen years old. Both patients had healthy, unrelated Caucasian parents.

## RESULTS

Both patients had low plasma phosphate and 1.25 OH<sub>2</sub>D, elevated alkaline phosphatase and urine phosphate excretion, and a highly increased plasma FGF23. A blood sample taken directly from the haemangioma of patient one revealed a 25-fold increase in FGF23. Direct sequencing of the PHEX and FGF23 genes of both patients did not reveal any gene variants. Magnetic resonance (MR) angiography in patient one showed a diffuse haemangiomatic tumor with intraosseous venous malformation in the left skull base and communication with the middle cerebral vein (*Figure 1*). Due to tumor size and location, surgery was not an option. A treatment trial with intravascular bleomycin sclerotherapy did not reduce tumor size. Treatment was alphacalcidol and phosphate supplementation for 15 years. January 2020 treatment was switched to burosumab (a FGF23 antibody). The current dose is 1.5 mg per kg every 3 weeks, which have resulted in normal 1.25OH<sub>2</sub>D and near normal fasting plasma phosphate and FGF23 (*Table 1*).

PET/CT and MRI in patient two revealed an osteolytic tumor of 2.3x3.1x3.6 cm<sup>3</sup> in the left scapula (*Figure 2*). Tumor was surgically removed, leg pain disappeared, and all paraclinical data normalised (*Table 1*).

FIGURE 1

MRI with a vascular, predominantly venous malformation localised to the parapharyngeal venous plexus on the left side. The larynx is slightly displaced to the right side, but there is no obstruction of the airway.

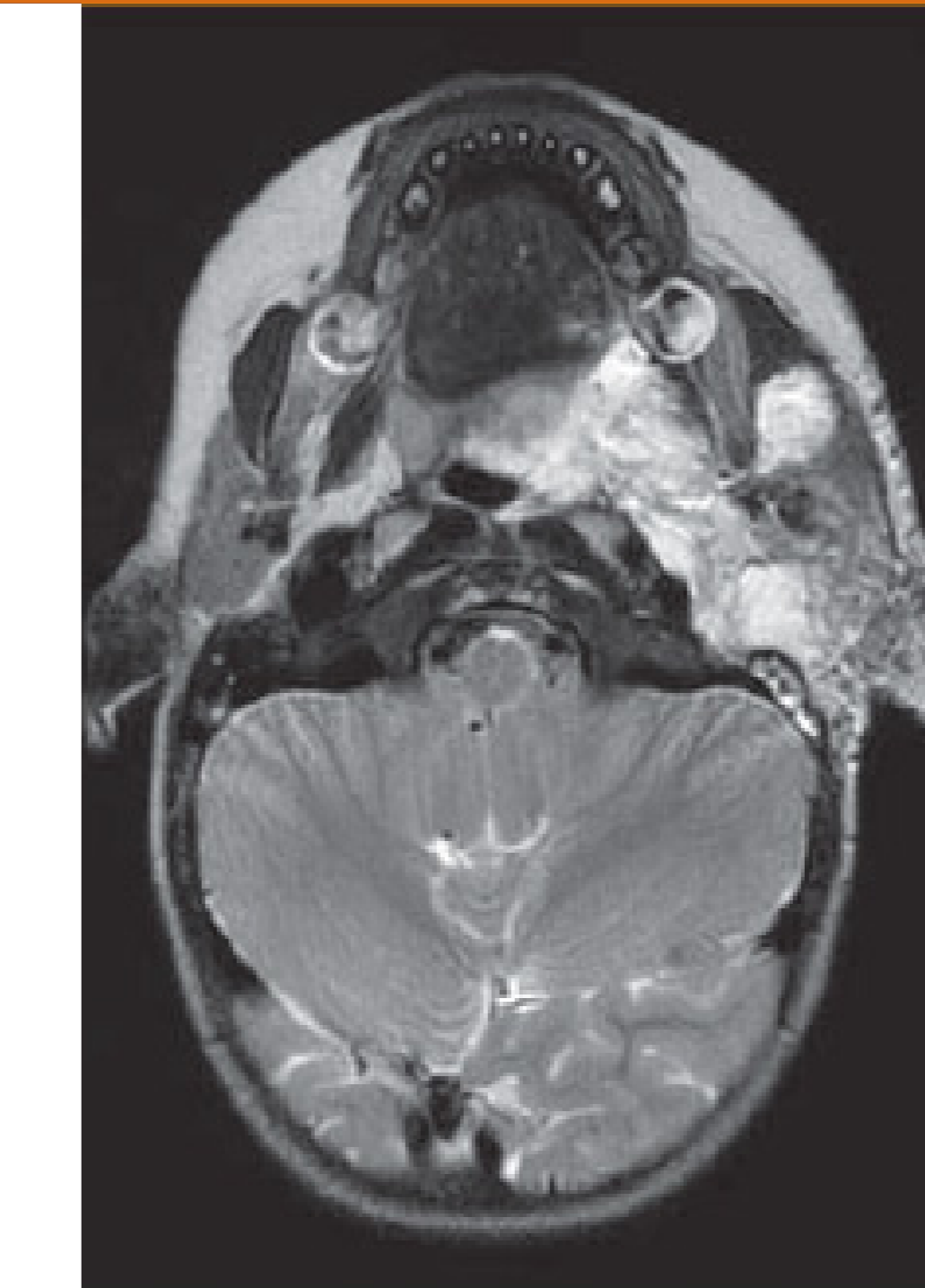


FIGURE 2

MRI with contrast of the left scapula showing the tumor.

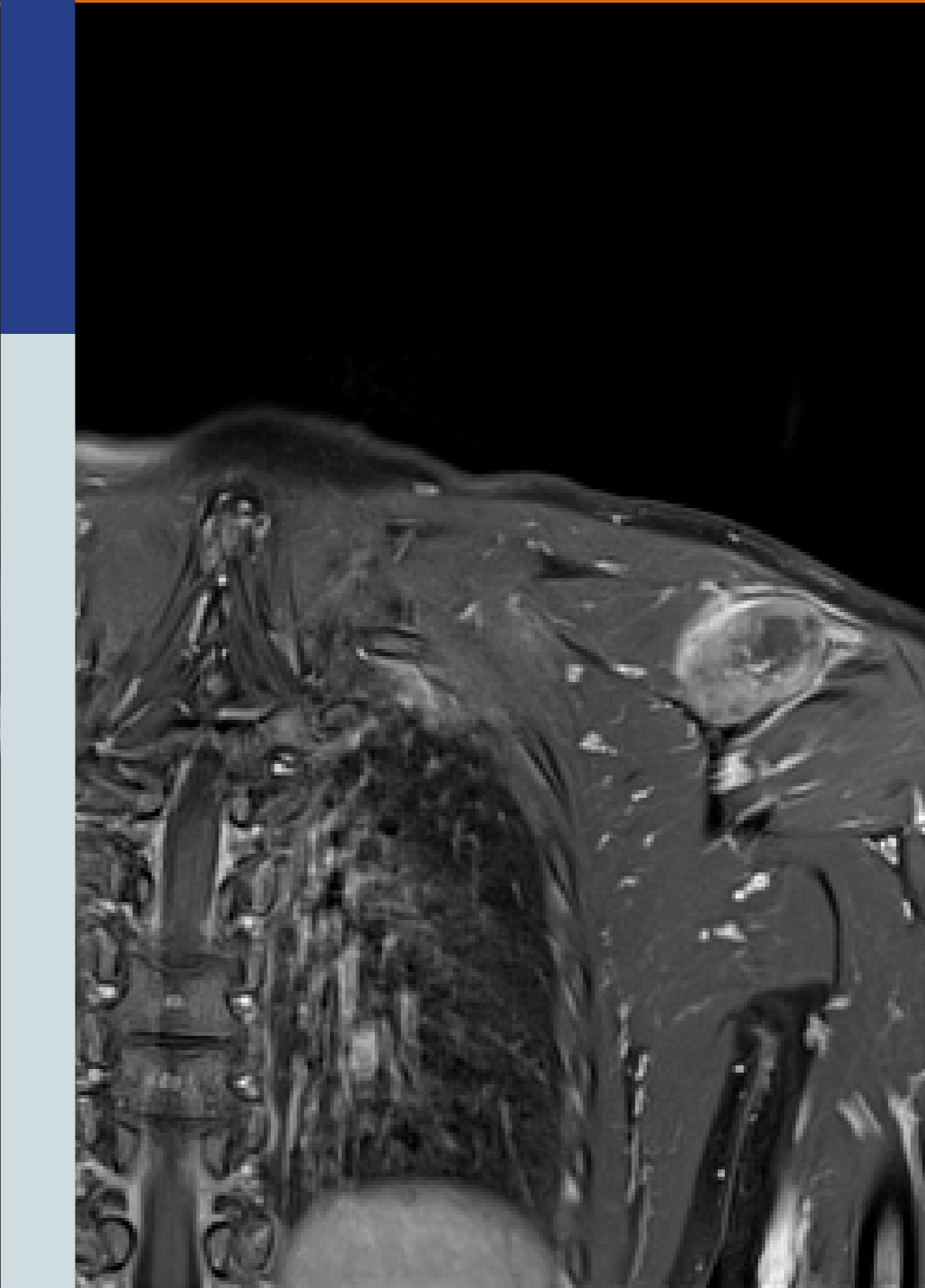


TABLE 1

	Reference values	PT 1					PT 2	
		Day 0*	Day 14	Day 14	Day 28	Day 21	Before surgery	After surgery
Alkaline phosphatase	35-105 U/L	300	277	263	270	193	1001	68
1.25 OH <sub>2</sub> D	60-180 pmol/L	93	100	162	155	152	34	151
Phosphate	0.76-1.41 mol/L	0.37	0.7	0.82	0.73	0.73	0.47	1.2
FGF 23	23-91 ng/L	272	194	81	175	116	1200 RU/ml (<100)	81
Burosumab dose mg/kg		0	0.4	1.5	1.5	1.5		

\* After pausing conventional treatment 7 days.

## CONCLUSIONS

TIO is a very rare condition, and the tumor may be difficult to localize. Treatment is easy if removal of the tumor by surgery is possible. If the tumor cannot be removed the FGF23 antibody burosumab may be an effective treatment option.

Kyowa Kirin has sponsored the Burosumab treatment.