

DIFFERENT FACES OF MINIPUBERTY IN PRETERM TWIN GIRLS



G. PEPE¹, M. CALAFIORE², M.R. VELLETRI², I. MONDELLO², A. LI POMI¹, M. WASNIEWSKA¹

1. University of Messina, Messina, Italy

2. Bianchi-Melacrinò-Morelli Hospital, Reggio Calabria, Italy

INTRODUCTION

Minipuberty (MP) consists in a postnatal activation of hypothalamic-pituitary-gonadal (HPG) axis, which occurs physiologically in both sexes during the first months of life. FSH and LH peak between 1 and 3 months, stimulating sex hormones secretion. In preterm infants, MP might lead to a stronger and more protracted hormonal stimulation, even if specific literature data are limited and not univocal. Immaturity of the hypothalamic feedback has been suggested as a possible mechanism for this phenomenon, although its biological meaning is still unknown. We present a case of MP observed in a preterm girl, in comparison to her twin sister.

CASE REPORT

A girl born at 31 weeks of gestation presented with **severe edema in the vulva and swelling labia major and minor**, appeared at one month of life. She was the second twin of a monozygotic diamniotic pregnancy, born by cesarean section (Apgar scores 8-9) and adequate for gestational age (AGA). She was admitted to NICU for prematurity, mild distress respiratory syndrome and neonatal jaundice. She had no family history for precocious puberty and no personal history of any hormonal therapy.

Laboratory evaluations highlighted **central activation of the HPG axis**, with elevated LH (4.66 mIU/ml) and FSH (2.74 mIU/ml) and increased estradiol levels (1152.1 pmol/l). Adrenal steroidogenesis and serum electrolytes were within the normal range, thus excluding congenital adrenal hyperplasia. Thyroid function, prolactin, alpha-fetoprotein, and beta-human chorionic gonadotropin levels were normal. Pelvic ultrasonography and MRI showed increased uterine length (4.5 cm), endometrial thickness of 4 mm, enlarged ovaries with multiple follicles bilaterally and three ovarian cysts (measuring 8 mm, 16 mm and 9 mm of diameter, respectively). Brain imaging was unremarkable.

Repeated hormonal workup over the course of 6 months showed decreasing trend of estradiol levels (*table 1*). Clinical and sonographic pubertal signs also spontaneously regressed over time (*figure 1a-1b*).

The same hormonal evaluation was performed in her twin sister, displaying mildly elevated levels of FSH (3.23 mIU/ml), LH (2.23 mIU/ml) and estradiol (289.6 pmol/l), without evidence of pubertal clinical signs.

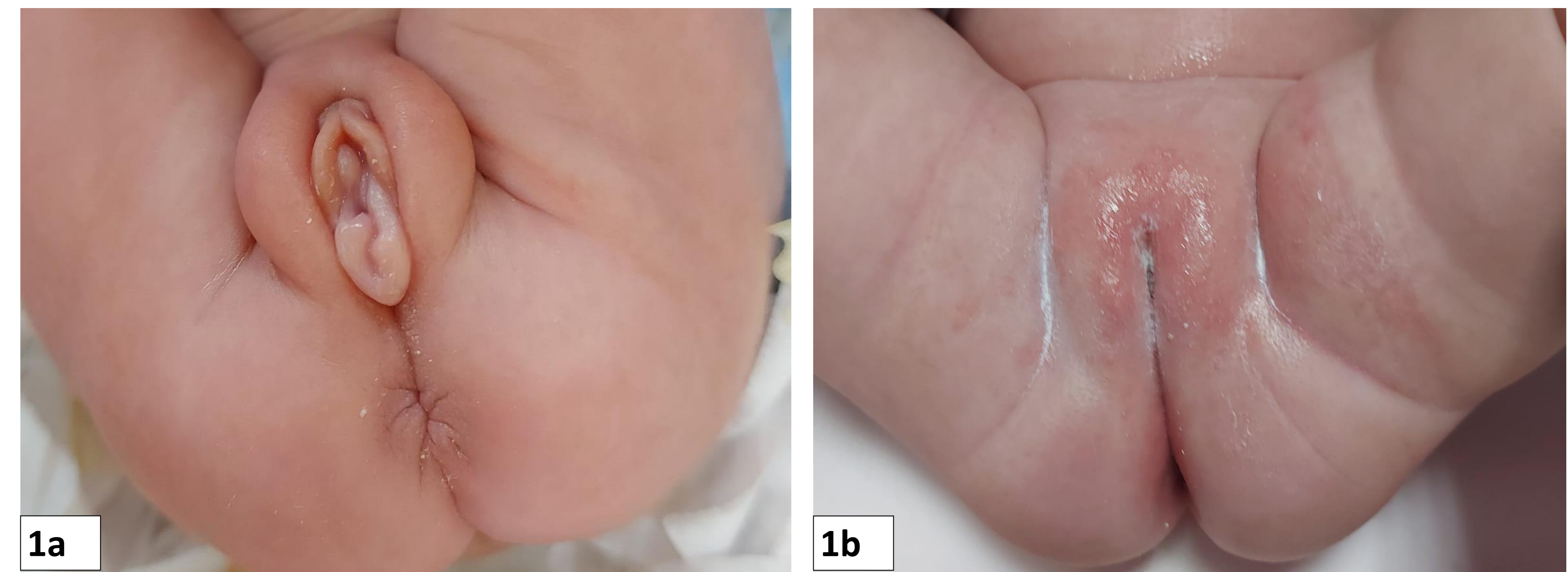


Figure 1a-1b. Severe edema of the external genitalia at one month of age in a preterm AGA twin girl with minipuberty (1a). Clinical resolution of the pubertal signs after 6 months follow-up (1b).

Age (months)	LH (mIU/l)	FSH (mIU/l)	Estradiol (pmol/l)
1	4.66	2.74	1152.10
3	3.61	1.99	535.70
6	7.92	4.32	121.69

Table 1. Serum levels of LH (mIU/l), FSH (mIU/l) and Estradiol (pmol/l) detected during 6 months follow-up.

CONCLUSIONS

Preterm birth does not seem to influence the timing of MP occurrence. The amplitude of postnatal **HPG activation might be exacerbated in preterm babies**, with evidence of puberty changes in clinical, laboratory and sonography data. The spontaneous resolution, together with the exclusion of other causes, is suggestive for MP of infancy.