Denosumab therapy for giant cell granuloma in a paediatric patient: using quantification of Tc99m-MDP uptake on SPECT imaging to guide treatment.

Laura Wade[1], Kathryn Siddle[1], Tobi Aderotimi[1], Suzanne Armitage[1], Joanne Blair[1], Craig Munns[2], Nik Barnes[1], Laurence Abernethy[1], Poonam Dharmaraj[1]

[1]Alder Hey Children's NHS Foundation Trust, Liverpool, United Kingdom. [2]Children's Hospital at Westmead, Sydney, Australia

ESPE 2021
The 59th Annual Meeting Online
22-26 September 2021

NHS Alder Hey Children's NHS Foundation Trust

INTRODUCTION

Giant cell granulomas (GCG) are uncommon bony lesions that most commonly affect the maxilla and mandible; whilst generally benign they can be disfiguring to the face.(1, 2) Historically, GCGs have been treated with steroids or bisphosphonates to try and avoid surgical resection. Over recent years denosumab, a human monoclonal antibody which acts against the receptor activator of nuclear factor kappa B ligand, has been shown to be effective in treating GCGs, although there are risks in using the drug in growing children.(1-7) We present a case of a child treated with denosumab using quantification of technetium 99m-methyl diphosphonate (Tc99m-MDP) uptake on SPECT imaging to guide treatment.

CONCLUSIONS

This case report adds further support for the use of denosumab in the treatment of GCG in paediatric patients. Imaging using SPECT with semi-quantitative analysis of Tc99m-MDP uptake allowed for valuable assessment of denosumab effect which was difficult to appreciate on standard MRI/SPECT images.

CASE PRESENTATION

An 11-year-old female presented with an oral lesion. CT scan and biopsy confirmed a diagnosis of GCG of the maxilla. Initial treatment with weekly steroid injections resulted in a short period of stability before growth progression returned. MRI/SPECT imaging showed an expansile, lytic left maxillary lesion with increased Tc99m-MDP uptake, measuring 36mm x 41mm x 42mm. Zoledronic acid was commenced, after which a small reduction in lesion size was noted, although MRI/SPECT imaging after a year of treatment showed no change with increased sclerosis and increased Tc99m-MDP uptake.

Denosumab was commenced at 60mg every 4 weeks (increased to 120mg after 11 months) by subcutaneous injection with calcium and vitamin D supplementation. The patient has maintained normal renal function and bone chemistry whilst on denosumab , bone density is within the normal range for age and no signs of osteonecrosis of the jaw. After 14 months of denosumab, the patient had suppressed bone turnover markers, MRI scan showed lesion size was unchanged but with increased sclerosis. However, semi-quantitative analysis showed a reduction in the ratio of Tc99m-MDP uptake in the lesion, compared to normal bone, from 4.9 to 1.4.

The lesion has clinically reduced after 19 months of denosumab with only mild facial asymmetry. Denosumab weaning will be gradual to avoid rebound hypercalcaemia after treatment cessation. In line with case reports in the literature, the patient will then receive two doses of zoledronic acid. Ongoing 3-6 monthly SPECT scans will help to guide whether denosumab needs to be restarted in the future.

MRI & SPECT Nov 2016
Post steroid injection (pre zoledronate) – Lesion size 3.6x4.1x4.2mm
Inhomogenous uptake with foci of intense uptake visible around the posterior, superior and media margins.

MRI & SPECT Nov 2017
11 months of zoledronate lesion size 3.7x3.3x3.8mm
Extensive new sclerosis within the lesion on superomedial aspect, significant heterogenous increase in uptake within the lesion.
Tc99m-MDP uptake 4.9

MRI & SPECT Feb 2019
26 months of zoledronate lesion size 3.7x3.5x3.7mm
Avid uptake throughout the lesion consistent with continuing bone turnover.
Tc99m-MDP uptake 4.2

CT & SPECT Feb 2020
6 months of denosumab tx lesion size 3.8x4.2x4mm
Lesion now more uniformly dense, SPECT imaging shows increased uptake compared to previous scan.
Tc99m-MDP uptake 1.7

MRI & SPECT Nov 2020
14 months of denosumab lesion size 3.5x3.7x3.7mm
Persisting avid uptake subjectively more heterogenous than previously, areas of less uptake centrally, suggesting some degree of reduced bone turnover.
Tc99m-MDP uptake 1.2

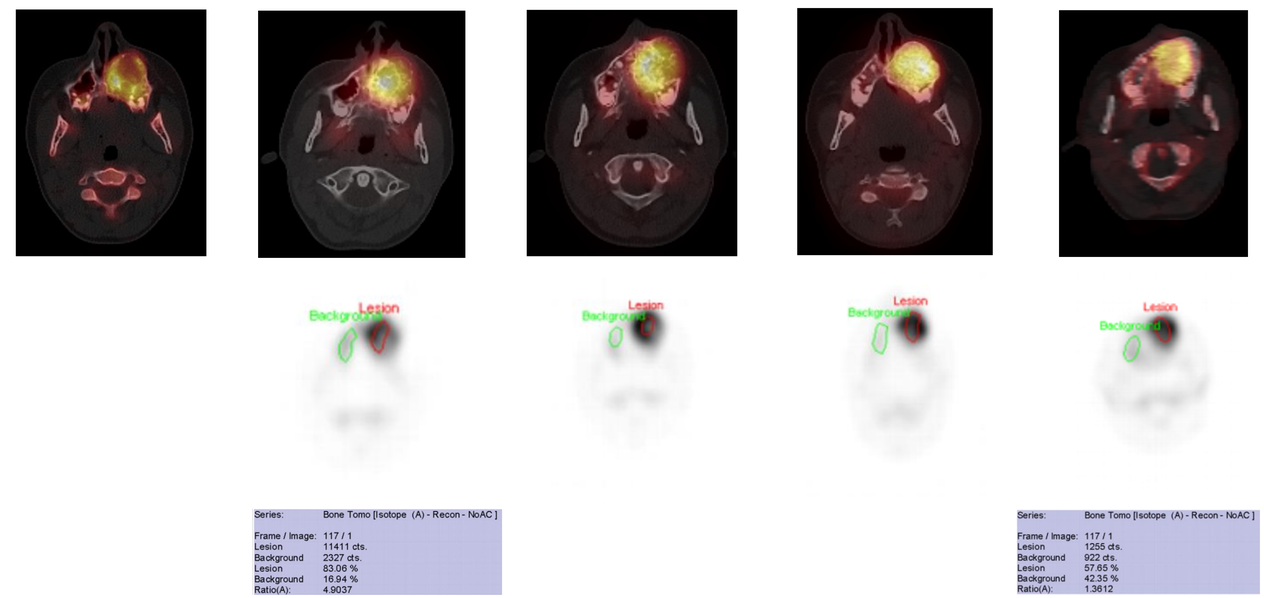

REFERENCES

1. Choe M, Smith V, Okcu MF, Wulff J, Gruner S, Huisman T, et al. Treatment of central giant cell granuloma in children with denosumab. Pediatr Blood Cancer. 2021;68(3):e28778.
2. Mohan RP, Verma S, Agarwal N, Singh U. Central giant cell granuloma: a case report. BMJ Case Rep. 2013;2013.
3. Bredell M, Rordorf T, Kroiss S, Rucker M, Zweifel DF, Rostetter C. Denosumab as a Treatment Alternative for Central Giant Cell Granuloma: A Long-Term Retrospective Cohort Study. J Oral Maxillofac Surg. 2018;76(4):775-84.
4. Gupta B, Stanton N, Coleman H, White C, Singh J. A novel approach to the management of a central giant cell granuloma with denosumab: A case report and review of current treatments. J Craniomaxillofac Surg. 2015;43(7):1127-32.
5. Hameed M, O'Connell JE, Rogers SN. Management of an aggressive giant cell granuloma of the mandible with denosumab: a case report. Br J Oral Maxillofac Surg. 2019;57(7):691-3.
6. Mariz B, Migliorati CA, Alves FA, Penteado FM, Carvalho NPF, Santos-Silva AR, et al. Successful denosumab treatment for central giant cell granuloma in a 9-year-old child. Spec Care Dentist. 2021.
7. Uday S, Gaston CL, Rogers L, Parry M, Joffe J, Pearson J, et al. Osteonecrosis of the Jaw and Rebound Hypercalcemia in Young People Treated With Denosumab for Giant Cell Tumor of Bone. J Clin Endocrinol Metab. 2018;103(2):596-603.

ACKNOWLEDGEMENTS

We'd like to thank Professor Munns for his generosity in sharing his experience in managing giant cell granulomas and protocol for Denosumab use.

CONTACT INFORMATION

Dr Poonam Dharmaraj – Consultant Endocrinologist
Poonam.Dharmaraj@alderhey.nhs.uk