

SPONTANEOUS RESHAPING OF VERTEBRAL FRACTURES IN AN ADOLESCENT WITH OSTEOPENIA IMPERFECTA

R. MONTERO-LOPEZ, E. LAURER, K. TISCHLINGER, T. HÖRTENHUBER, W. HÖGLER
Department of Paediatrics and Adolescent Medicine, Johannes Kepler University Linz, Linz, Austria

INTRODUCTION

Vertebral fractures (VF) are a common and severe finding in secondary and primary osteoporosis [1].

In children, VFs have the potential to reshape and regain their original configuration. Vertebral reshaping is a desired effect of bisphosphonate therapy (BP) in children who have sufficient remaining growth potential.

Spontaneous vertebral body reshaping (i.e., medication-unassisted) has been reported in patients with secondary osteoporosis [2].

Here we describe a case of spontaneous vertebral reshaping in an adolescent patient with osteopenia imperfecta (OI) with multiple vertebral fractures. To the best of our knowledge, this is the first reported case of spontaneous vertebral reshaping in an OI patient naïve to BP therapy.

CASE REPORT

This 17-year-old female had been diagnosed with **OI type I** aged 5 years (**COL1A1 mutation**) and reported more than 40 fractures. She had received regular physiotherapy but, due to parental reservations about medication, **never received BP** or any other bone active medication.

At the time of the first consultation, the patient had not sustained **any fractures since age 15y**, no back pain or other body pain. She had grown and matured normally. She had blue sclera but no dentinogenesis imperfecta or skeletal deformity apart from a slight right-convex scoliosis.

A **lateral spine X-ray** (Fig. 1, 17y) demonstrated transparent bones, with

a mild anterior reduction in the height of vertebral bodies T6 and T7. A bone density scan demonstrated total body BMD height-adjusted-score -2.1; subtotal BMC for height -1.3; lumbar spine BMAD -1.1.

Of great interest were previous **spine X-rays taken at age 6 years** (Fig. 1, 6y) at an external institution, which showed three VF at thoracic spine with moderate to severe deformities (Grade 2-3, modified Genant Semi-Quantitative [3]).

Therefore, the two lateral spine x-rays, taken 11 years apart, demonstrate that substantial **spontaneous vertebral reshaping** had occurred between age 6 and 17 years.

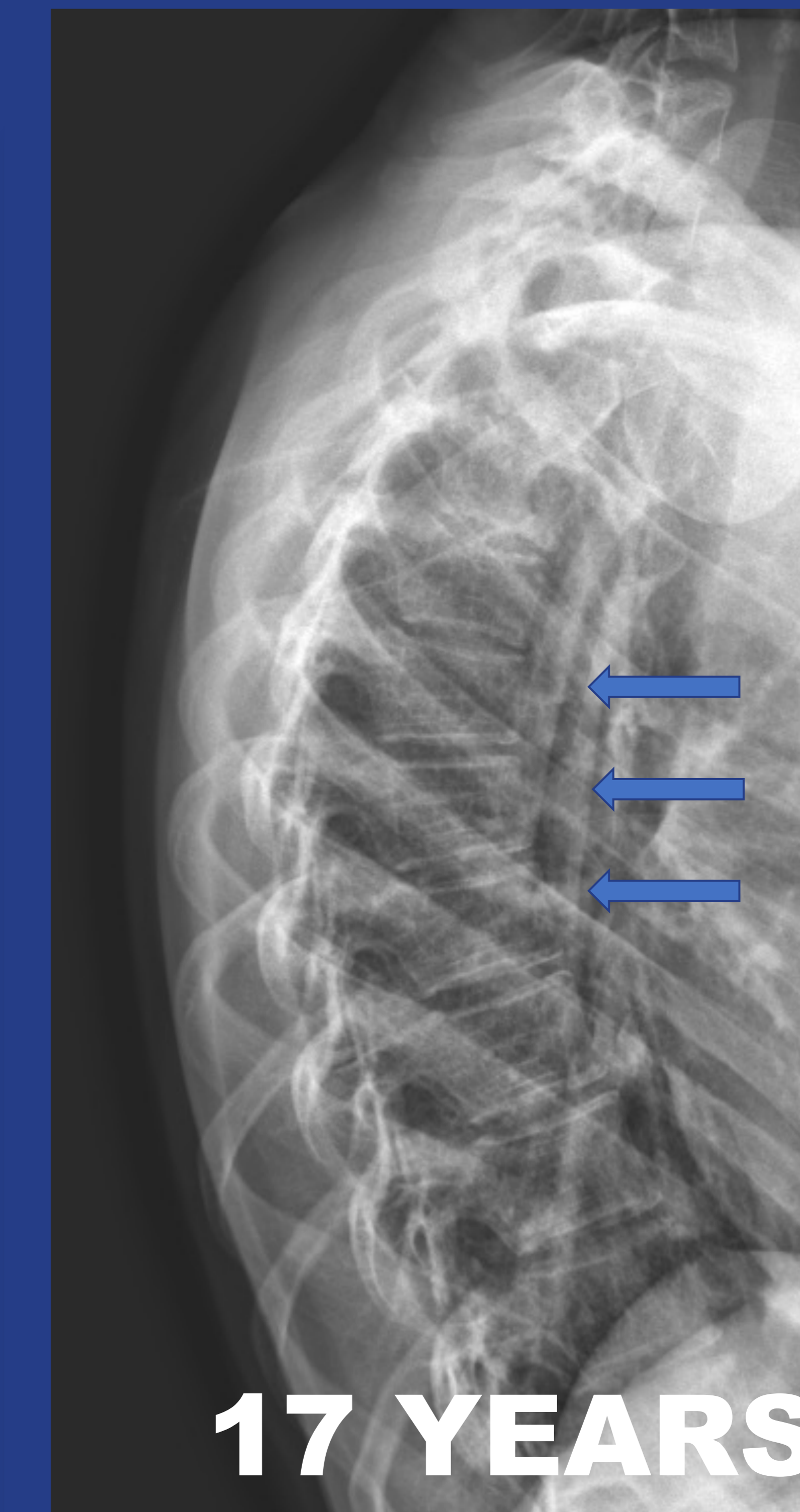
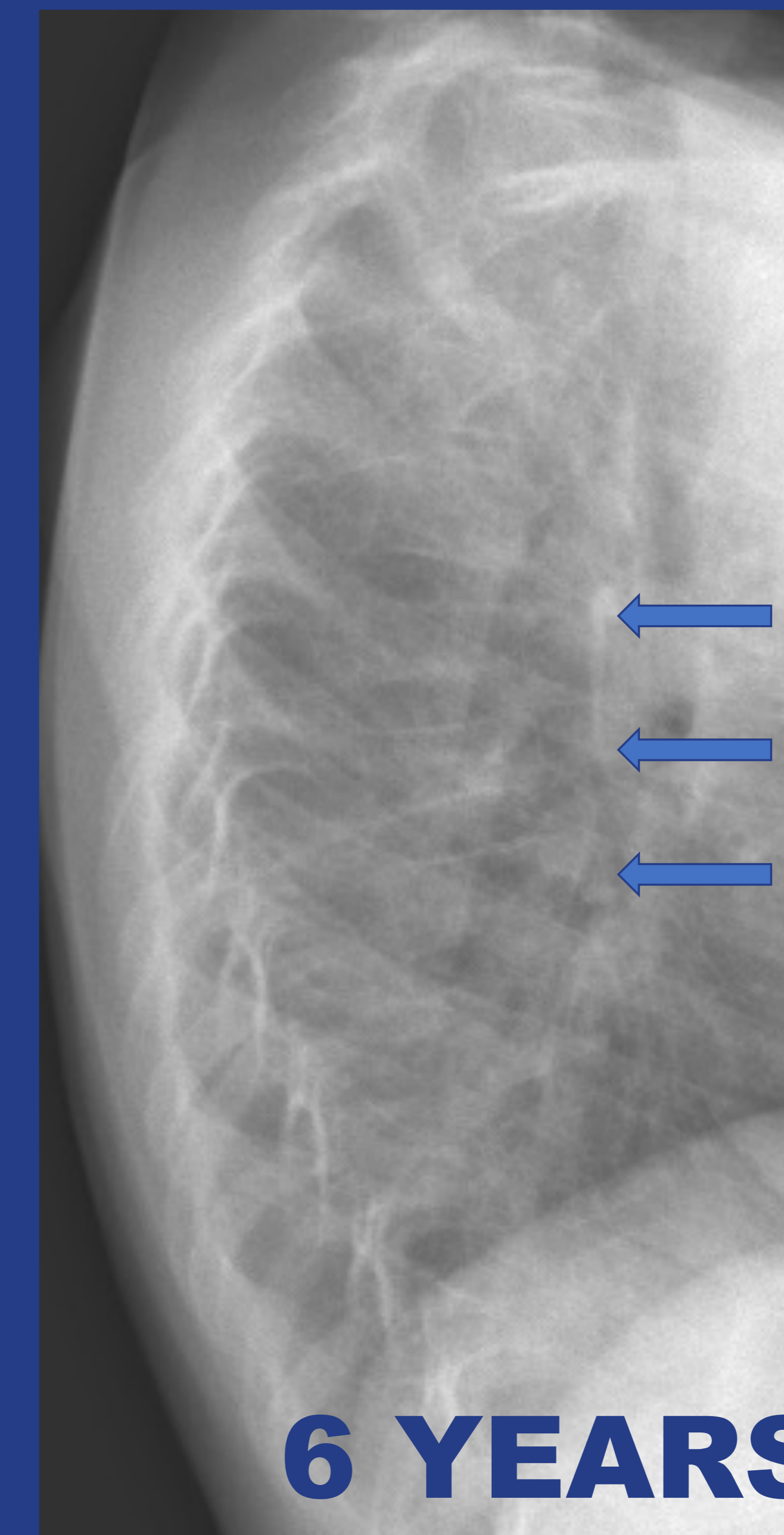


Figure 1. Lateral spine x-rays of the patient taken at the age of 6 years and 17 years. The arrows show the complete reshaping of the original three vertebral fractures

DISCUSSION

Vertebral reshaping is explained by the stabilization of BMD and residual growth capacity of children. Due to intrinsic bone defect in OI, spontaneous reshaping is unexpected, and so far unreported, in patients not treated with BP.

Although our patient reported more than 40 fractures, the presence of a normal stature, the absence of dentinogenesis imperfecta or bone deformities identified her as OI type I [4]. In addition, BMD was at the lower limit of normal, without intravenous BP. The patient's mutation (heterozygous *COL1A1* c.537_540delC) has not

been reported (<http://oi.gene.le.ac.uk>). This mutation could lead to a mild form of type I OI. We hypothesize that her remaining growth potential and pubertal hormones, physiotherapy and avoidance of trauma may have contributed to her exceptional spontaneous reshaping.

Despite this findings, BP should not be delayed in patients with VF and OI, due to their large impact on morbidity and mortality. Lateral vertebral assessment should be included in the regular assessment of children with OI to monitor vertebral body height and reshaping of VF.

REFERENCES

1. Ward LM, Weber DR, Munns CF, Högl W, Zemel BS. A Contemporary View of the Definition and Diagnosis of Osteoporosis in Children and Adolescents. *J Clin Endocrinol Metab.* 2020 May 1;105(5):e2088–97.
2. Lentle B, Ma J, Jaremko JL, Siminoski K, Matzinger MA, Shenouda N, Konji VN, Ward LM. The Radiology of Vertebral Fractures in Childhood Osteoporosis Related to Glucocorticoid Administration. *J Clin Densitom.* 2016 Jan-Mar;19(1):81-8.
3. Genant HK, Wu CY, van Kuijk C, Nevitt MC. Vertebral fracture assessment using a semiquantitative technique. *J Bone Miner Res.* 1993 Sep;8(9):1137-48.
4. Tournis S, Dede AD. Osteogenesis imperfecta - A clinical update. *Metabolism.* 2018 Mar;80:27-37.

RELEVANCE

This **unusual** case shows that spontaneous reshaping of VF can also occur in **BP-naïve OI patients**. Undoubtedly however, the persistent low bone mass predisposes this patient to future fractures.

CONTACT INFORMATION

Department of Paediatrics and Adolescent Medicine, Johannes Kepler University Linz, Kepler University Hospital, Krankenhausstraße 26- 30, 4020 Linz, Austria.

E-mail address: rodrigo.monterolopez@kepleruniklinikum.at

