

A PATIENT WITH TURNER SYNDROME(45X/46XX) AND CONGENITAL ADRENAL HYPERPLASIA:A CASE REPORT AND A LITERATURE REVIEW

YirouWang¹, Yu Ding¹, Yufei Xu¹, Yao Chen¹, Jian Wang¹, Xiumin Wang¹

1. Shanghai Children's Medical Center, Shanghai, China

INTRODUCTION

Turner syndrome is caused by partial or complete loss of the second sexual chromosome which leads to genital system malformation and infertility. 21-hydroxylase deficiency is a well-known cause of disorder of sexual development in genotypic female neonates. A 8-month-old patient suffering from both 45,X/46,XX Turner's syndrome and virilization form of CAH was referred to our hospital. She was born spontaneously at full-term with normal birth measurement. After birth, she showed normal in growth and development until her mom found ambiguous genitalia when she was 8-month-old. Genital examination revealed a 3cm phallus, normal external urethral orifice and incomplete fusion of labia. An association between Turner syndrome (TS) and Congenital Adrenal Hyperplasia (CAH) due to 21-hydroxylase deficiency is rare. The aim of our study is to report this patient and stress this rare possibility.

AIM

- ✓ Summarize a rare case of CAH combined with TS, through the description of clinical manifestations and treatment outcome to strengthen clinicians' understanding of this disease.
- ✓ And by comparing the similarities and differences between this patient and the reported case to further summarize the clinical characteristics of the two diseases occurring in one patient at the same time.

METHOD

Through genetic testing and literature review, we confirmed our diagnosis and summarized relevant experience to guide our clinical work.

RESULTS

The patient was 2 months old when she came at the first time for clinical check, for the ambiguous external genitalia with a hypertrophic clitoris still after her birth. The external genitalia was ambiguous: a clitoris was 1.5cm in length, absent labia majora and atretic opening of the vagina. Below the clitoris, the external orifice of urethra opening was normal. The result of karyotype was also made by outer hospital showed 45X/46XX, which revealed that this patient should be diagnosed with TS.

In this case, the sanger sequencing of CYP21A2 and karyotyping (including the sex determining region Y gene, SRY) must be verified to identify the etiology. Target sequencing of CYP21A2, followed by bioinformatics analysis, filtering against public databases, and biological analysis showed a homozygote missense mutation located at c.518T>A, p.Ile173Asn. At the same time, the karyotyping result showed a pattern of 45X/46XX like before, while the result of SRY analysis was negative. Therefore, we clarified that this girl was diagnosed with CAH combining with TS.

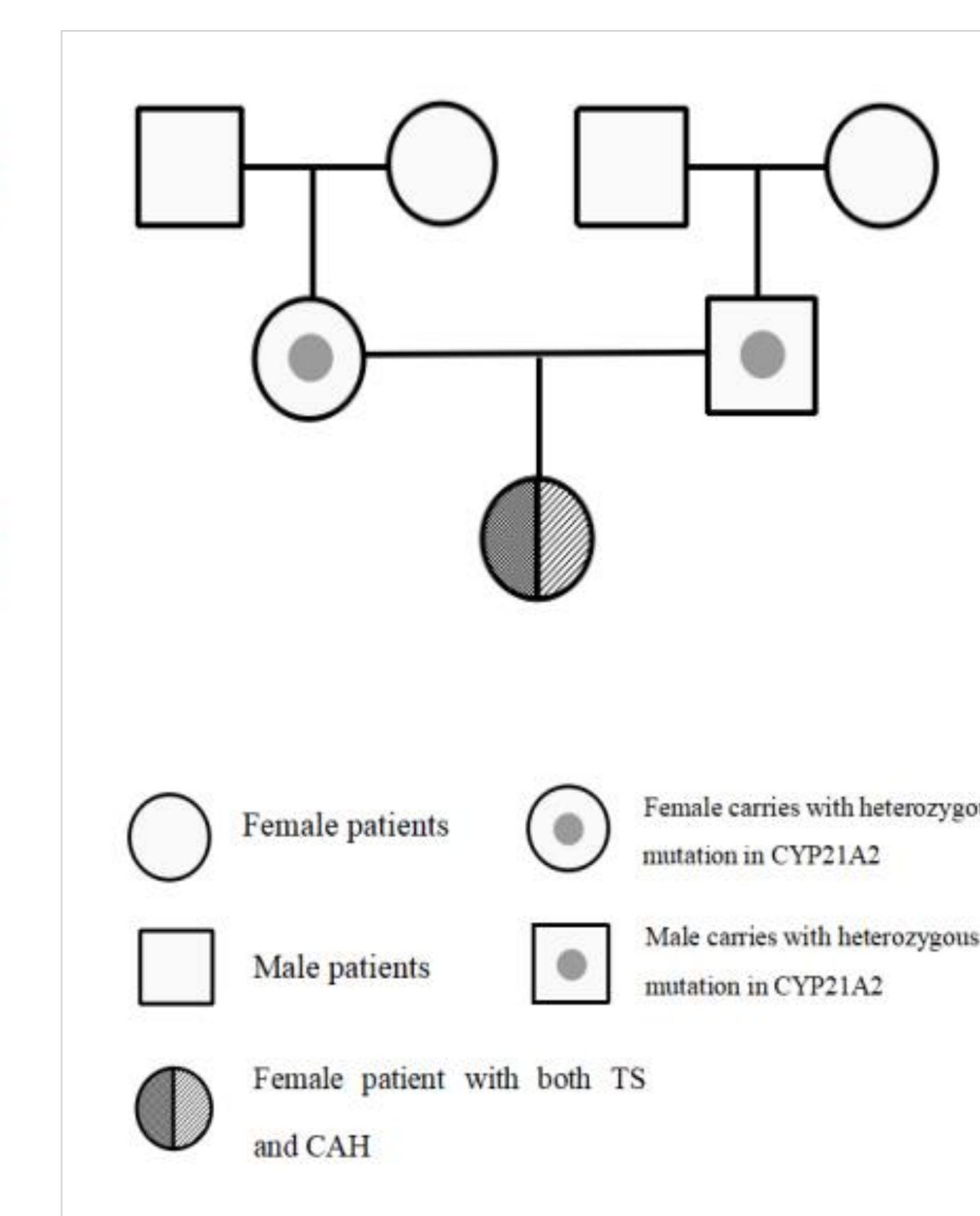
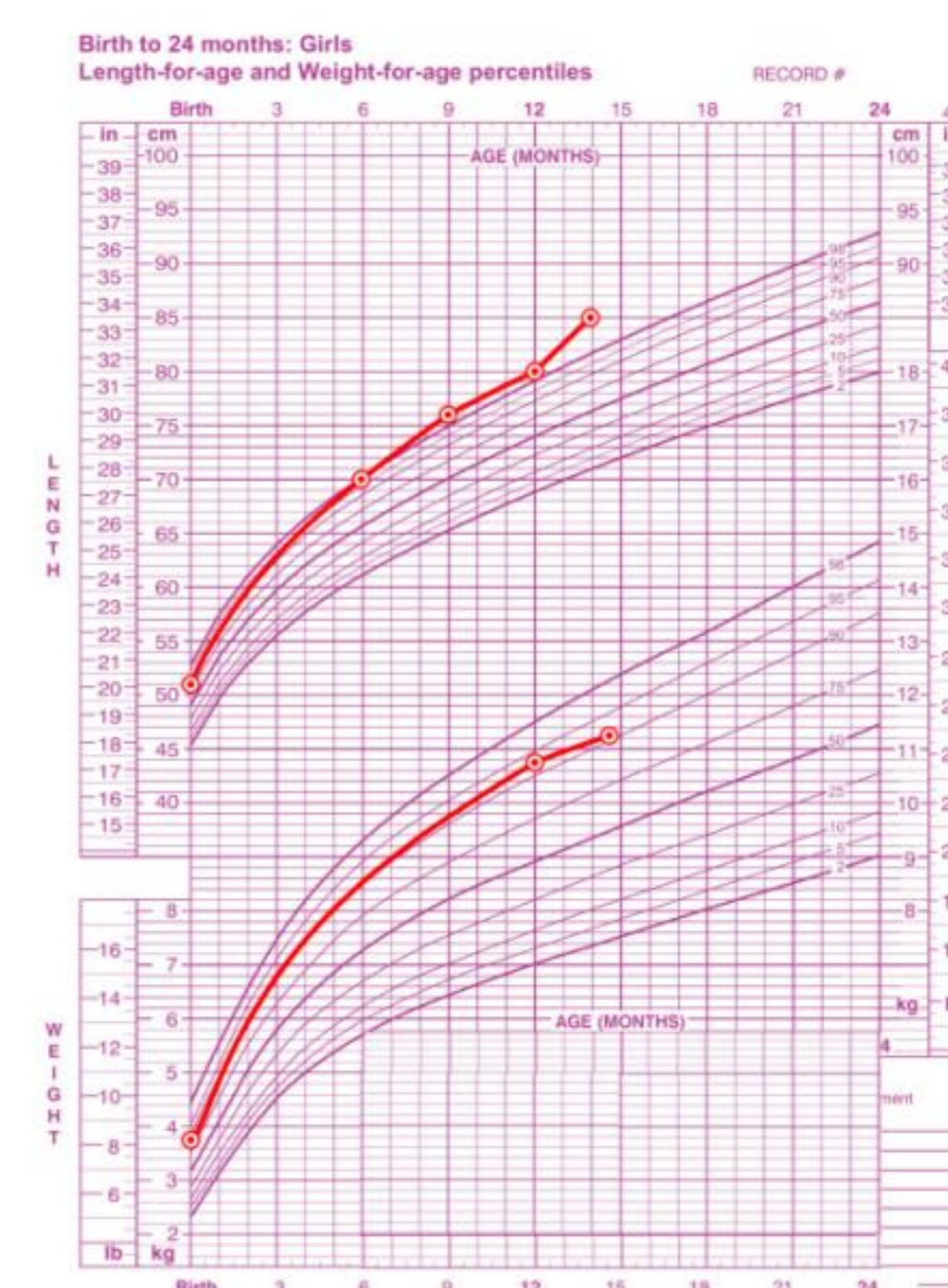
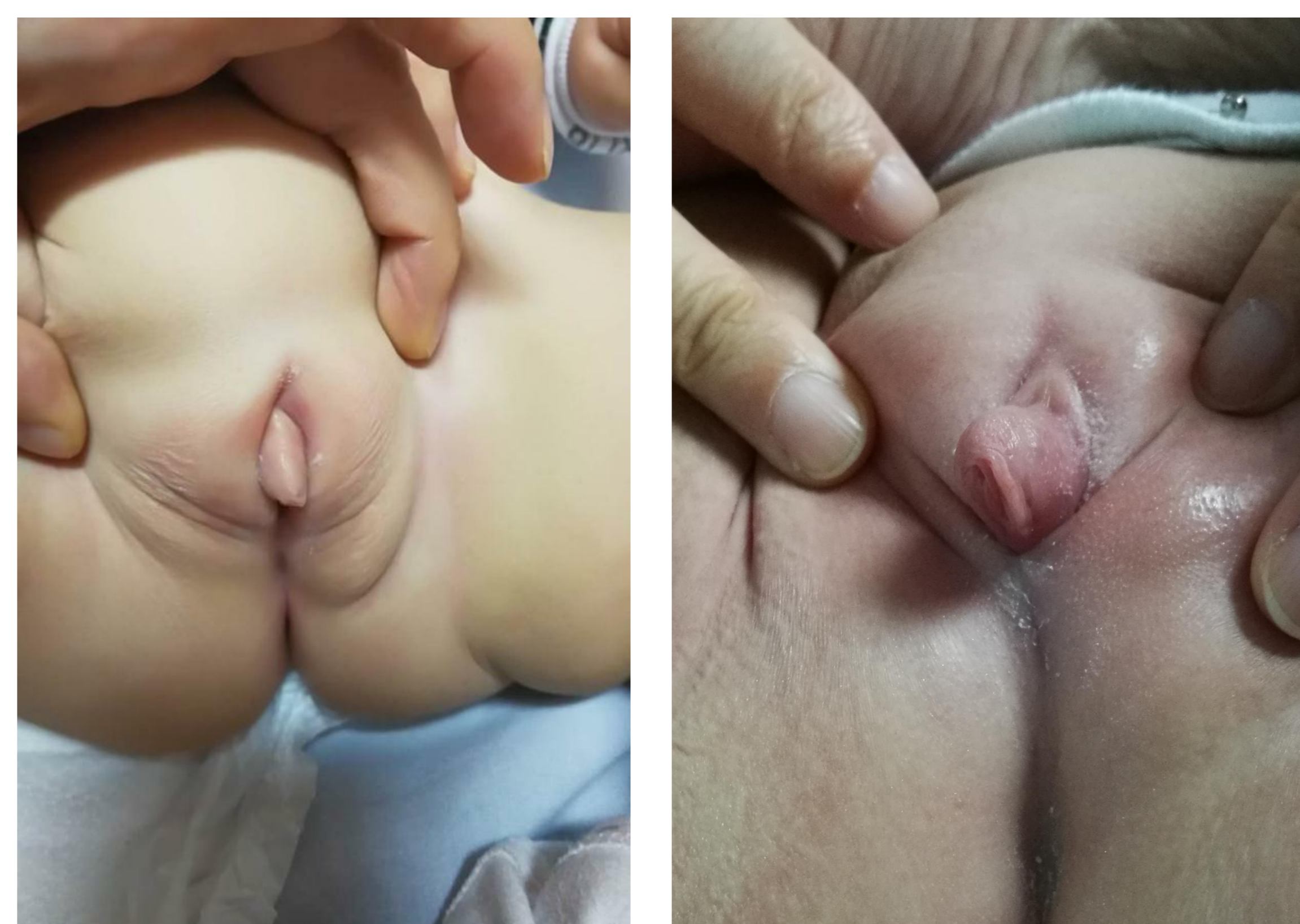

Figure 1 First visit, the patient was complaining about clitoridauw. The clitoris was about 2cm in length, absent labia majora and atretic.

Figure 2 Due to irregular medication, the hormone levels were poorly controlled. The clitoris continued to increase and the clitoris like a micropenis was about 3cm in length.

Figure 3 The patient's growth curve shows that her height and weight are growing normally (according to WHO standards).

Figure 4 The family tree shows that the patient has TS and CAH, her father carries a heterozygous mutation in CYP21A2, and her mother has a heterozygous large fragment deficiency.

CONCLUSIONS

This case shows a rare combination of TS and CAH, a female patient with TS, if whose main manifestation is virilization, the SRY gene should be verified. If the SRY gene is negative, the simple virilizing type of CAH needs to be considered. It reminds us that if a known genetic disease cannot explain all the clinical manifestations, it is necessary to consider the possibility that another genetic disease exists at the same time, although we generally use a diagnosed disease to explain all the symptoms of the patients in the clinical diagnosis. Multidisciplinary combination therapy is particularly important in the treatment process, including endocrinology, urology, gynecology and assisted reproductive center.

REFERENCES

- [1] Shammas C, Byrou S, Phelan M M, et al. Genetic screening of non-classic CAH females with hyperandrogenemia identifies a novel CYP11B1 gene mutation. [J]. Hormones, 2016, 15(2):235.
- [2] Wesseliuss R, Schotman M, Schotman M, et al. A Patient (46XX) With Congenital Adrenal Hyperplasia and Prostate Cancer: A Case Report: [J]. Journal of the Endocrine Society, 2017, 1(9):1213-1216.
- [3] Bondy C A. Care of girls and women with Turner syndrome: a guideline of the Turner Syndrome Study Group. [J]. Journal of Clinical Endocrinology & Metabolism, 2007, 92(1):10.
- [4] Shankar R K, Backeljauw P F. Current best practice in the management of Turner syndrome. [J]. Ther Adv Endocrinol Metab, 2018, 9(1):33-40.
- [5] Speiser P W, Azziz R, Baskin L S, et al. Congenital adrenal hyperplasia due to steroid 21-hydroxylase deficiency: an Endocrine Society clinical practice guideline. [J]. Journal of Clinical Endocrinology & Metabolism, 2010, 95(9):4133.

ACKNOWLEDGEMENTS

We greatly appreciate the patient's family for their participation in this study. We are grateful to SCMC Turner Baby's Club.

CONTACT INFORMATION

This work was supported by the Cross Research Fund for Medical Science Foundation of Medical Engineering of Shanghai Jiao Tong University (Project Leader: Yu Ding, grant no. YG2016QN39) Horizontal Project Fund of Shanghai Children's Medical Center (Project Leader: Yu Ding, grant no. PEGRF201506011)

