

## INTRODUCTION

Pituitary adenomas in children are rare and account for 3% of intracranial tumors in the pediatric population (1), dominated by prolactinomas and corticotropic adenomas, but plurisecreting adenomas are exceptional. We report a case of a 14-year-old girl with a pituitary macroadenoma with a prolactin-predominant plurisecreting immunohistochemical profile revealed by an intracranial hypertension syndrome with a good therapeutic response to cabergoline.

## OBSERVATION

A 14-year-old girl presented to the emergency department with asthenia and intracranial hypertension syndrome. Clinical examination revealed signs of central hypothyroidism and hypocorticism, an impuberism, with a growth delay (-2 SD for weight and height) and visual impairment. Laboratory investigations revealed thyroid, corticotropic and gonadotropic insufficiency contrasting with surprisingly normal prolactinemia confirmed by the absence of the hook effect, IGF1 was low. Hypothalamic-pituitary MRI identified a pituitary macroadenoma measuring 27x32x22mm compressing the optic chiasm (FIGURE1). Immunohistochemical analysis was positive for TSH, FSH, ACTH, and GH with obvious predominance of anti prolactin antibodies. Screening for multiple endocrine neoplasia type 1 was negative. The patient underwent specific oral drug therapy with cabergoline at 0.5mg weekly besides hormone replacement therapy. Clinical features and the visual acuity improved. Hypothalamic-pituitary MRI after 6 months of treatment with cabergoline, showed a reduction of at least 50 percent in measurable tumor size (FIGURE2).

## Bibliography:

Perry A, Salvatore C, Wetjen NM, Meyer FB, Marcellino C, Pollock BE. Pediatric Pituitary Adenoma : Case Series , Review of the Literature , and a Skull Base Treatment Paradigm. 2018;

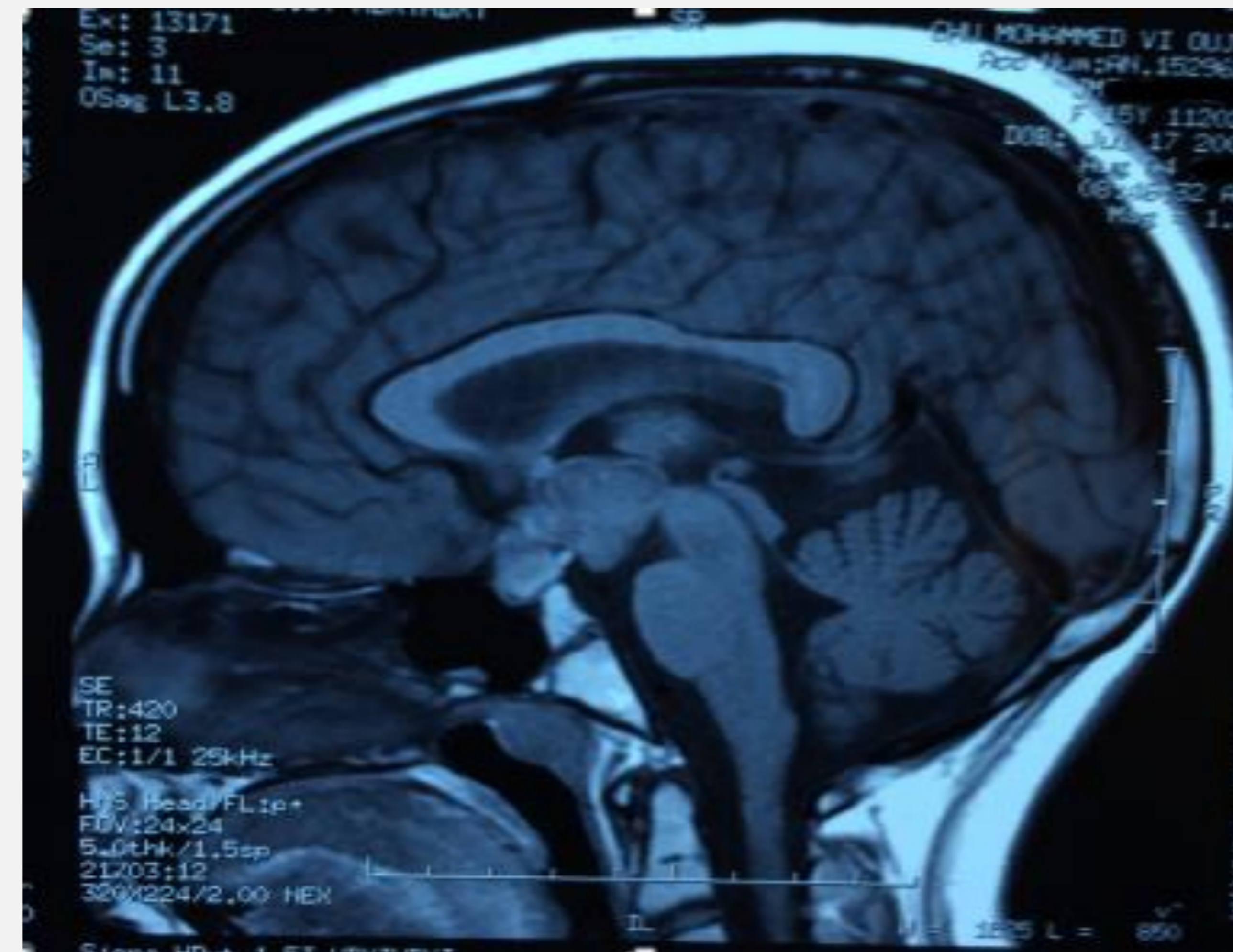


FIGURE 1: Before Treatment

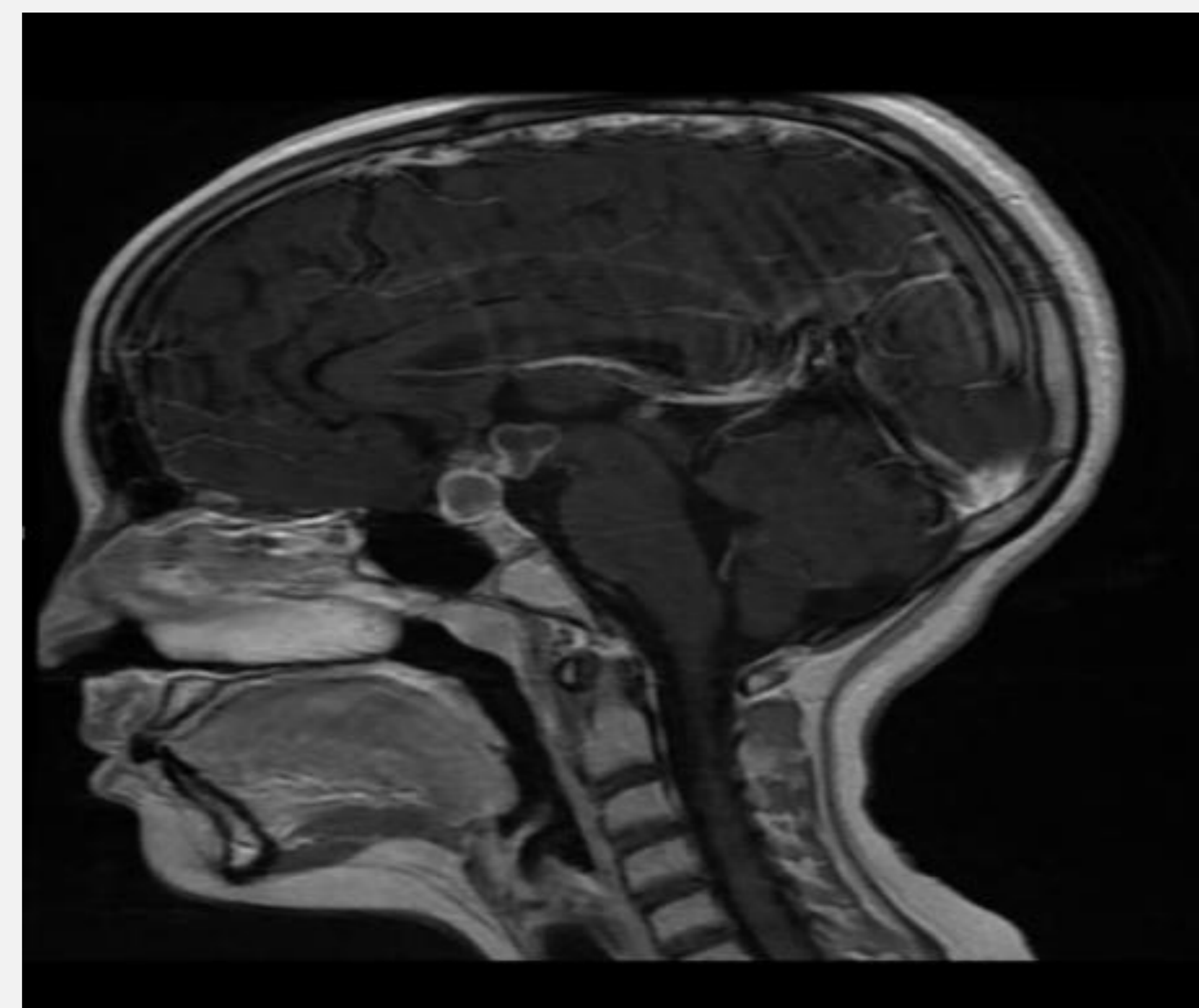


FIGURE 2 : Six months after treatment

## DISCUSSION

The prevalence of pituitary adenoma has increased in female children with a predominance of prolactinoma. The presentation of pediatric pituitary adenoma varies according to the secretory profile. Children rarely present with focal neurological signs unlike adults. However, visual impairment is a feature of non-functioning macroadenomas. Although surgery is the preferred first-line treatment for most pituitary tumors, prolactinomas are a good indication for dopaminergic agonists before proceeding to surgery. Cabergoline is generally more effective and better tolerated, with stable biological remission in 70% of macroadenomas. Patients who have a very low probability of tumor control with medical therapy may benefit from surgery.

## CONCLUSION

Pituitary adenomas in children are rarely described. They are often aggressive and affect growth and pubertal development. In 14% of cases a genetic mutation is found. Urgent and multidisciplinary management are required to minimize morbidity and mortality in this vulnerable group.