

45,X/46,XY MOSAICISM : PHENOTYPIC CHARACTERISTICS, GROWTH AND GONADAL FEATURES.

N.M. SELVEINDRAN¹, J.S.L. WONG¹, J.Y.H. HONG¹
¹Paediatric Endocrine Unit, Putrajaya Hospital, Malaysia

INTRODUCTION

Sex chromosome mosaicism (45,X/46,XY and variants) is a rare subgroup of disorders of sex development.¹ It has widespread clinical implications as it affects growth, hormonal balance, gonadal development, and histology.^{2,3} Clinical knowledge about the phenotype and outcome of this group of patients is limited.

AIM

The aim of this study is to evaluate phenotype, growth, reproductive hormones and gonadal histology in patients with 45,X/46,XY mosaicism.

METHOD

This was a retrospective, longitudinal study conducted from January 2006 to January 2021 at a tertiary paediatric endocrine referral center. Patients' clinical presentation, karyotypes, height, hormonal profiles, imaging and histologic findings of the gonads were evaluated. Phenotypes were scored using external masculinization scores (EMS) and external genitalia scores (EGS).

RESULTS

- A total of 12 patients with 45X/46XY and its variants were identified.
- Four patients had variants of the karyotype with aberrations of the Y chromosome.
- Final gender of rearing was male (8 patients) and female (4 patients). During the course of follow-up, two patients underwent gender change.
- Nine patients were diagnosed due to ambiguous genitalia, and three others between the ages of 8 to 12 due to short stature/delayed puberty.
- 25% of patients had features of Turner phenotype.
- Majority of the patients had normal reproductive hormones during minipuberty.
- One patient was started on growth hormone therapy.

Table 1 : Characteristics of patients with 45X/46XY

Age		Genital phenotype	
Age at first presentation (years)(median,IQR)	0.2[0.1 - 0.75]	EMS (median, range)	4.5 [1 - 10.5]
Age of Gender assignment (years)(median,IQR)	0.45 [0.075 - 1]	EGS (median, range)	5.25 [1 - 10.5]
Height		Mullerian remnants detected (yes)	66%
Female Height SD (median, range),cm	-2.62 (-3.26 to -2.0)		
Male Height SD (median, range),cm	-0.46 (0.13 to -1.7)		

CONCLUSIONS

The 45,X/46,XY phenotype varies widely. This study demonstrates an association between the 45,X/46,XY karyotype and growth as has been described previously.⁴ Assessment of gonadal differentiation patterns in 45,X/46,XY is challenging because it represents a continuum between two extremes (normal testis and normal ovary).⁵ Management of each patient should be individualized according to the clinical and histological assessment.

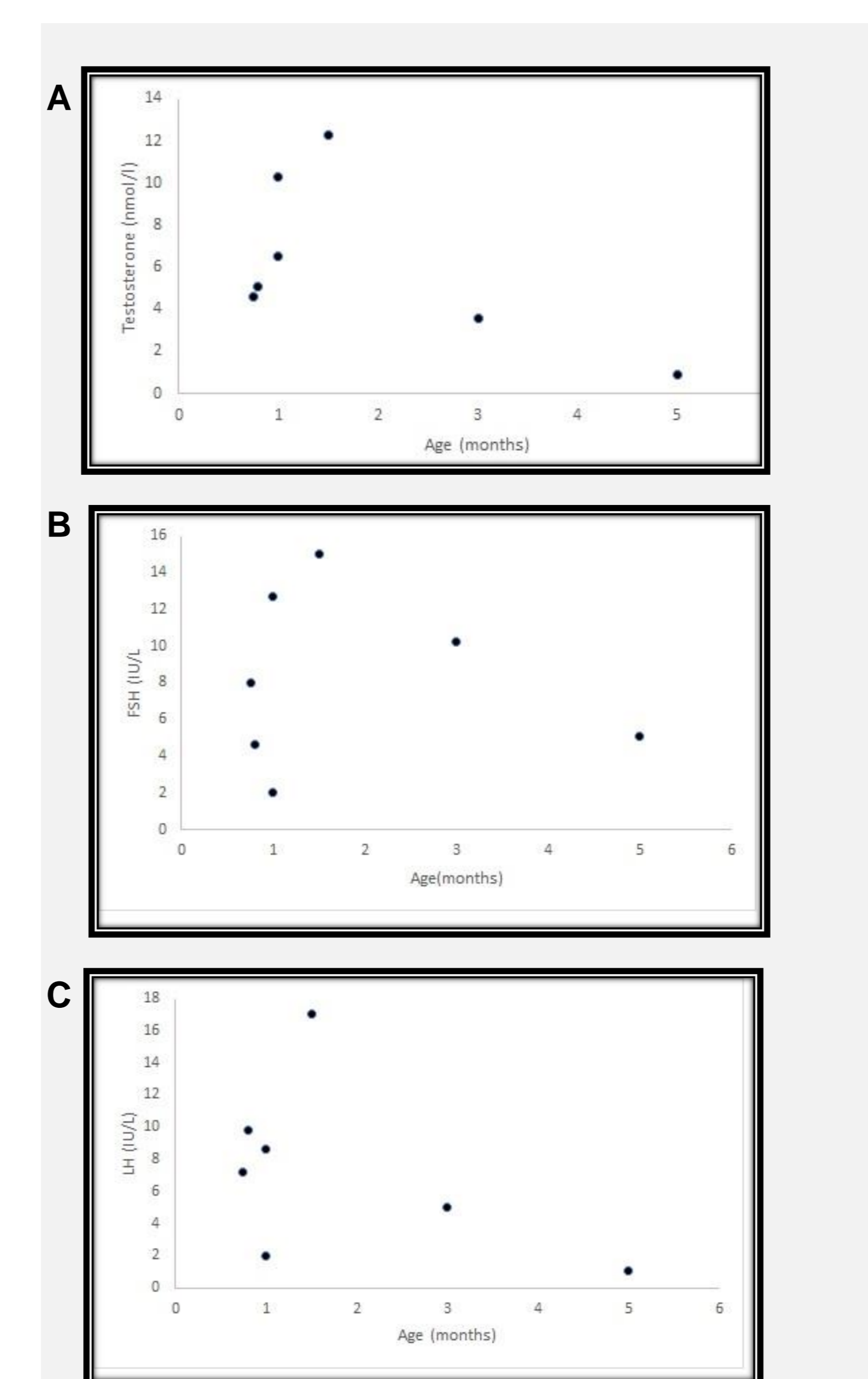


Figure 1 :Serum levels of testosterone, LH, FSH according to age in male patients with a 45,X/46,XY karyotype during the minipuberty period.
A. Testosterone(nmol/l) B. FSH (IU/L) C. LH (IU/L)

- Histology of 16 gonads was available from patients who had undergone a gonadectomy or gonadal biopsy.
- All tissue samples from patients revealed abnormal gonadal histology.
- Scrotal gonads were all recognized as testis.
- Gonads in the inguinal region were mostly testis (67%) however Undifferentiated Gonadal Tissue (UGT) were also identified (33%).
- Abdominal gonads mostly presented as streak tissue (50%) or ovarian tissue (20%), however testis (20%) and UGT (10%) was also identified.
- The absence of gonadal tissues was observed in 6.3% of samples.

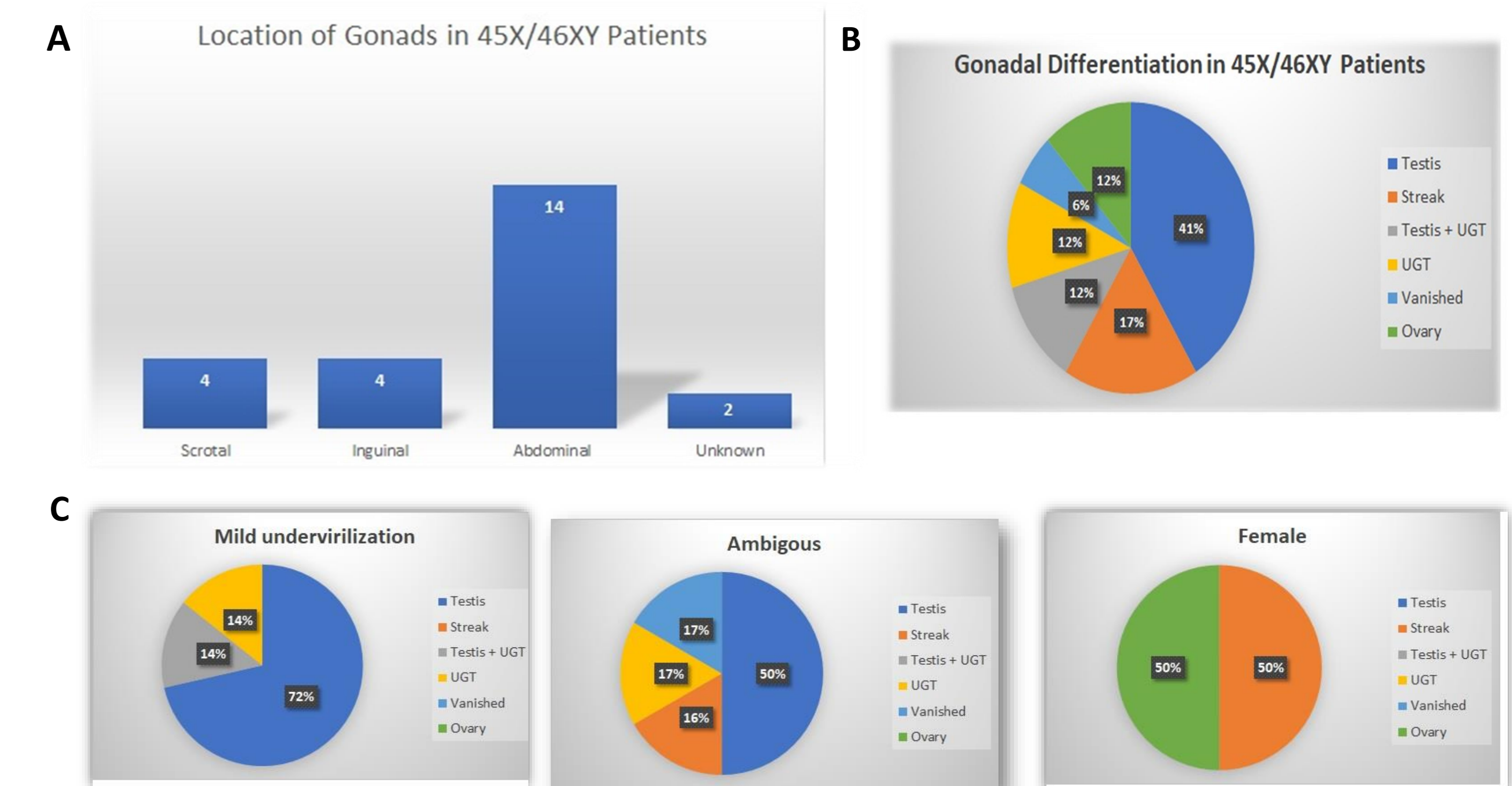


Figure 2 : A. Location of the gonads in 45,X/46,XY Patients. B. Distribution of gonadal differentiation in 45,X/46,XY Patients. C. Distribution of gonadal differentiation patterns in the different phenotypic groups. (Mild undervirilized (EMS≥7), Ambiguous (EMS<7), Female)

REFERENCES

- Marie Lindhardt Johansen, Casper P. Hagen, Ewa Rajpert-De Meyts, Susanne Kjærgaard, Bodil L. Petersen, Niels E. Skakkebaek, Katharina M. Main, and Anders Juul. 45,X/46,XY Mosaicism: Phenotypic Characteristics, Growth, and Reproductive Function—A Retrospective Longitudinal Study. J Clin Endocrinol Metab, August 2012, 97(8):E1540 –E1549.
- Lili Pan, Zhe Su*, Jianming Song, Wanhua Xu, Xia Liu, Longjiang Zhang, Shoulin Li and on behalf of the multidisciplinary collaboration team of DSD management at Shenzhen Children's Hospital. Growth data and tumour risk of 32 Chinese children and adolescents with 45,X/46,XY mosaicism. BMC Pediatrics (2019) 19:143
- Merih Berberoğlu1, Zeynep Şıklar1, Ankara University Faculty of Medicine Disorders of Sexual Development Ethics Committee. The Evaluation of Cases with Y-Chromosome Gonadal Dysgenesis: Clinical Experience over 18 Years. J Clin Res Pediatr Endocrinol 2018;10(1):30-37
- Martinerie L, Morel Y, Gay CL, Pienkowski C, de Kerdanet M, Cabrol S, Lecointre C, Coutant R, Baron S, Colle M, Brauner R, Thibaud E, Leger J, Nihoul-Fekete C, Bouvattier C 2012 Impaired puberty, fertility and final stature in 45,X/46,XY mixed gonadal dysgenetic patients raised as boys. Eur J Endocrinol 166:687–694
- M. Cools, J. Pleskacova, H. Stoop, P. Hoebeke, E. Van Laecke, S. L. S. Drop, J. Lebl, J. W. Oosterhuis, L. H. J. Looijenga,* and K. P. Wolfenbützel,* on behalf of the Mosaicism Collaborative Group. Gonadal Pathology and Tumor Risk in Relation to Clinical Characteristics in Patients with 45,X/46,XY Mosaicism. J Clin Endocrinol Metab, July 2011, 96(7):E1171–E1180

ACKNOWLEDGEMENTS

We thank all referring clinicians and patients who have contributed to this study.

CONTACT INFORMATION

Paediatric Endocrine Unit,
Putrajaya Hospital,
Jalan P9, Presint 7, 62250 Putrajaya, Wilayah
Persekutuan Putrajaya, Malaysia.
Email: naliselv@gmail.com