

## A case report of Non-syndromic 46, XX testicular DSD presenting as a genital ambiguity - Clinical, molecular and cytogenetic analysis

**Kishore K Behera, S K Sahoo<sup>1</sup>, S R Behera.**  
**All India Institute of Medical Sciences; Bhubaneswar, India.**  
**Dept of endocrinology & metabolism; Pediatric surgery<sup>1</sup>**

**Submission ID: 276**

**INTRODUCTION:** Non-syndromic 46, XX testicular disorders of sex disorder (46,XX testicular DSD) are rare; occurred 1:20000 in new-born [1].

- Approximately 15- 20 % of individuals with this disorder present at birth with ambiguous genitalia[2,3]. Majority of them reared as male gender. Males with 46, XX testicular DSD experience hypergonadotropic hypogonadism.
- SRY-positive 46, XX testicular DSD is generally result from de novo abnormal interchange between the Y chromosome and the X chromosome, resulting in the presence of SRY on the X chromosome and infertility due to lack of AZF factors

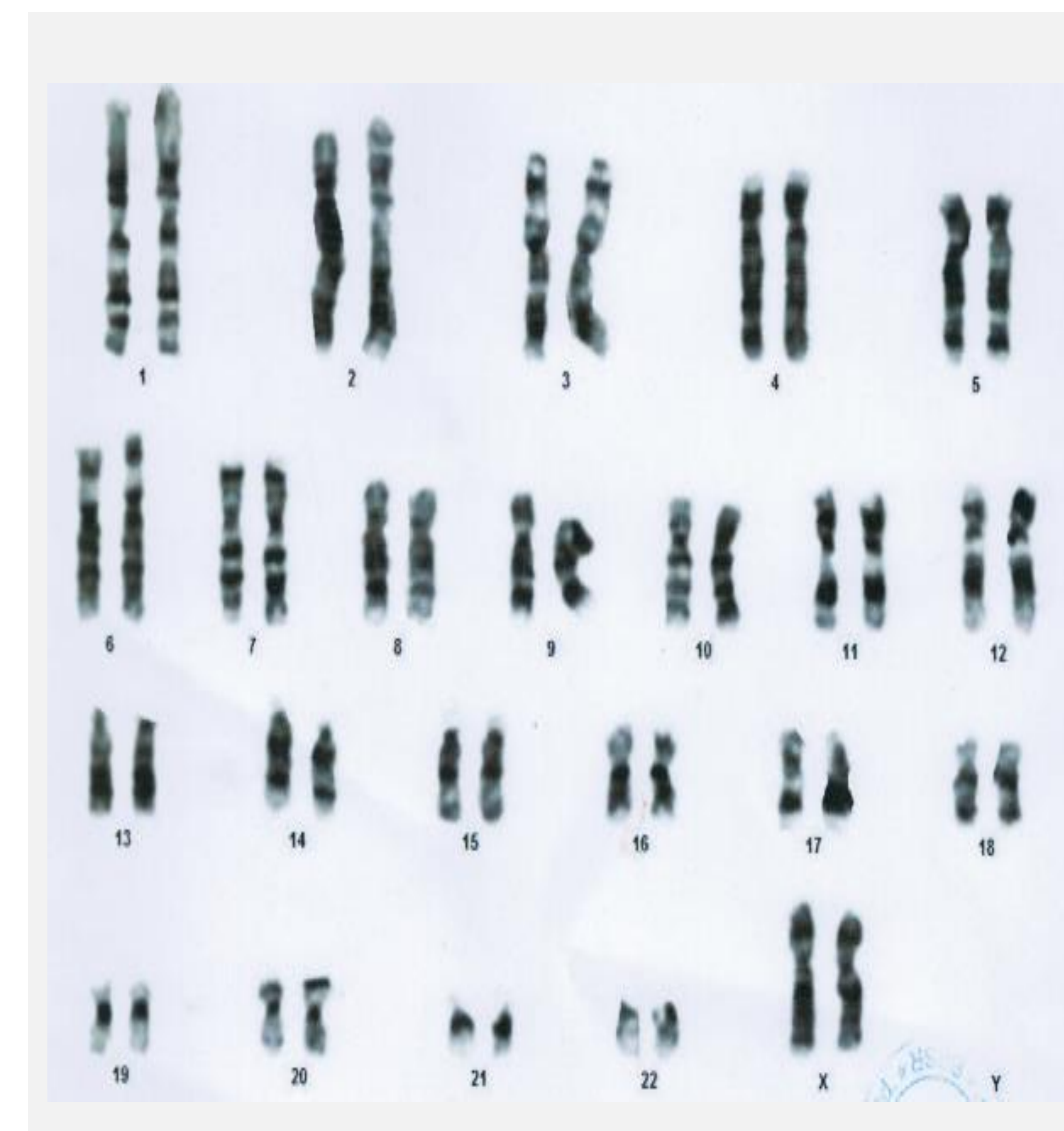
### AIM

- To study the clinical ,molecular and cytogenetic analysis of Non-syndromic 46, XX testicular DSD presenting as a genital ambiguity in a phenotypically male child .

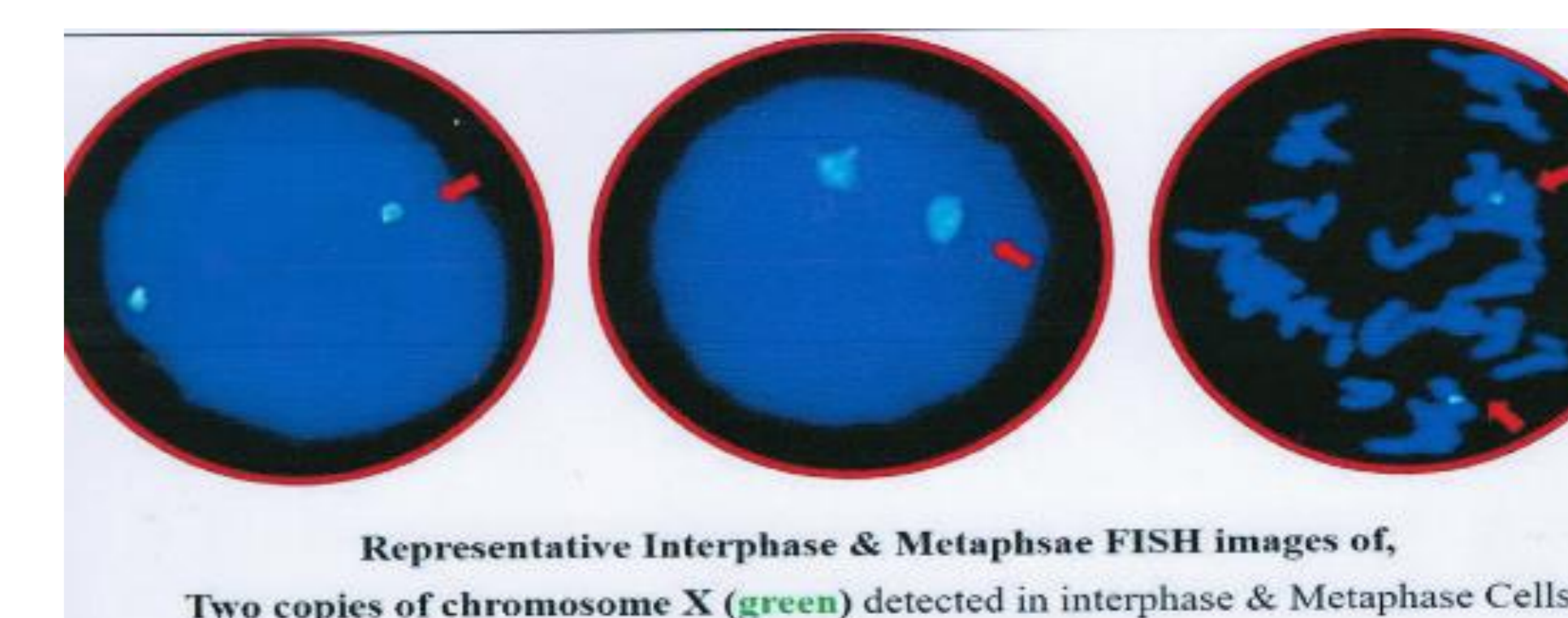
### RESULTS

- Examination of external genital showed bifid labio- scrotum sac, small phallus with ventral chordae with penoscrotal hypospadias.
- Biochemical test reveals normal electrolytes and renal function. His testosterone basal of 0.014 ng/dl, post HCG stimulation testosterone was 399ng/dl. Follicle stimulating hormone was 1.32mIU/L (reference range: 0.26–3.0 IU/L) luteinizing hormone was 0.001 mIU/L (reference range: < 0.3 IU/L), and thyroid hormones and serum cortisol were all within normal levels. 17 OH progesterone was 0.2ng/ml.
- Ultrasound examination showed that patient's bilateral gonads were found lateral to the phallic shaft ; right and left gonads measuring 1 × 0.5 cm and 0.5 × 0.47 cm respectively; no Mullerian structures were identified.
- The karyotype was 46, XX (fig-1). FISH analyses(fig-2) were conducted on both metaphase spreads and interphase nuclei which revealed a pair of X-chromosomes in all analyzed cells, ruling out mosaicism confirming conventional karyotyping results.
- By PCR (fig-3), the most common Yp loci, SRY, and ZFY were detected in the patient sample confirming the presence of malefactors.

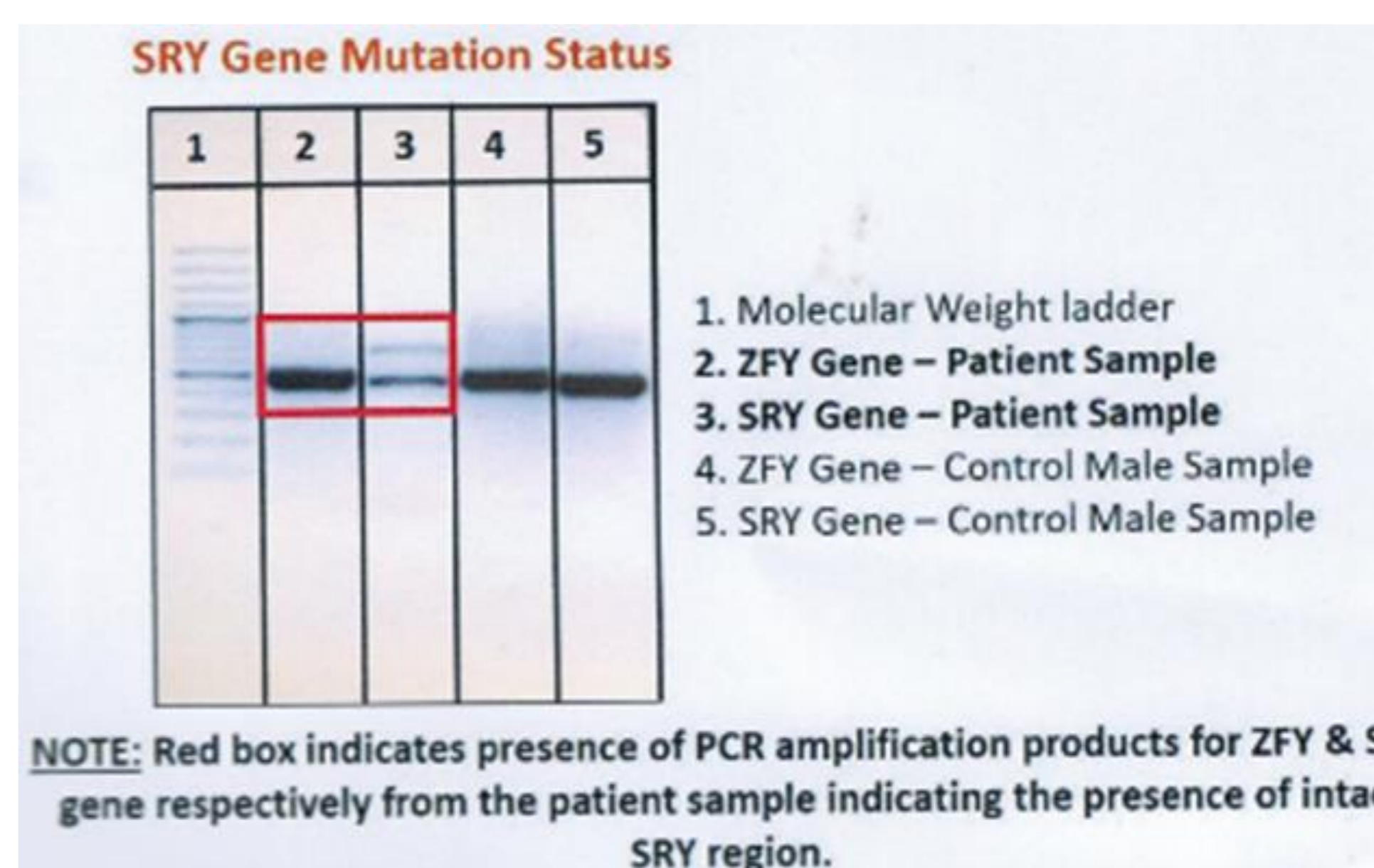
**Fig-1** Karyotype analysis report showing 46XX



**Fig-2** FISH analysis confirms two copies of chromosome X shown in green detected in interphase and metaphase cell



**Fig-3** PCR amplification showing products for ZFY and SRY gene marked in red box.



### METHOD

- A 3 years old child with genital ambiguity with hypospadias and bifid scrotum consulted to our endocrine OPD for further management.
- Clinical data was noted, and Karyotype analysis of G-banding in lymphocytes and Fluorescence in situ hybridization (FISH) were performed. FISH analyses were conducted on both metaphase spreads and interphase nuclei.
- The genomic DNA was isolated from EDTA whole blood. The isolated genomic DNA was checked for the presence of SRY and ZFY (Zinc finger chromosomal protein) genes to access the male factor via Polymerase Chain Reaction (PCR) followed by agarose gel electrophoresis.

### DISCUSSION & CONCLUSIONS

- 46XX male syndrome (testicular DSD) is due to defect in gonadal differentiation manifested by female karyotype in incongruous with male phenotype.
- Our case puts in a new case of 46, XX male subject with SRY-positive gene and further demonstrates that the presence of SRY gene and the absence of major regions in the Y chromosome should lead to masculinized phenotype with genital ambiguity.
- The genital anomalies need to be surgically corrected in staged manner. This case needs long term follow up to address various endocrinological issues that will be faced during puberty such as pubertal development, and concerned about fertility during adult hood.

### REFERENCES

1. Wu, QY., Li, N., Li, WW. et al. Clinical, molecular and cytogenetic analysis of 46, XX testicular disorder of sex development with SRY-positive. BMC Urol 14, 70 (2014). <https://doi.org/10.1186/1471-2490-14-70>
2. Délot EC, Vilain EJ. Nonsyndromic 46,XX Testicular Disorders of Sex Development. 2003 Oct 30 [updated 2015 May 7]. In: Adam MP, Ardinger HH, Pagon RA, Wallace SE, Bean LJH, Stephens K, Amemiya A, editors. GeneReviews® [Internet]. Seattle (WA): University of Washington, Seattle; 1993–2020. PMID: 20301589.
3. Li H, He J, Leong I. A rare case of 46, XX (SRY positive) testicular disorder of sex development with growth hormone deficiency: Case report. Medicine (Baltimore). 2021 Feb 12;100(6):e24641. doi: 10.1097/MD.00000000000024641.

### ACKNOWLEDGEMENTS

Nil

### CONTACT INFORMATION