

# PERSISTENT MÜLLERIAN DUCT SYNDROME (PMDS) PRESENTING WITH BILATERAL CRYPTORCHIDISM AND OBSTRUCTED INGUINAL HERNIA

Elpis- Athina Vlachopapadopoulou<sup>1</sup>, Anatoli Fotiadou<sup>2</sup>, Jean-Yves Picard<sup>3</sup>, Orthodoxos Achilleos<sup>4</sup>, Zoe Lamprinou<sup>4</sup>, Adelais Tzortzopoulou<sup>4</sup>, Alexandros Passalidis<sup>4</sup>, Stephanos Michalacos<sup>1</sup>

1. Department of Endocrinology, Growth and Development, "P. & A. Kyriakou" Children's Hospital, Athens, Greece.
2. 2nd Department of Paediatrics, University of Athens, "P. & A. Kyriakou" Children's Hospital, Athens, Greece.
3. Sorbonne University, CRSA - Inserm UMRS 938, Paris, France.
4. 2nd Department of Pediatric Surgery, "P. & A. Kyriakou" Children's Hospital, Athens, Greece

## INTRODUCTION

PMDS is a Disorder of Sex Development (DSD) caused by mutations in genes encoding anti-Müllerian hormone (AMH) or its type II receptor (AMHR2) with autosomal recessive transmission. In humans, the gene for AMH is located on chromosome 19p13.3, while the gene AMHR2 codes for its receptor on long arm of chromosome 12. AMH is activated by SOX9 in the Sertoli cells of the male fetus.

## AIM

To report a case of transverse testicular ectopia (TTE), associated with PMDS, initially presented as an obstructed inguinal hernia.

## METHODS

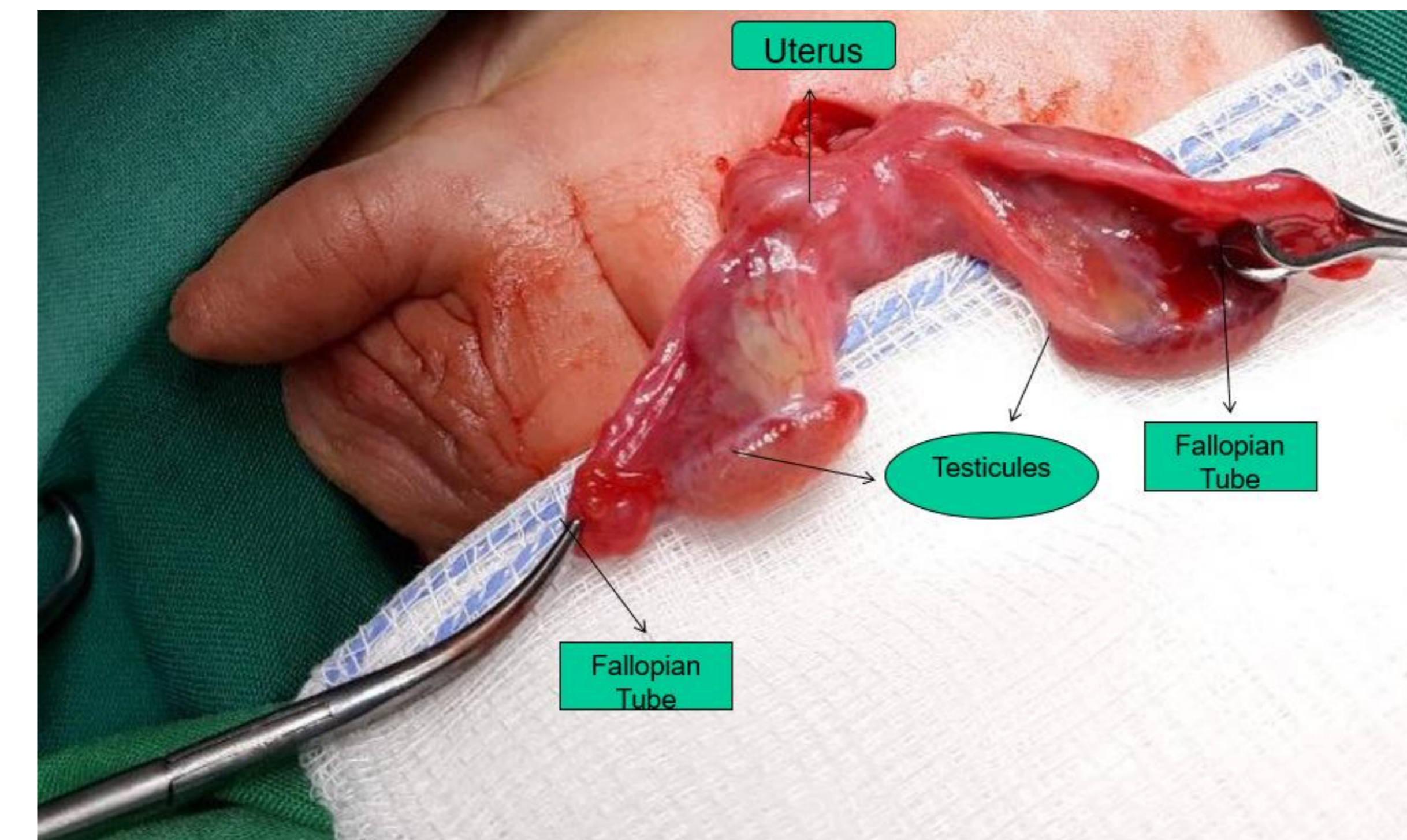
An 18-days-old male infant, with a known history of bilateral cryptorchidism, presented with a left-sided obstructed inguinal hernia. He was born at 38 weeks gestation with a birth weight of 3300 grs with no perinatal complications. On clinical examination he had normal penile length. Genetic study used NGS sequencing targeted on both genes AMH and AMHR2.

## RESULTS

Pelvic ultrasonography indicated two testes inside the left scrotum along with uterine tissue extended through the inguinal canal. The inguinal exploration revealed a hernial sac containing both testes and a uterus with fallopian tubes. During hernia repair surgery, all of the tissues were pushed back into the peritoneal cavity and biopsy samples were taken.

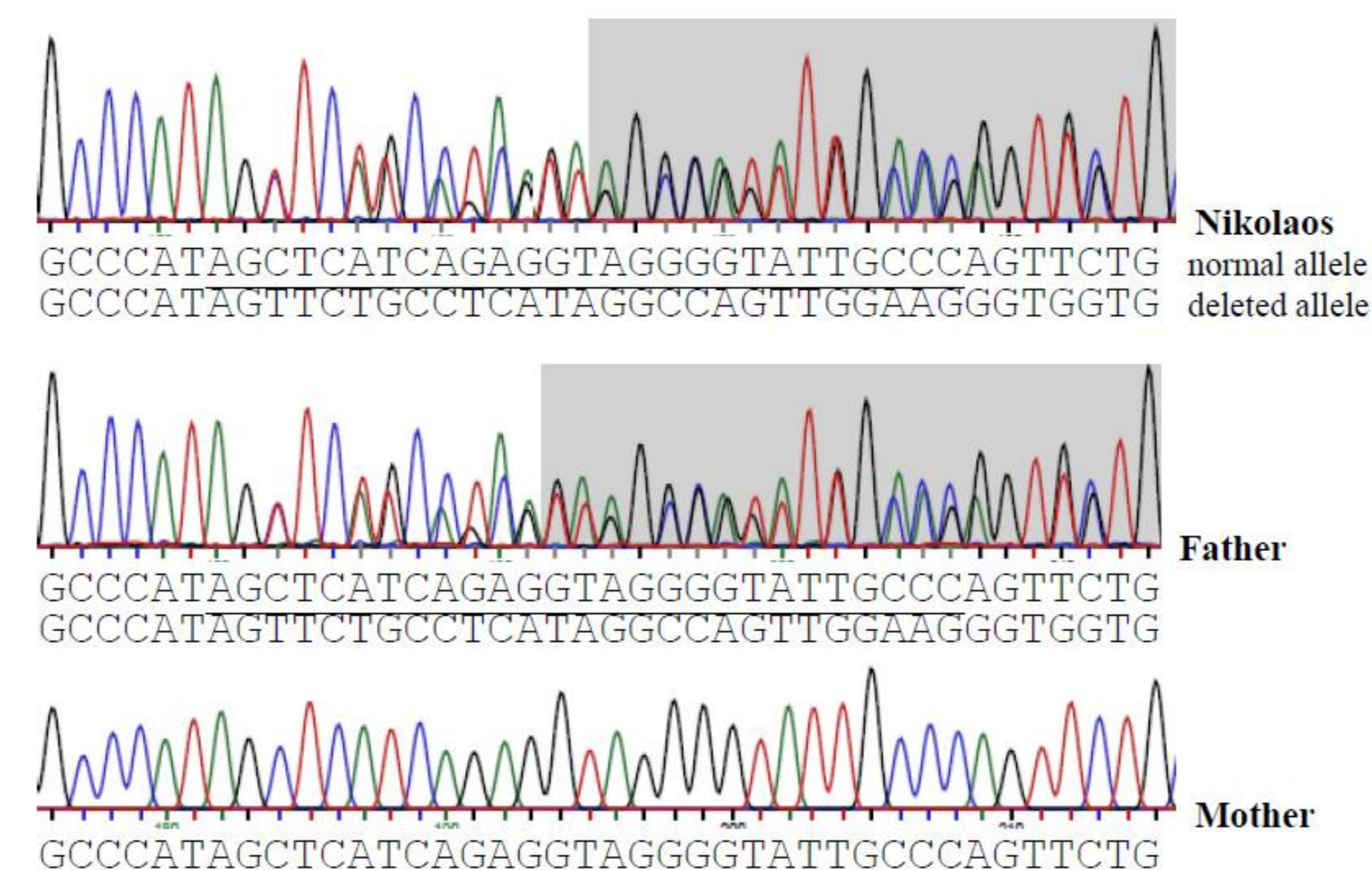
Endocrine evaluation revealed normal levels of gonadotrophins, testosterone, cortisol and 17-OH-progesterone and low levels of estradiol, **subnormal level of AMH**. Karyotyping confirmed a male gender (46 XY). The histopathological diagnosis confirmed the presence of Müllerian-derived tissues.

**Genetic studies revealed that our patient was heterozygous for two recessive mutations.** The first one was a **frequent deletion** of 27 pairs of bases in the 10th of 11 exons of the gene, while the second one was a **novel 2 base pair deletion** mutation in the 6th exon. One year later and after confirmation of the diagnosis, removal of the Mullerian remnants and orchidopexy were performed.

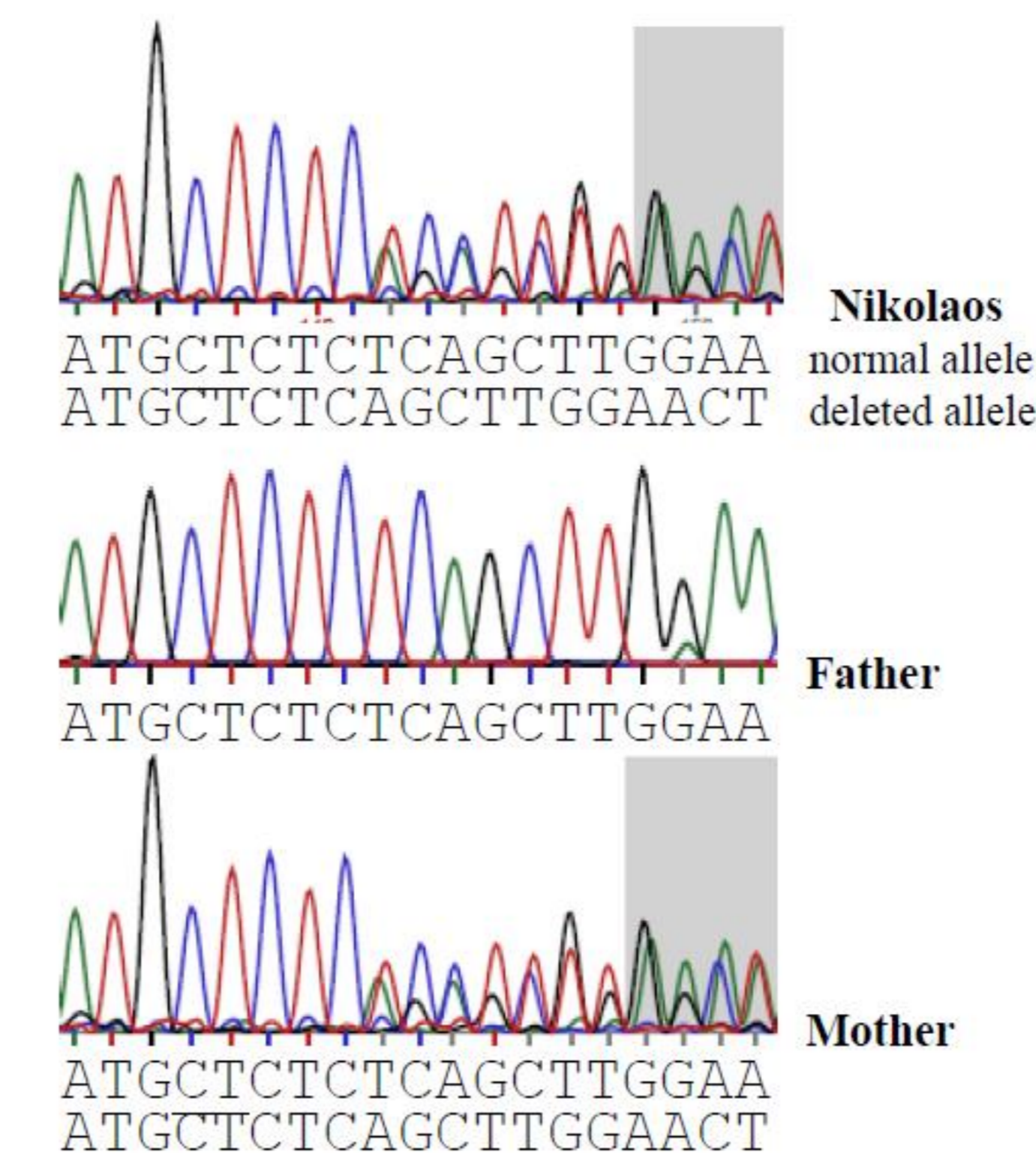


	Results	Normal Range (30-days-old male.)
FSH	1,96	<3,2 mIU/ml
LH	10,25	<6 mIU/ml
Testosterone	1,26	0,2-3 ng/ml
Estradiol	5,3	<10 pg/ml
17 OHP	2,5	0,3-2,5 ng/ml
Cortisol	7,5	1,8- 14,5 µg/dl
AMH	<b>160</b>	228-4280 pmol/l

**27 bp deletion (bases underlined on the normal allele are absent on the mutated allele)**



**2bp deletion**



## CONCLUSIONS

PMDS is a rare congenital condition, usually presented as cryptorchidism with associated inguinal hernia. It is classified as a 46 XY DSD.

The surgical approach of bilateral orchidopexy and hernia repair with or without removing Mullerian structures is the optimal treatment. The main therapeutic targets are the potential for fertility and prevention of malignant transformation. Gonadal biopsy and genetic testing should be carried out in order to rule out other disorders.

The diagnosis and treatment of neonates with DSD should be undertaken by a multidisciplinary team that consists of pediatric endocrinologists, urologists, surgeons, neonatologists, geneticists and psychologists.

## REFERENCES

1. Cools M, Nordenström A et al. Caring for individuals with a difference of sex development (DSD): a Consensus Statement. Nat Rev Endocrinol. 2018 Jul;14(7):415-429.
2. León NY, Reyes AP et al. A clinical algorithm to diagnose differences of sex development. Lancet Diabetes Endocrinol. 2019 Jul;7(7):560-574.
3. Picard JY, Cate RL et al. The Persistent Müllerian Duct Syndrome: An Update Based Upon a Personal Experience of 157 Cases. Sex Dev. 2017;11(3):109-125.

## ACKNOWLEDGEMENTS

Special thanks to Dr. JY Picard and his laboratory who helped us with each step of genetic testing by facilitating it and being always ready to give their comment and advices.

## CONTACT INFORMATION

Elpis Vlachopapadopoulou, email: [elpis.vl@gmail.com](mailto:elpis.vl@gmail.com)  
Jean-Yves Picard, email: [jean-yves.picard@u-psud.fr](mailto:jean-yves.picard@u-psud.fr)

