


# 5 ALPHA-REDUCTASE TYPE 2 DEFICIENCY: A CASE REPORT

**M.Karrou (Dr), A.Tahri (Dr), I. Assarrar (Dr), N. Messaoudi (Dr), I.Rami (Dr), S. Rouf (Pr), H. Latrech (Pr)**  
*Department of Endocrinology-Diabetology and Nutrition, Mohammed VI University Hospital Center, Faculty of Medicine and Pharmacy, University of Mohammed 1st, Oujda, Morocco*



## INTRODUCTION

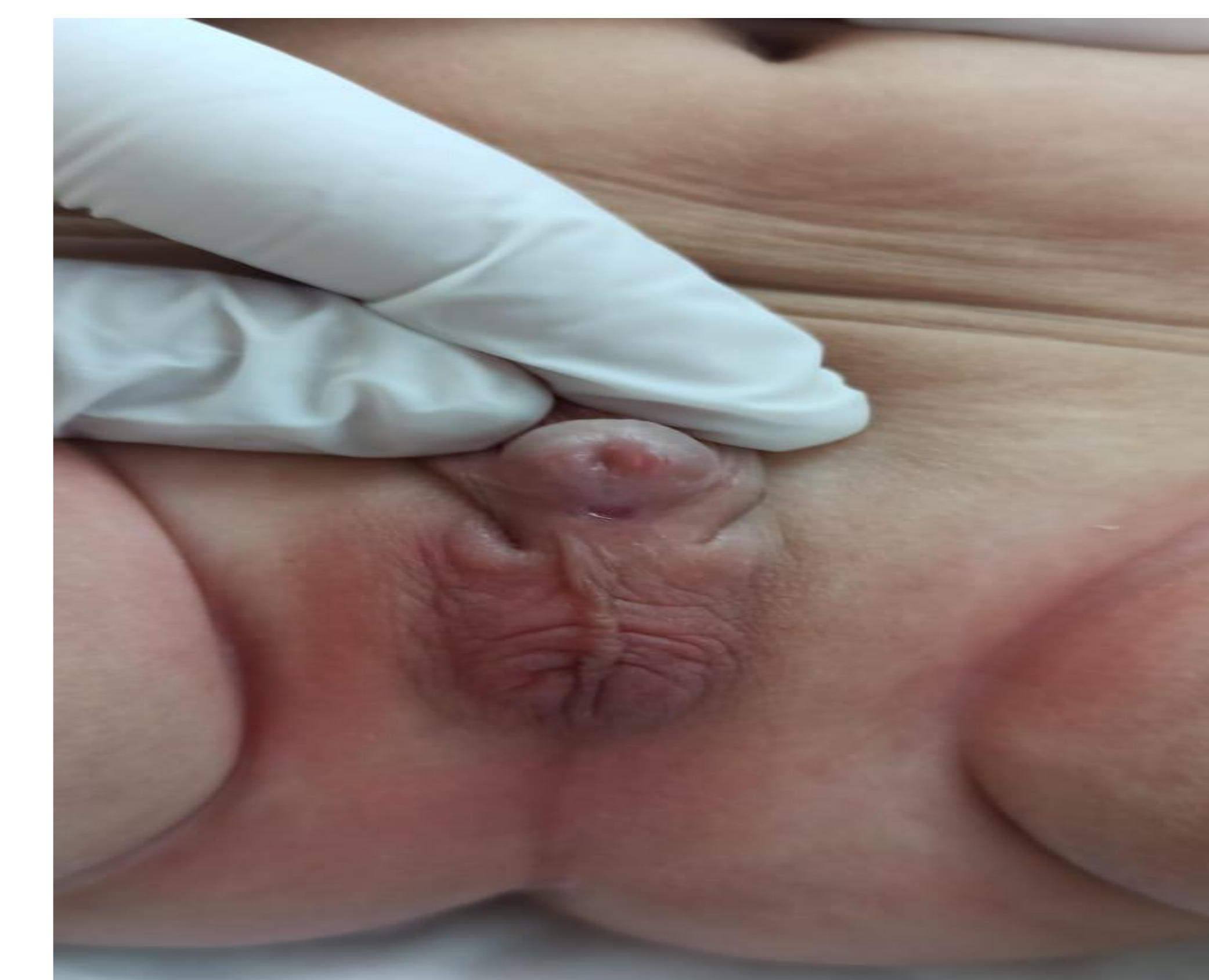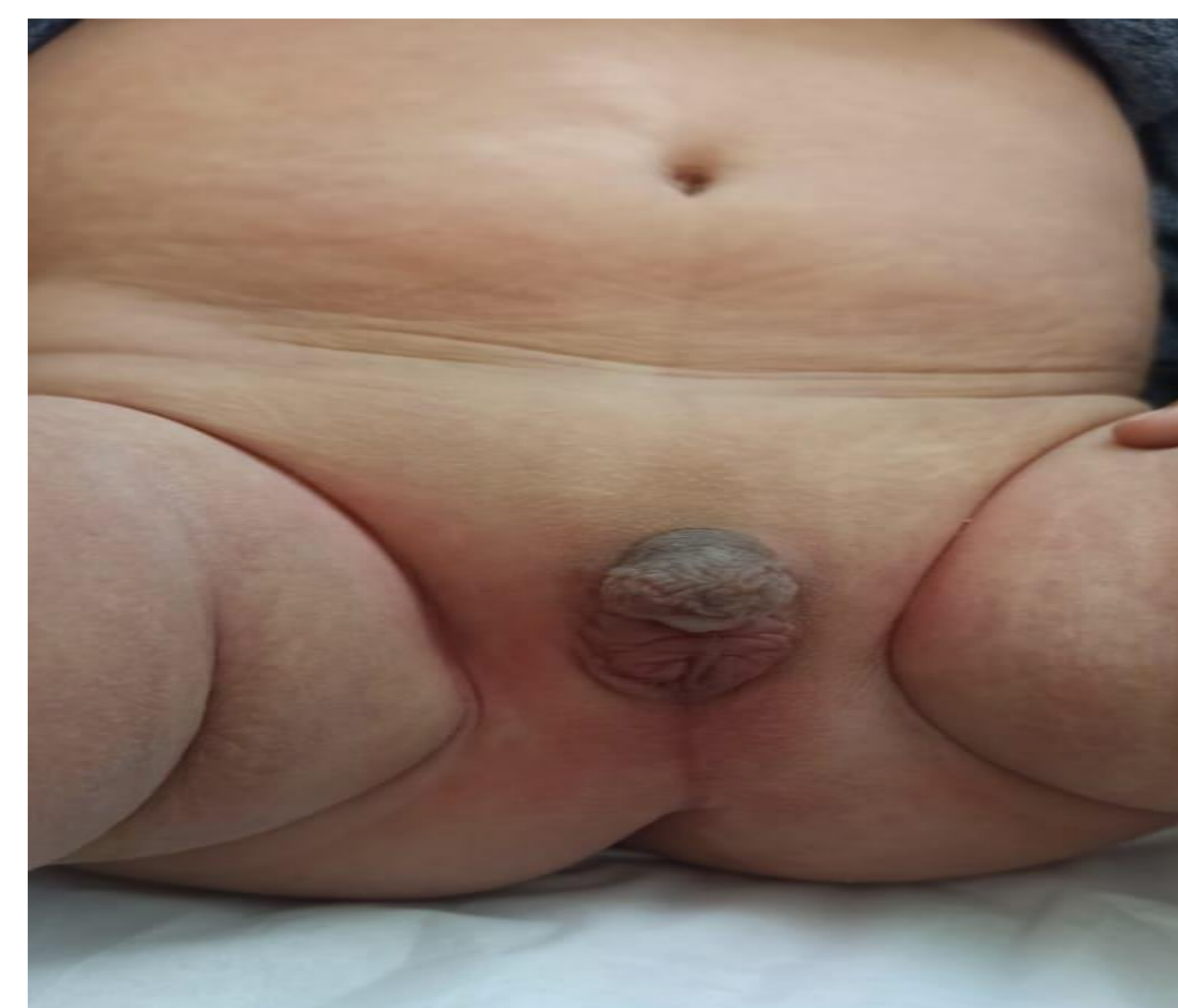In medical practice, sex assignment at birth depends primarily on the appearance of the external genitalia, which development begins as early as the fetal period and is largely dependent on dihydrotestosterone (DHT). Any discordance between the chromosomal, gonadal or anatomical sexes can lead to a disorder of sex development (DSD). 5 alpha-reductase 2 (5aRD2) deficiency is a very uncommon autosomal recessive genetic disorder that falls into the DSD 46 XY group, affecting the conversion of testosterone (T) to DHT.

## METHOD

We report the case of a patient admitted for DSD whose investigations revealed a 5aRD2 deficiency, followed-up in the Endocrinology-Diabetology-Nutrition of Mohammed-VI University Hospital Center of Oujda, in the eastern of Morocco.

## OBSERVATION

An infant aged 10 months, from a first degree consanguineous marriage, with a history of DSD in a cousin, was admitted in our department for DSD. The clinical examination revealed: genital tubercle measuring 02 cm with two orifices (the first is in normal position and the second is posterior and functional), and empty symmetrical and fused labioscrotal folds. Karyotype was 46XY. Endocrine evaluation showed a gonadotropic axis in quiescent phase (FSH: 0.79 mU/ml (1.5 - 14 mU/ml), LH: 0.64 mUI/ml (1.2 - 10 mUI/ml), T: 0.12 ng/ml (0.02 - 0.30)). The exocrine and endocrine testicular functions were evaluated respectively by AMH: 87.9ng/ml (1.4-11.2) and hCG test which came back positive (T: 10.68 ng/ml). The diagnosis of 5aRD2 was based on a T/DHT ratio (after hCG test) = 12.27 (>8.5). Pelvic MRI showed the presence of testicles in the inguinal position. The patient benefited from a micropenis hormonal therapy using androstrenolone gel, followed by correction of hypospadias and orchiopexy in two stages.



Endocrinology department images of a patient with 5aRD2.

## CONCLUSIONS

5aR2 deficiency is one of the causes of 46XY DSD. The phenotype of affected children can vary from an undervirilized male genitalia to a complete female phenotype. Following a review of the literature, the clinical presentation of this condition may be revealed by: clitoromegaly or micropenis, hypospadias and cryptorchidism. The confirmation of diagnosis is based on a high ratio of T/DHT after hCG test (8.5 is considered the most reliable cut-off value), therefore, molecular analysis is the most effective diagnostic method. Treatment using DHT gel has satisfactory results on the correction of micropenis. Through this case we understand the importance of 5aR2 in sexual differentiation, whose deficiency can lead sometimes to dramatic complications.

## REFERENCES

K. N. Walter *et al.*, "Difficulties in Diagnosis and Treatment of 5 $\alpha$ -Reductase Type 2 Deficiency in a Newborn with 46,XY DSD," *Horm. Res. Paediatr.*, vol. 74, no. 1, pp. 67–71, Jul. 2010, doi: 10.1159/000313372.

## ACKNOWLEDGEMENTS

all the participants in the achievement of this study.

