

ATYPICAL PRESENTATION OF ACUTE SUPPURATIVE THYROIDITIS IN A 6 YEAR OLD CHILD

M. LIAPI¹, M. MÖLLER², J. FELDKAMP³, N. JORCH²

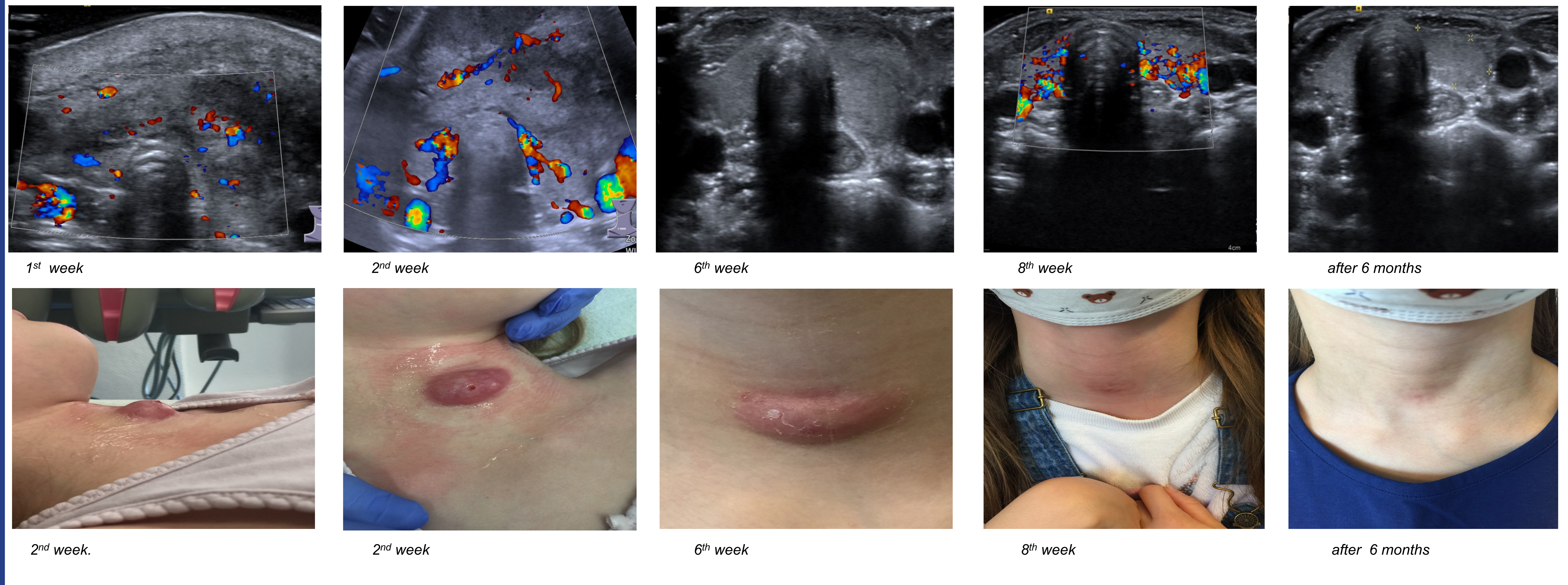
1. Kinderärzte Radewig, Herford, Germany
2. Evangelisches Klinikum Bethel, Universitätsklinikum OWL, Bielefeld, Germany
3. Klinikum Bielefeld, Universitätsklinikum OWL, Bielefeld, Germany

INTRODUCTION

- Bacterial infection of the thyroid (acute suppurative thyroiditis, AST) is a very rare condition, particularly in children, as the thyroid gland is extremely resistant to infection.
- Typical presentation with painful anterior neck mass, fever, sore throat, dysphagia, leucocytosis, elevated inflammation parameters.

CASE REPORT

- 6 year old girl with acute painless neck enlargement, without further symptoms.
- On palpation hard neck mass, without erythema, CRP and ESR only slightly elevated.
- Normal Thyroid hormone levels.
- Calcitonin elevated.
- Progressive neck swelling within a week with erythema and tenderness, without fever or pain, ESR elevation to maximum 49 mm/hr.
- Fine needle aspiration biopsy:
 - Cytology negative for malignancy.
 - Positive culture for Prevotella oris
- Treatment with clindamycin for 4 weeks
- ESR and calcitonin returned to normal within 6 weeks.
- No recurrence on 6 months follow up.



TAKE HOME MESSAGE

- Acute suppurative thyroiditis may sometimes present with atypical findings without pain, without systemic reactions and with only mild laboratory changes.
- Patients with AST remain mostly euthyroid.
- Serum calcitonin levels can be elevated in infectious thyroiditis and are not associated with malignancy.
- Ultrasound findings show heterogenous echogenicity of the thyroid gland (in our patient hyperechogenic changes) with irregular margin and inflammation.
- AST can be successfully treated with appropriate antibiotics.
- In recurrent infections anatomical defects such as pyriform fistula should be considered, in our patient because of full retrieval we decided for a “wait and see” strategy.

Blood test at diagnosis	Value	Normal range
Leukocytes	8,2/nl	5-12/nl
CRP	7,8 mg/l	0-2 mg/l
Calcitonin	14,2 µg/l	<9,8 µg/l
TSH	4,19 mIU/l	0,60-4,84 mIU/l
ESR	23 mm/h	<20 mm/h

REFERENCES

1. Pediatric endocrinology, M.A. Sperling, 5th edition
2. Acute suppurative thyroiditis: a ten year review in a Taiwanese hospital. Jeng LB et al, Scand J Infect Dis 1994;26:297.
3. Refractory acute suppurative thyroiditis secondary to pyriform sinus fistula. Jee Hyue Seo et al, Ann;19:104-107 Pediatr Endocrinol Metab 2014
4. Acute bacterial suppurative thyroiditis: a clinical review and expert opinion. Paes JE, Burman KD, CohenH, et al,Thyroid 2010, 20(3):247-55.

CONTACT INFORMATION

liapi@kinderaezte-radewig.de