

# Allan-Herndon-Dudley syndrome: Case report of a rare disorder

L. NAVASARDYAN<sup>1</sup>, I. MURADYAN<sup>2</sup>

1. Yerevan State Medical University, Endocrinology Department, Yerevan, Armenia
2. "Arabkir" Medical Center, Yerevan, Armenia



## INTRODUCTION

**Allan-Herndon-Dudley syndrome (AHDS)** is an X linked disorder – mutation of **monocarboxylate transporter 8 (MCT8)** gene. It leads to a severe psychomotor retardation, significant hypotonia of the skeletal muscles, spastic or dystonic quadriplegia. MCT-8 is responsible for the uptake of T3 by neurons of CNS. AHDS is characterized by increased T3 concentration, increased T3 / T4 ratio, TSH not depressed, even slightly elevated levels. Because of impossibility for the T3 entrance into the neuronal cells, clinical features of hypothyroidism become evident early at a critical stage of neuro-cognitive development in newborn period.

There are currently described **132 families** with AHDS in the world. In peripheral tissues, T3 can be transported into the cell by alternative transporters, resulting in peripheral hyperthyroidism, manifested by tachycardia, hypertension, loss of muscle mass and weight, malnutrition.

Currently **no treatment** is available to correct the peripheral thyrotoxicosis. The effectiveness of levothyroxine and/or antithyroid therapy is **not proven**. There is no any guideline for the management of these patients. Recently a paper was published by Groeneweg S. et al (2019) showing the effectiveness and safety of T3 analogue **Triac** in the phase 2 trial. Triac enters into the neuronal cells independently from MCT8 via an alternative channels, which serves as an exciting and uncommon opportunity potentially to improve the neurocognitive development.

## METHODS

Neurological and physical examination, 24-Hour Holter - monitoring, thyroid status and genetic testing were done.

## CASE REPORT

A child was followed by neurologists from the newborn period due to neuro-developmental delay. Newborn screening of TSH was normal, later TSH and fT4 evaluation found subclinical hypothyroidism. Due to stable subclinical hypothyroidism treatment with levothyroxin was administered, which was ineffective and the treatment was stopped. Objective examination showed muscular weakness, scoliosis, global development delay, dystonic opened mouth, no contractures. (Figure 1, Figure 2). The whole-exome-sequencing was performed by neurologists, which revealed a novel homozygous mutation (c.972G>A) in the *SLC16A2/MCT8* gene. Last examination: bilateral esotropia, severe tetraparesis with contractures, neuro-developmental delay, no speech, weight - < 3%, height - 25%, head circumference - <3%. Thyroid status and results of Holter-monitoring are shown in Table 1 and Table 2 respectively. Symptoms of peripheral hyperthyroidism: tachycardia 115-197b/min by Holter-monitoring.

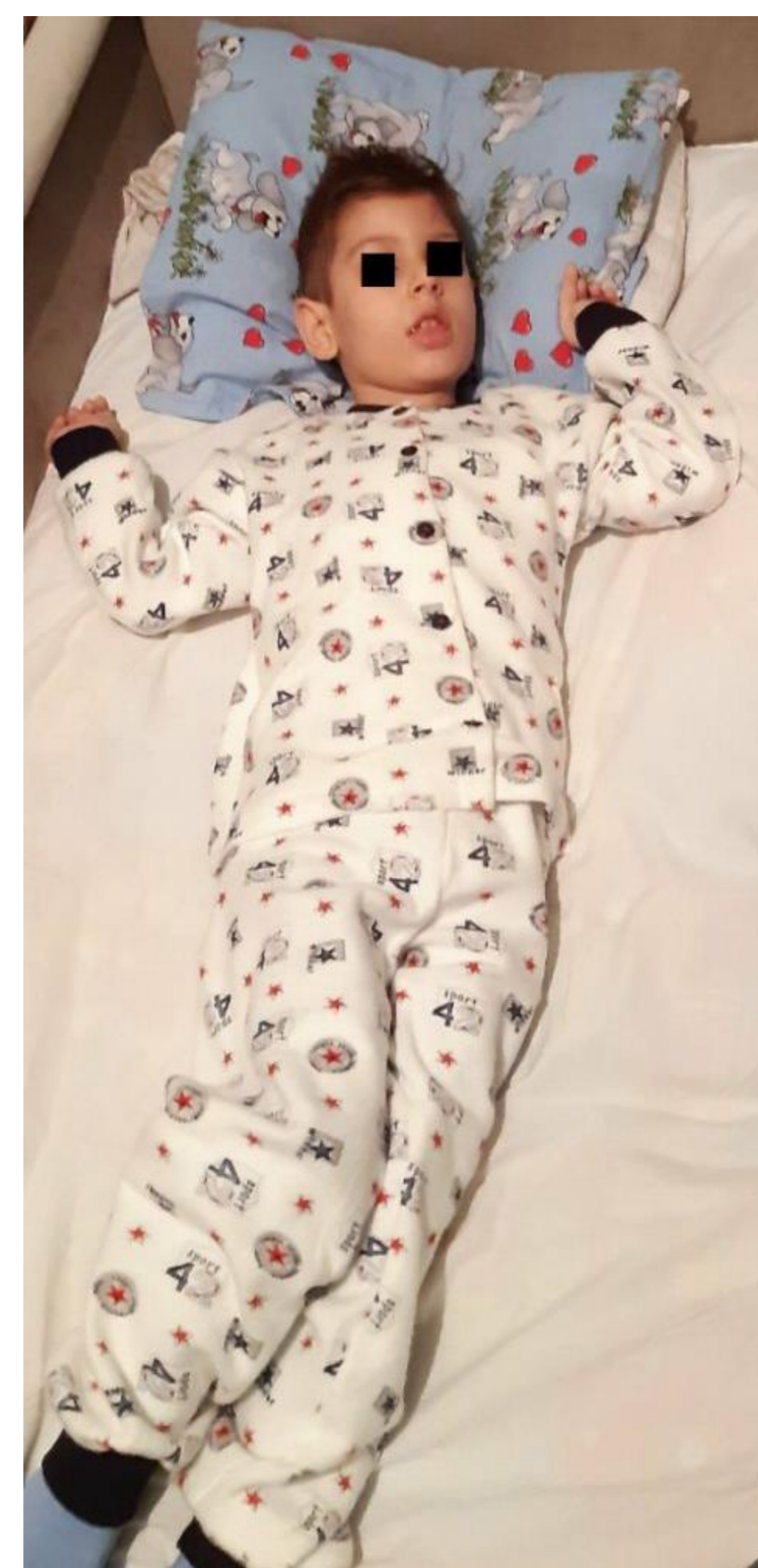

Figure 1: The patient at age of 5 years. Muscular weakness, dystonic opened mouth, no contractures can be seen.

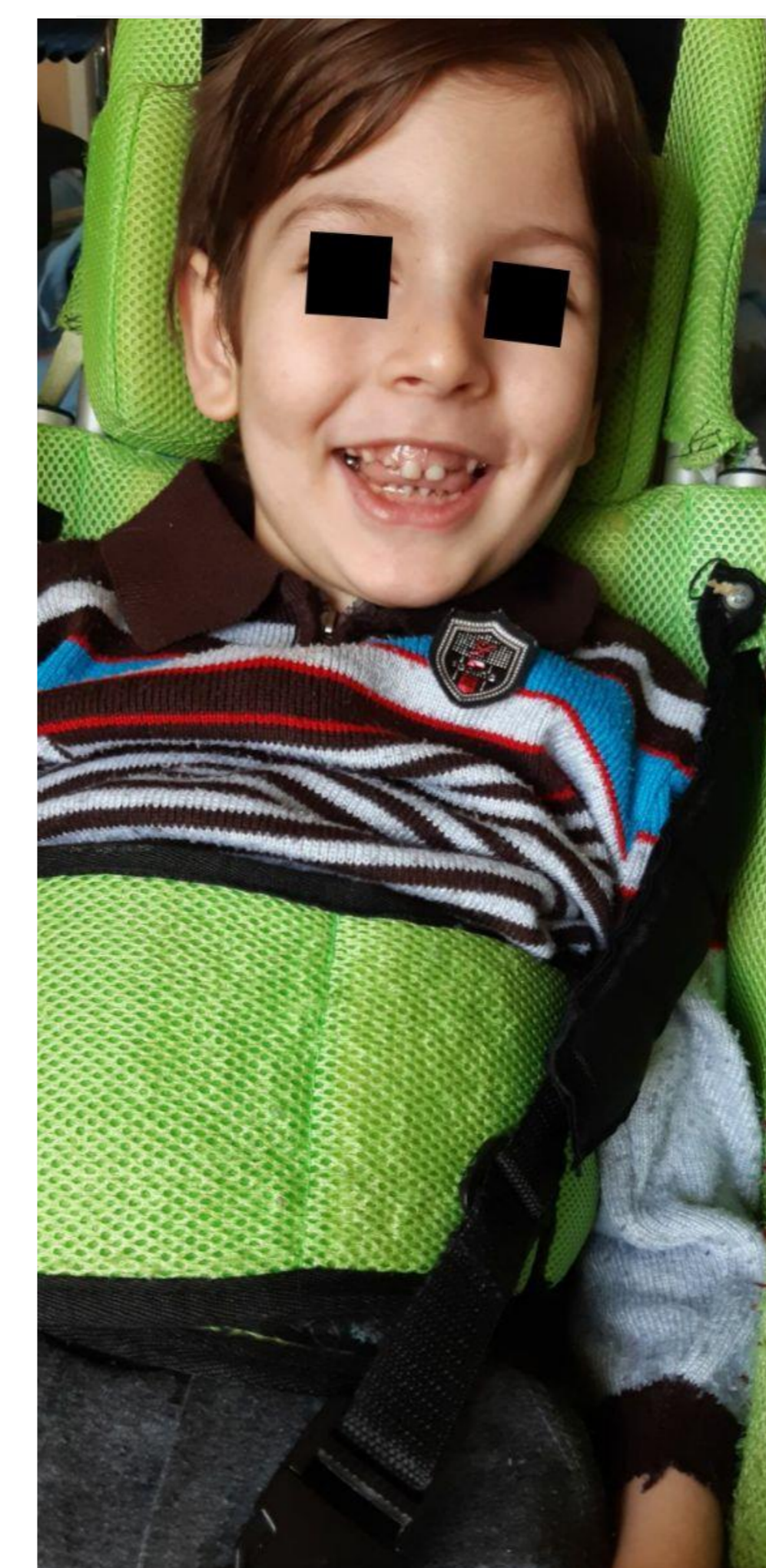


Figure 2: The patient smiles and laughs, but gives no appropriate emotional response to triggers.

Table 1: Thyroid Status of the patient

	Results	Normal Range
<b>TSH</b>	9.22 mUI/mL	0.5-4.5 mUI/mL
<b>FT4</b>	8.83 pmol/L	12.3-22.2 pmol/L
<b>T3</b>	6.04 nmol/L	1.42-3.8 nmol/L

Table 2: Results of heart rhythm's 24-Hour Holter-Monitoring

	Average (bpm)	Maximal (bpm)	Minimal (bpm)
<b>Day</b>	115-127	140-142	54-58
<b>Night</b>	106-118	124-126	52-53
<b>On exertion</b>	<b>192-197</b>		

## CONCLUSIONS

Overall, a patient has a subclinical hypothyroidism, in fact, with thyrotoxicosis. The treatment with levothyroxine is ineffective and can cause cardio-vascular complications.

Early diagnosis of AHDS by evaluating the whole thyroid profile and genetic testing gives an opportunity to avoid useless treatment and frequent hormonal tests in patients with neuro-developmental delays. With the Triac a new insight is suspected to have in a nearest future.

## REFERENCES

1. Friesema, E., Jansen, J., Heuer, H. *et al.* Mechanisms of Disease: psychomotor retardation and high T<sub>3</sub> levels caused by mutations in monocarboxylate transporter 8. *Nat Rev Endocrinol* 2, 512–523 (2006). <https://doi.org/10.1038/ncpendmet0262>
2. Triac in the treatment of Allan–Herndon–Dudley syndrome, Andrew J Bauer, *Lancet Diabetes Endocrinol* 2019 Published Online July 31, 2019 [http://dx.doi.org/10.1016/S2213-8587\(19\)30217-7](http://dx.doi.org/10.1016/S2213-8587(19)30217-7)
3. Bauer AJ. Triac in the treatment of Allan-Herndon-Dudley syndrome. *Lancet Diabetes Endocrinol.* 2019 Sep;7(9):661-663. doi: 10.1016/S2213-8587(19)30217-7. Epub 2019 Jul 31. PMID: 31377264.)

## ACKNOWLEDGEMENTS

Authors have no conflict of interest to declare

## CONTACT INFORMATION

L. Navasardyan, MD, PhD, Associate Professor,  
Yerevan State Medical University, 2 Koryun st,  
Yerevan 0025, Armenia, Tel: +37494942544  
Email: lusinevnavasardyan@gmail.com