A perioperative change of Anti-Mullerian Hormone (AMH) and E2 in a patient with SCTAT

Aya Shimada, Masaki Takagi, Kentaro Miyai, Ryuji Fukuzawa, Yukihiro Hasegawa

Tokyo Metopotian Children's Medical Center 1) Department of Endocriology and Metabolism 2) Department of

【Background】

Sex Cord Tumor with Annular Tubules (SCTAT)
- is a rare ovarian benign tumor (5% of ovarian tumor)
- is an estrogen producing tumor
- can cause precocious puberty
- has a high rate of recurrence

One third of patients with SCTAT also have Peutz-Jeghers syndrome (PJS).

As possible tumor markers of SCTAT,
- AMH,inhibinB,Estradiol(E2) were reported
- However, there is no report in pediatric field.

【Objective】

To show perioperative changes of AMH and E2 in children

【Methods】

We examine AMH and E2 at perioperative period.
(before operation, after 24hr/72hr/1month from operation)

【Case】A 6 years-old girl

【HPI】

6y Breast Swelling

6y3m Genital Breeding

【Physical Exams】

Ht 122 cm(+1.7SD), BW 21.8 kg(+0.4SD)

General Appearance: good

Abdomen: Soft&flat, no palpable mass

Skin: no café au lait spots

Tanner: Br3, PH2, AH(-)

No clinical signs of PJS.

【Bone Age】7y10m

【Laboratory Data】

Fig.1 Growth chart

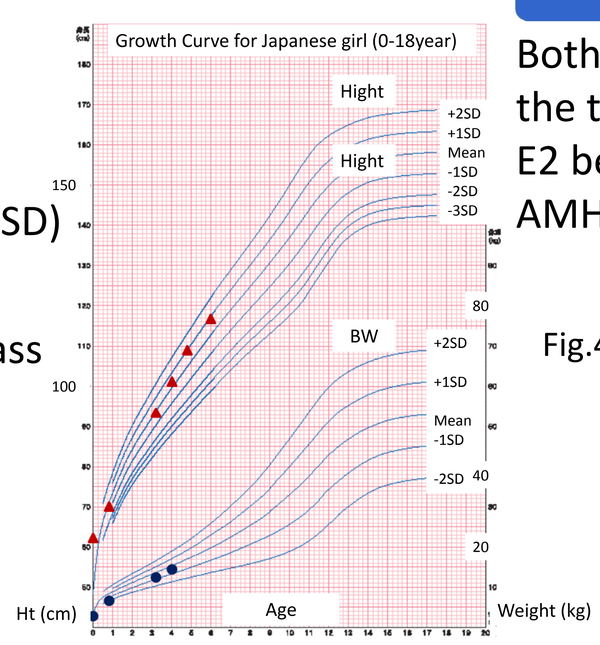

Table.1-1 Hormonal Data

LH	≦0.10	μIU/mL
FSH	≦0.05	μIU/mL
E2	153	pg/mL
T	≦0.03	ng/mL
DHEA-S	13	μg/dL
AMH	75.7	ng/mL

Table.1-2 Tumor markers

		Reference	
HCG-β	≦0.10	(0.00-0.1)	μIU/mL
CA19-9	≦0.05	(0.0-37.0)	μIU/mL
CA125	153	(0.0-35.0)	pg/mL
AFP	≦0.03	(<10.0)	ng/mL

【Ultrasonography (Fig.2)】

-multiple cystic mass(White arrow)

-sized in 5.3 cm × 6.2 cm × 4 cm

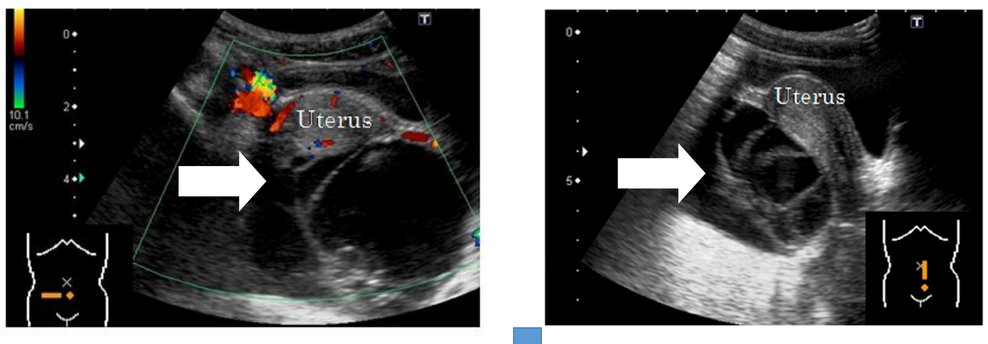

Diagnosis:

#1 Left ovarian tumor（Granulosa Cell Tumor suspected)

#2 GnRH independent precocious puberty

Treatment:

Left oophorectomy

【 Pathological findings 】

<Macro (Fig.3-1)>

Size:7.3 cm × 5 cm × 2.4 cm Weight：69.7 cm

-composed of cystic and solid component

-cystic component was filled with yellow fluid

<Microscopic findings (Fig.3-2)>

-multiple hyaline bodies which is surrounded by columnar cells

-tumor cells have eosinophilic cytoplasma and round nuclei

-shows minimal atypia

Fig.3-1

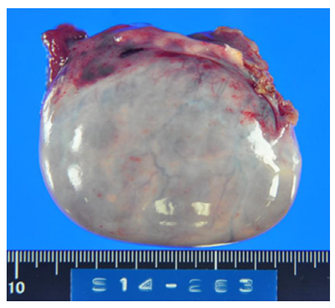

Fig.3-2 ENLARGE

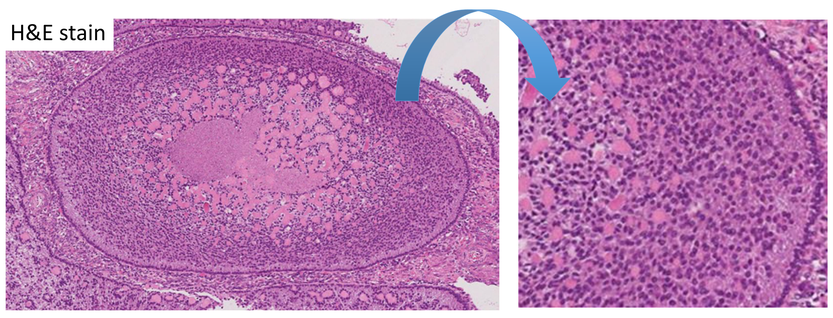

【Results】

Both AMH and E2 were extremely high in fluid component of the tumor.

E2 became rapidly undetectable after resection of the tumor.

AMH turned into normal within a month after resection.

Fig.4 Perioperative change of E2 and AMH

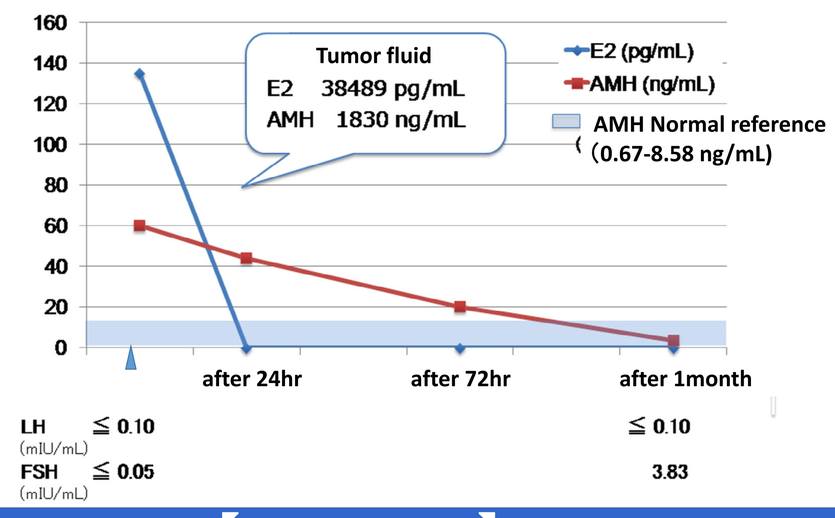

【Discussion】

SCTAT is a estrogen producing ovarian tumor. The first line therapy for SCTAT is a surgical resection of the tumor.

However, a special caution for recurrence is necessary after resection of the tumor because of its high recurrence rate.

Gustafson et al[1] reported that there was a strong co-relation between tumor volume and serum AMH at a patient with SCTAT. AMH and E2 may be used as useful tumor markers in a pediatric patient with SCTAT as it had been reported with adult patient. AMH can be a more useful marker in pediatric patients since AMH level remains relatively stable regardless of pubertal stage.

【Conclusion】

AMH can be a more useful marker in pediatric patients with SCTAT.

【Reference】

1) Gustafson ML, Le MM and Scully RE et al, N Engl J Med. 1992; 13:326:466-71

2) Hiroshi Ishikawa et al, Am J Obstet Gynecol. 2012; e14-e16

3) Hagen CP et al, J Clin Endocrinol Metab.2010; 95:5003-5010

【COI】

no conflicts to disclose

ESPE 2015 432-P2

Endocrine Oncology

Aya Shimada

DOI: 10.3252/pso.eu.54espe.2015

Poster presented at: ESPE 2015 BARCELONA

PosterSessionOnline.com