

Congenital hyperinsulinism in siblings - case report

Brandt Agnieszka, Buraczewska Marta, Myśliwiec Małgorzata

Clinic of Pediatrics, Diabetology and Endocrinology

Medical University of Gdansk, Poland

BACKGROUND

- Congenital hyperinsulinism (CHI) is the most common cause of hypoglycemia in childhood, and diagnosis and treatment of CHI is one of the most difficult aspects of endocrinology and diabetology
- In half of infants suffering from CHI, which may require resection of pancreas, potentially curable focal form can be found
- Recently introduced diagnostic imaging using 18 F-DOPA-PET allows for differentiation as a diffuse and focal form and determines further treatment
- Identification of the exact location of lesions is used in preoperative planning, which involves resection limited to the focus and as a result it leads to a reduction in postoperative complications

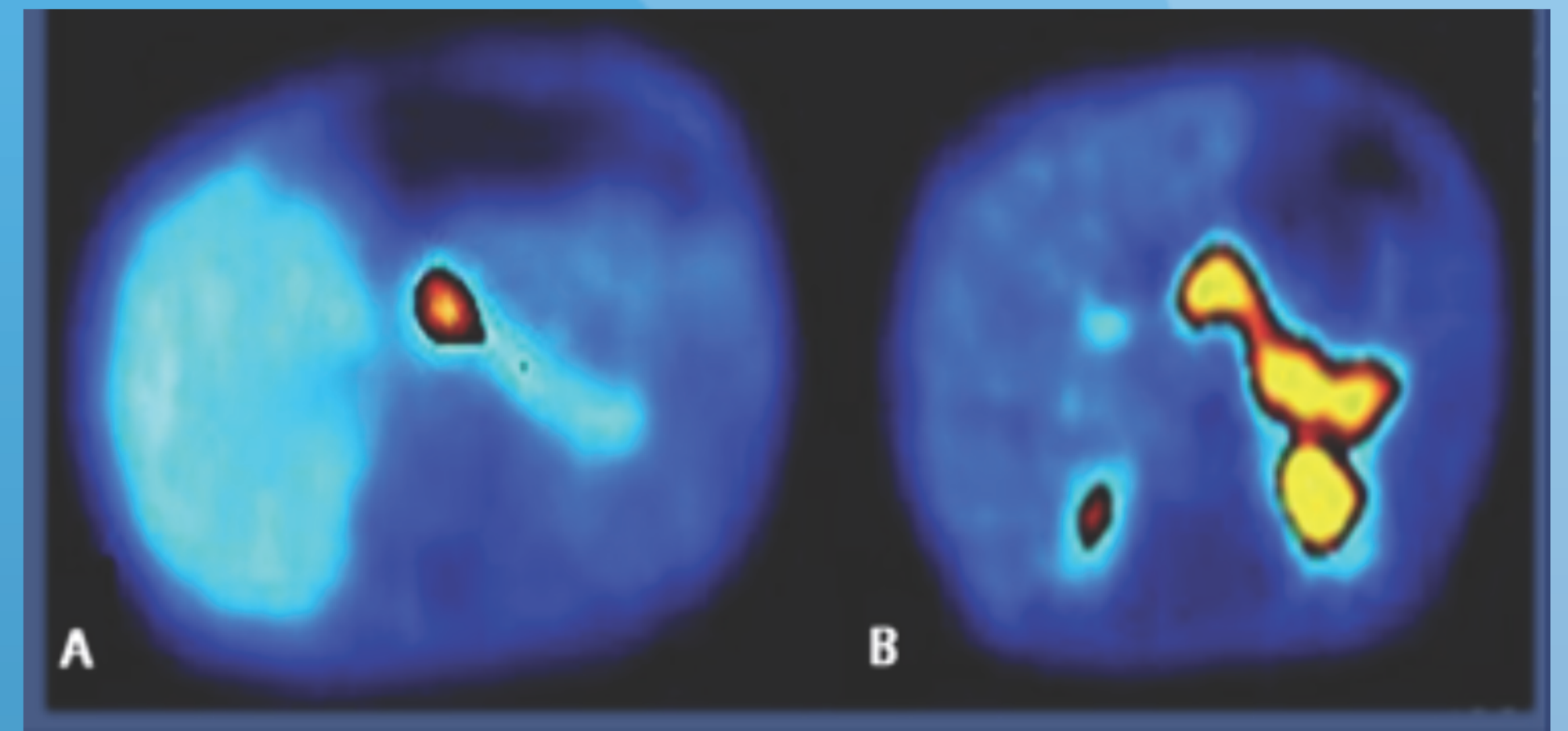


Image congenital hyperinsulinism during the test 18-F-DOPA-PET (Amoux et al. Congenital hyperinsulinism current trends in diagnosis and therapy. Orphanet Journals of Rare Diseases 2011.)

Conventional CT and MRI are not able to detect lesions in the pancreas. Imaging using PET with marker 18 F-DOPA has revolutionized the diagnosis of congenital hyperinsulinism.

CASE REPORT

- two sisters, who were diagnosed with congenital focal form of hyperinsulinism and the impact of performed diagnostic test for the treatment and the occurrence of postoperative complications
- CHI in older sister was diagnosed when diagnostic imaging with 18 F-DOPA-PET was not yet available, which led to subtotal pancreatectomy and ultimately resulted in diabetes and pancreatic enzyme deficiency symptoms after operation. In the postoperative examination of the removed tissue a single focus of hyperinsulinism was found
- In younger sister during diagnosis it was possible to perform the study with 18-F-DOPA-PET, and there was identified an isolated focus of hyperinsulinism, which was resected during operation and none postoperative complications were observed and complete resolution of the symptoms of hypoglycemia
- In both sisters genetic tests were performed for searching the reason of familial form of CHI

	Sister 1	Sister 2
diazoxide	no effect	no effect
octreotide	no effect	no effect
PET	not done	done
operation	subtotal pancreatectomy	CHI focus resection
Histology of CHI	focal	focal
diabetes	yes	no
pancreatic enzymes deficiency	yes	no

CONCLUSION

It is important to perform diagnostic imaging with 18 F-DOPA-PET in children with CHI before planning pancreatectomy to avoid complications

E-mail: abrandt@gumed.edu.pl