

# Patients with Turner's syndrome should have ophthalmological examination before commencing recombinant growth hormone treatment

Hussain Alsaffar, Ellinor Thomason, Mohammed Didi, Joanne Blair

Department of Paediatric Endocrinology – Alder hey Children's Hospital - Liverpool - UK

## Introduction

Turner's syndrome (TS) is caused by an abnormality of one of the X chromosomes. Short stature or slow growth is one of the first manifestations of TS and it is recommended that growth hormone (GH) therapy should be initiated as soon as it becomes apparent that affected girls are not growing normally to optimise final adult height. Idiopathic intracranial hypertension (IIH) is a well-known side effect of GH therapy, and it has also been reported in girls with TS with or without GH therapy.

## Case Report

A patient with TS, aged 3.55 years, height 83cm (-4.04SDS), started treatment with GH (Norditropin SimpleXx) 0.5mg subcutaneously (43micrograms/kg/day).

Within two weeks of the start of treatment she presented to the Emergency Department with headache and vomiting. Ophthalmological review revealed that she had bilateral papilloedema.

A lumbar puncture (LP) was performed under general anaesthesia. The opening pressure was 24.5 cm H<sub>2</sub>O. GH was stopped, however, she continued to have intermittent headaches but with no vomiting. Neurological examination remained normal.

After three months she presented with worsening headache and vomiting. At this time the opening pressure on LP was 33cmH<sub>2</sub>O. She started treatment with acetazolamide with good effect. One week later opening pressure on LP was 24cmH<sub>2</sub>O.

## Conclusion



We concluded this patient may have had pre-existing, asymptomatic IIH that became symptomatic when she started GH therapy as IIH worsening despite stopping treatment. Therefore, we recommend that all patients with TS should have detailed ophthalmological examination to exclude papilloedema before starting GH therapy.

## References

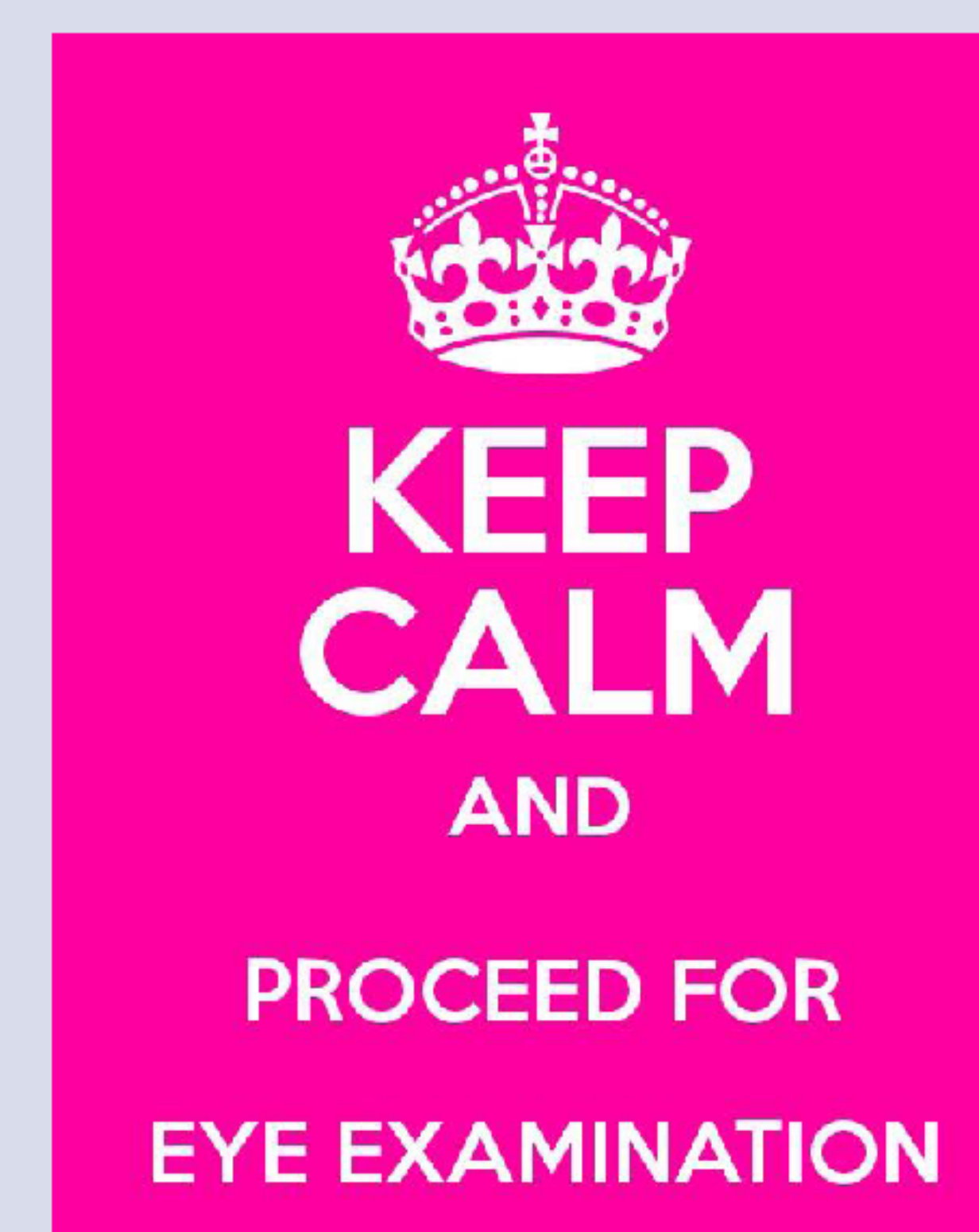- 1- Noto R et al, Intracranial hypertension in pediatric patients treated with recombinant human growth hormone: data from 25 years of the Genentech National Cooperative Growth Study, Journal of Pediatric Endocrinology and Metabolism. 2011;24(9-10):627-31.
- 2- Bala et al, Turner's syndrome and benign intracranial hypertension with or without growth hormone treatment. Journal of Pediatric Endocrinology and Metabolism. 2004 Sep;17(9):1243-4.



Short girl with Turner's syndrome who will be started on growth hormone treatment



**Has she had ophthalmology assessment?**



Poster number P3-1240  
Turner, Alsaffar

