

Vitamin D dependent rickets type 1A with genetic analysis in 3 Chinese children

Wenjing LI, Chunxiu GONG, Diwu

Department of Endocrinology, Genetics and Metabolism, Beijing Children's Hospital, Capital Medical University, Beijing 100045, P.R. China



Background:

Vitamin D dependent rickets type 1A (VDDR1A) is a rare disease caused by CYP27B1 mutations which encodes vitamin D 1 α -hydroxylase.

Objective and hypotheses:

Vitamin D dependent rickets type 1A features of 3 Chinese cases with CYP27B1 mutations and report the experience of medication for severe hypocalcemia.

Method: Summarize their clinical features analyze the CYP27B1 and vitamin D receptor (VDDR) mutations.

Results:

one 1.2 yr boy and two girls of 2 and 2.7 years old on their admissions.

Typical signs of rickets.

Two of them had pathological fractures and predominant lower limbs deformities.

Delayed walking.

They had hypocalcemia (1.17-1.59mmol/L), high alkaline phosphatase level (904.6-2240U/L) accompanied with elevated PTH level (492.3-1238.4pg/ml). Serum 25-(OH) D3 levels were normal to high 27-105.2ng/ml and 1, 25 -(OH)2D3 levels were low (3.21-10.02pg/ml)

In genetic analysis, they were all shown to have compound heterozygous mutations of CYP27B1 gene (see table 1).

Table 1. The CYP27B1 gene mutations in the three patients

Case	mutation	Changed structure	Protein
1	485T>A/1086T>A	Missense/synonymous	162 V>D/362 T>T
2	1325CCCACCC,ins/ 1375,C>G	frame shift/missense	Truncated /459R>G
3	1325 CCCACCC,ins/1442 A del	Truncated/frame shift	Truncated/protein changed

All patients were treated with calcium and calcitriol. Two of the female patient can stand up steadily 3 months after treatment and walk steadily 6 months later. A female patient suffered from "bone hungry syndrome", who was taken calcium intravenous infusion continuously for 3 days. The male patients died of severe pneumonia 1 month after discharged.

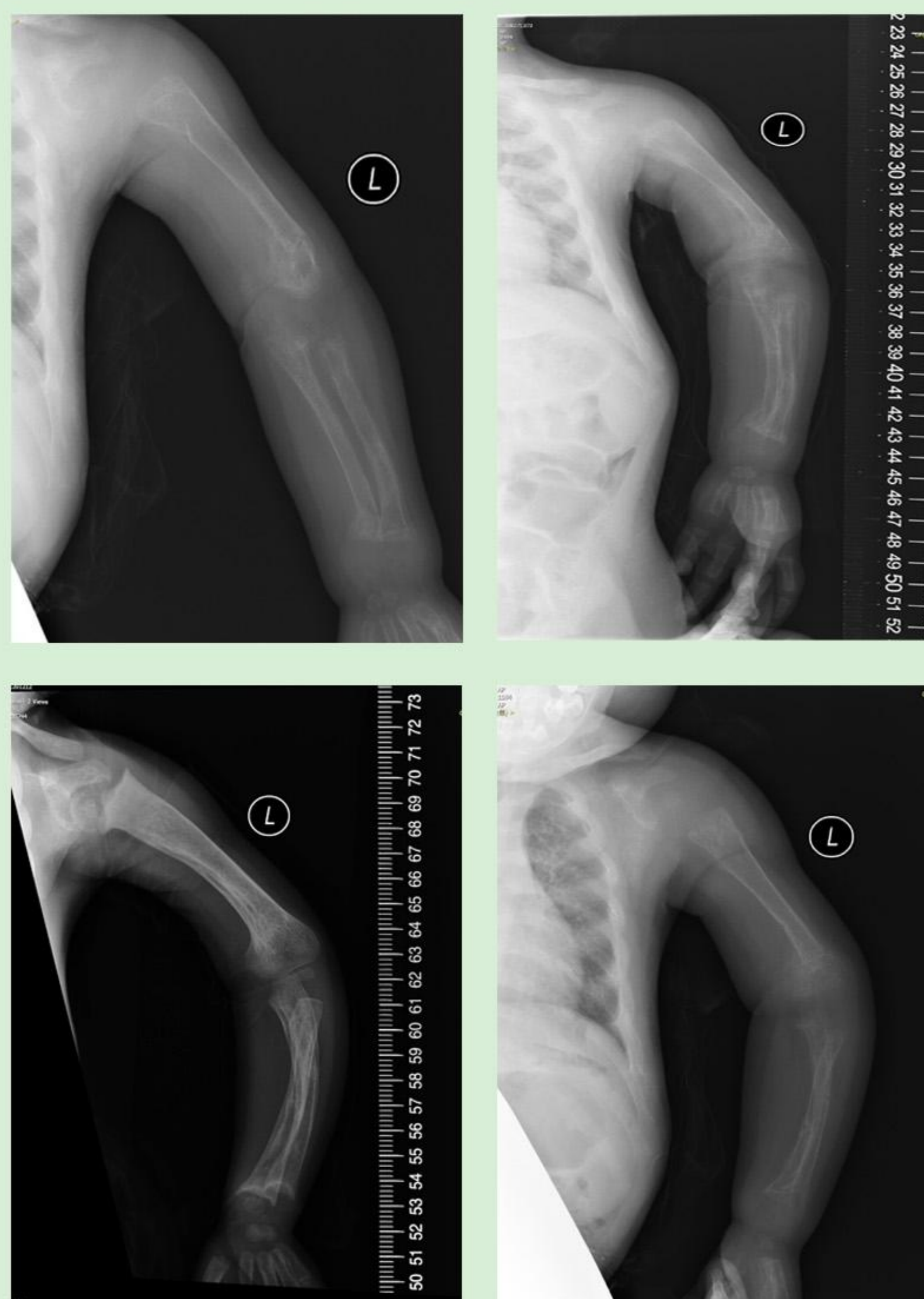
Conclusion:

Patients with VDRR 1A have a wide spectrum of clinical manifestations varying from mild to severe, even pathogenic fractures.

They can be cured by high dose calcitriol and calcium supplementation.

Intravenous injection may be needed because of severe bone hungry.

The mutation of c.1325 CCCACCC seems to be a hot spot of CYP27B1 in VDRR1A, which has been reported in several of families.



北京
儿
童
医
院

